EUROPEAN SOCIETY OF RADIOLOGY

eBook for Undergraduate Education in Radiology

CHAPTER: Pancreas and Spleen Imaging

Preface

Undergraduate teaching of radiology in Europe is provided according to national schemes and may vary considerably from one academic institution to another. Sometimes, the field of radiology is considered as a "cross-cutting discipline" or taught within the context of other clinical disciplines, e.g., internal medicine or surgery.

This e-book has been created in order to serve medical students and academic teachers throughout Europe to understand and teach radiology as a whole coherent discipline, respectively. Its contents are based on the *Undergraduate Level of the ESR European Training Curriculum for Radiology* and summarize the so-called ***core elements*** that may be considered as the basics that every medical student should be familiar with. Although specific radiologic diagnostic skills for image interpretation cannot be acquired by all students and rather belong to the learning objectives of the *Postgraduate Levels of the ESR Training Curricula*, the present e-book also contains some ***further insights*** related to modern imaging in the form of examples of key pathologies, as seen by the different imaging modalities. These are intended to give the interested undergraduate student an understanding of modern radiology, reflecting its multidisciplinary character as an organ-based specialty.

We would like to extend our special thanks to the authors and members of the ESR Education Committee who have contributed to this eBook, to Carlo Catalano, Andrea Laghi and András Palkó who initiated this project, and to the ESR Office, in particular Bettina Leimberger and Danijel Lepir, for all their support in realising this project.

We hope that this e-book may fulfil its purpose as a useful tool for undergraduate academic radiology teaching.

Minerva Becker

Chapter Outline

Copyright and Terms of Use

How to cite this work:

European Society of Radiology, Christoph D Becker (2023) eBook for Undergraduate Education in Radiology: Pancreas and Spleen Imaging. DOI 10.26044/esr-undergraduate-ebook-21

Chapter Outline

Hyperlinks

Core Knowledge

Further Knowledge

Attention

Compare

Questions

References

Chapter Outline

eBook for Undergraduate Education in Radiology

Based on the ESR Curriculum for Undergraduate Radiological Education

Chapter: **Pancreas and Spleen Imaging**

Author

Christoph D. Becker

Affiliation

Faculty of Medicine, University of Geneva, Switzerland

Christoph.Becker@unige.ch

Chapter Outline

Chapter Outline

Chapter Outline

Anatomy
Imaging Techniques
Variants
Acute Pancreatitis
Chronic Pancreatitis
Pancreatic Neoplasms
Splenic Pathologies
Blunt Trauma
Take-Home Messages
References
Test Your Knowledge

Pancreas: Anatomy Overview

The pancreas is a gland with exocrine and endocrine functions located at the level of L1/L2 mostly within the retroperitoneal space. It has four parts: the head with the uncinate process as its posterior lower portion, the neck, the body and the tail.

The pancreatic head is adjacent to the duodenal loop and contains the distal common bile duct, its junction with the common pancreatic duct and the sphincter Oddi. The pancreatic tail is situated in close vicinity to the splenic hilum and may be partially located intraperitoneally.

The pancreatic parenchyma is surrounded by the peripancreatic fatty tissue. Other characteristic adjacent anatomical landmarks that are visible on cross-sectional imaging include the splenic vein (SV) the celiac axis (CA) and the superior mesenteric artery (SMA).

The arterial supply of the pancreas is derived from branches of the CA (gastroduodenal and splenic arteries) and the SMA.

The venous drainage occurs mainly via the SV and SMV, and the portal vein.

The lymphatic drainage of the pancreas follows both intraperitoneal and retroperitoneal pathways, to the portal, celiac, superior mesenteric, para-aortic and aortocaval lymph nodes.

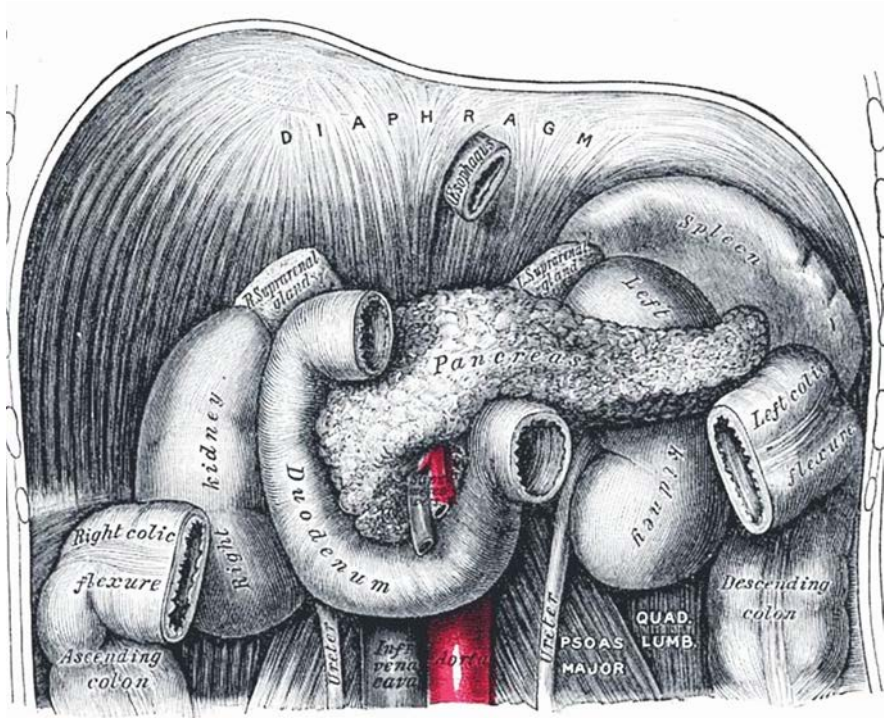

Case courtesy of Gray's Illustrations, Radiopaedia.org, rID: 36234

Chapter Outline

Pancreas: Anatomy at Cross-Sectional Imaging

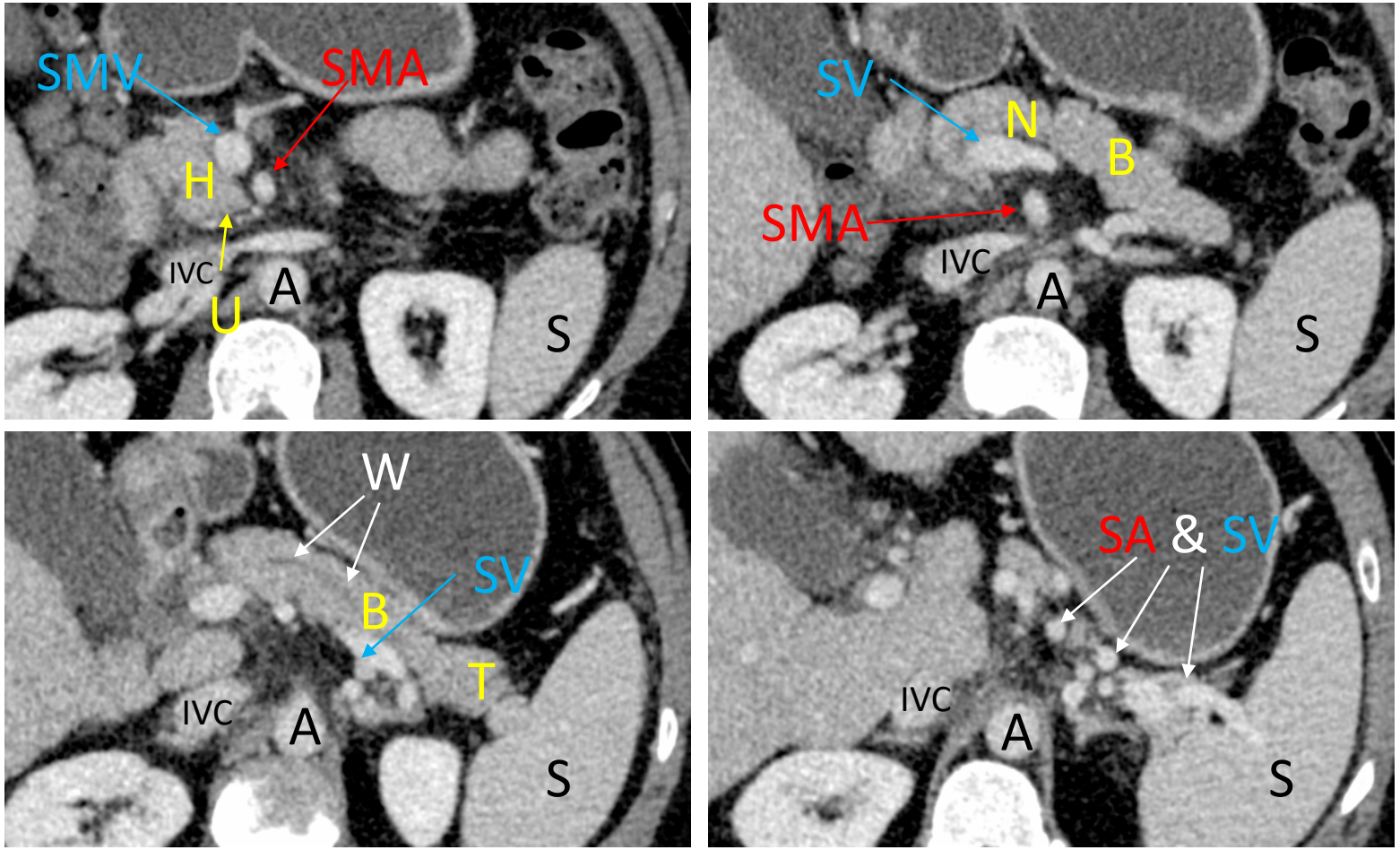

CT showing the pancreas with its adjacent structures.
A = aorta; B = body of pancreas; H = head of the pancreas; IVC = inferior vena cava; N = neck of the pancreas; S = spleen; SA = splenic artery; SMA = sup mesenteric artery; SMV = superior mesenteric vein; SV = splenic vein; T = tail of the pancreas; U = uncinate process; W = duct of Wirsung

Chapter Outline

Pancreas: Anatomy of Endocrine and Exocrine Components

Most of the pancreatic tissue (acinar cells and ductal cells) serves the exocrine function, producing pancreatic juice that is drained by the pancreatic ductal system. The pancreatic juice contains enzymes for protein, lipid and carbohydrate digestion. The exocrine pancreatic ductal system consist of minor (second order) pancreatic ducts which drain into the main pancreatic ductal system and into the duodenum.

The pancreas has also an endocrine function for the production of peptide hormones such as insulin, glucagon, or somatostatin. These hormones are produced in the islets of Langerhans (groups of about 100-200 cells), which are embedded in the exocrine pancreas and constitute about 1-2% % of the total organ mass.

Although scattered throughout the entire organ, islet cells are more concentrated in the pancreatic tail compared with the head and body.

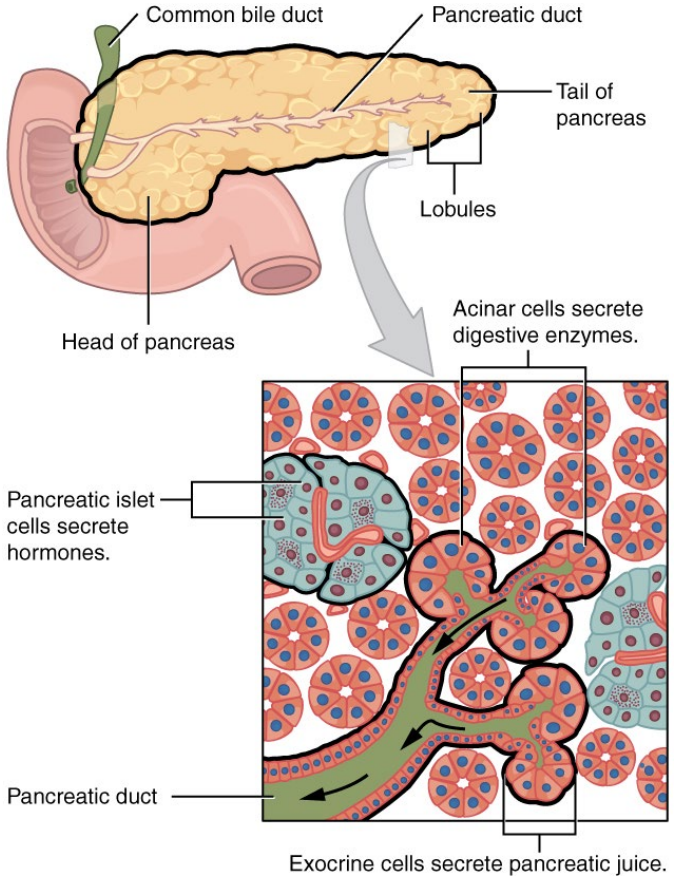

Diagram showing some of the anatomy and the microanatomy of the human pancreas. Reproduced from: https://commons.wikimedia.org/wiki/File:2424_Exocrine_and_Endocrine_Pancreas-ar.jpg

Chapter Outline

Spleen: Anatomy

The spleen is a homogeneously structured, intraperitoneal parenchymal organ in the left upper quadrant of the abdomen, adjacent to the pancreatic tail and upper pole of the left kidney.

Its arterial supply is derived from the celiac axis and its venous drainage goes via the splenic vein into the portal system.

It is the largest organ of the lymphatic system, and its function consists in immune surveillance, maturation of lymphocytes and degradation of damaged or senescent erythrocytes and platelets.

The spleen parenchyma contains the white pulp (lymphocytes around arteries) and the red pulp (venous sinuses and cords).

The spleen measures about 9 – 12cm and weighs about 150 – 200g.

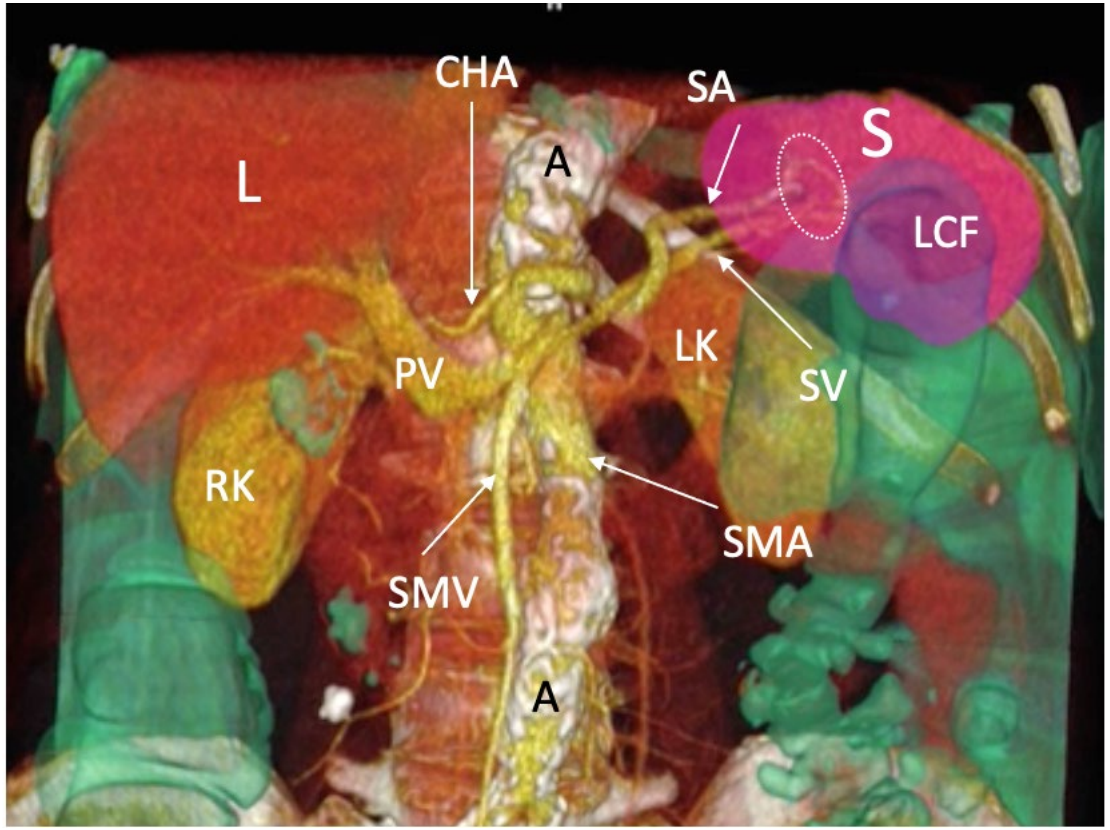

Colour-coded 3D Volume Rendering showing the position of the spleen in the upper abdomen (frontal view). A = aorta; CHA = common hepatic artery; L = liver; LCF = left colic flexure; LK = left kidney; RK = right kidney; S = spleen; SA = splenic artery; SMA = sup mesenteric artery; SMV = superior mesenteric vein; SV = splenic vein; Air in the large and small bowel is rendered in green. Spleen hilum within the dotted ellipse.

Chapter Outline

Imaging Techniques for the Pancreas: Computed Tomography (CT)

Multiphasic contrast-enhanced CT can be considered as the method of choice for imaging the pancreatic parenchyma for the most common indications including acute and chronic pancreatitis and their complications, for pancreatic trauma, and exocrine and endocrine neoplasms. It is a robust, rapid and reproducible imaging technique that offers a complete and rapid overview of the entire abdominal region.

The different dynamic phases after iv. injection of iodinated contrast material include the arterial, pancreatic (= late arterial) and portal phases, resulting in optimal depiction of the arterial and portal vessels, as well as of the pancreatic parenchyma. The late arterial (pancreatic) and the portal phase are mandatory, whereas the arterial phase in mainly indicated for angiographic studies.

Multiplanar oblique reconstructions demonstrate specific anatomical details, e.g., ductal or vascular structures.

Besides diagnostic imaging, CT can also be used for guiding minimally invasive, percutaneous biopsy, as well as aspiration and drainage of infected and non-infected pancreatic fluid collections.

Chapter Outline

Imaging Techniques for the Pancreas: Computed Tomography (CT)

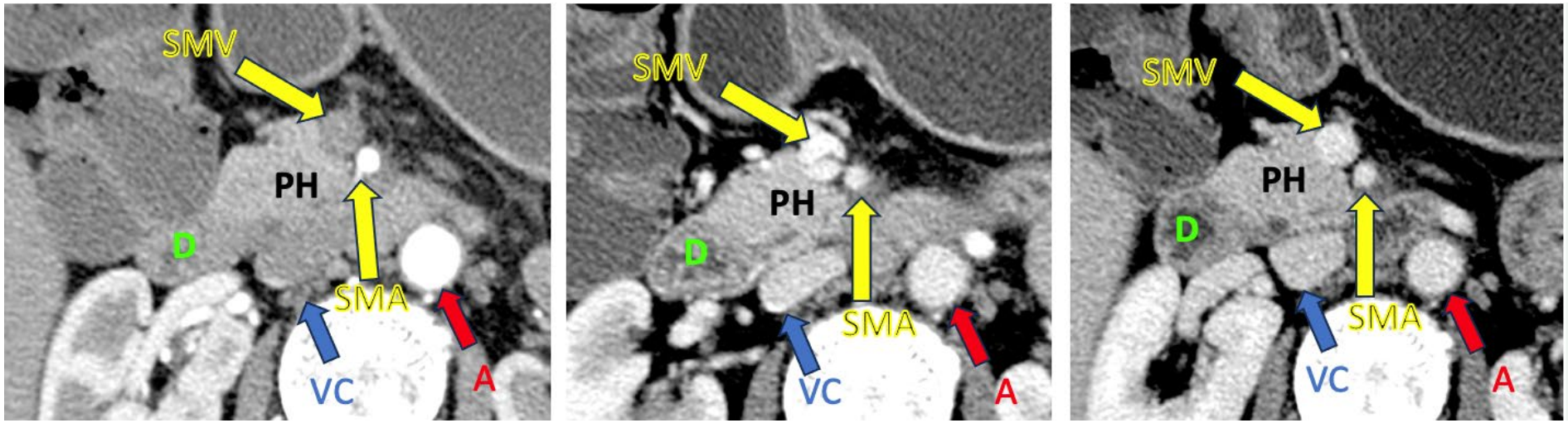

Arterial phase | Pancreatic phase | Portal phase

Multiphasic contrast-enhanced CT of the pancreas. Images obtained at the level of the pancreatic head (PH). A = Aorta; VC = Vena cava; SMA= Superior mesenteric artery; SMV= superior mesenteric vein; D= Duodenum

Images courtesy: Oskar Bożek, MD, Department of Radiodiagnostics and Invasive Radiology, Faculty of Medical Sciences in Katowice, Medical University of Silesia.

Chapter Outline

Imaging Techniques for the Pancreas: Computed Tomography (CT)

The head of the pancreas is in a slightly more inferior location in the abdomen in comparison to the pancreas body and tail. Therefore, the head is seen on more caudal axial CT slices, whereas the tail, which extends into the splenic hilum is seen on more cranial images.

The pancreas typically has a lobulated appearance.

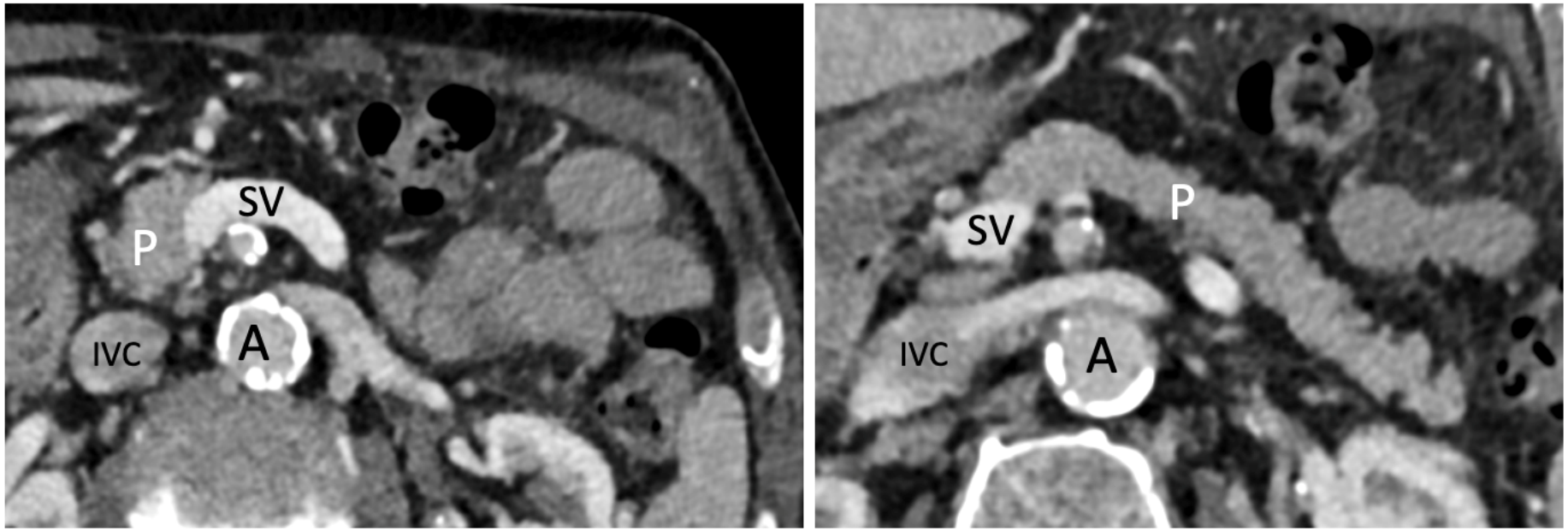

Axial CT slices (portal phase) obtained at the level of the pancreas head (left image) and pancreas body and tail (right image). Normal lobulated appearance of pancreatic tissue (P); A = aorta; IVC = inferior vena cava; SV = splenic vein

Chapter Outline

Imaging Techniques for the Pancreas: Computed Tomography (CT)

The main pancreatic duct runs through the gland from left to right and drains most of the pancreas apart from the inferior portion of the head and uncinate process. Its diameter is larger in the pancreatic head (~3.5mm) and slightly narrower in the body (~2.5mm) and tail (~1.5mm).

Variants exist with regard to the ductal anatomy in the pancreatic head.

In the most common situation, the duct of Wirsung joins the distal common bile duct to form the ampulla of Vater.

The accessory pancreatic duct of Santorini typically communicates with the duct of Wirsung. It drains separately into the duodenum via a minor papilla.

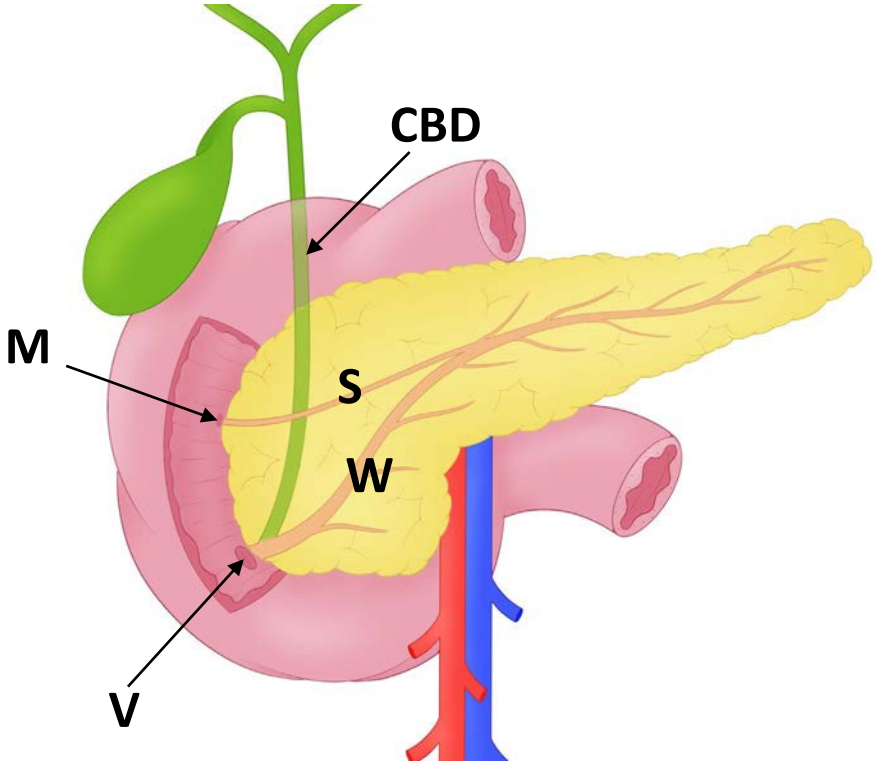

Schematic illustration of the normal anatomical relationship between the main pancreatic duct of Wirsung (W) and the accessory pancreatic duct of Santorini, (S), the common bile duct and the duodenum. V = ampulla of Vater; M = minor papilla.

Illustration by Emma Tabone, Mater Dei Hospital, University of Malta, Malta

Chapter Outline

Imaging Techniques for the Pancreas: Computed Tomography (CT)

CT allows visualisation of the main pancreatic duct and its contour. It also allows to measure ductal calibre and assess ductal dilatation. However, CT has an inferior diagnostic performance compared to MRI for precisely assessing ductal changes (see MRI part).

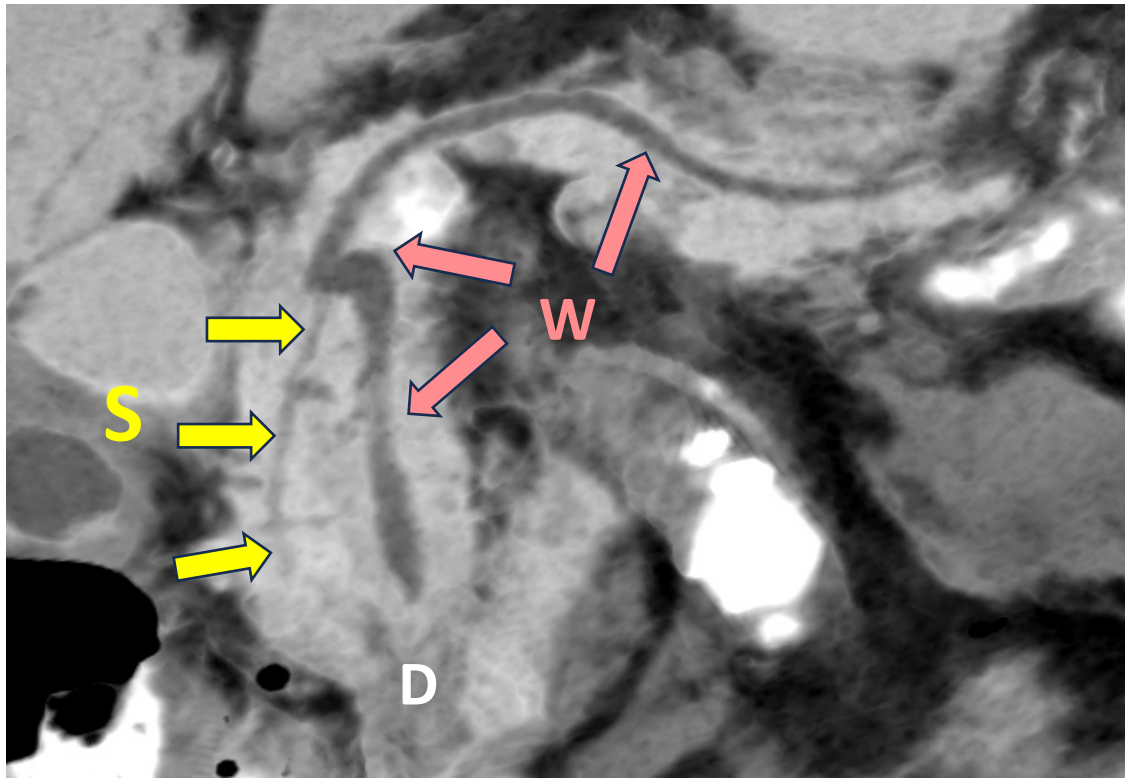

Pancreatic phase CT, oblique reconstruction, minimal intensity projection, demonstrating the pancreatic ductal anatomy. Note that in this (common) variant the duct of Wirsung is larger in calibre than the duct of Santorini. W = Duct of Wirsung; S = Duct of Santorini; D = Duodenum.

Image courtesy: Oskar Bożek, MD, Department of Radiodiagnostics and Invasive Radiology, Faculty of Medical Sciences in Katowice, Medical University of Silesia

Chapter Outline

Imaging Techniques for the Pancreas: Computed Tomography (CT)

Advantages of CT :

- Robust, reproducible, fast, high spatial resolution
- Dynamic imaging in different vascular phases in order to detect perfusion anomalies, haemorrhage and thrombosis
- Excellent contrast resolution for detection of pancreatic calcifications and inflammatory fluid collections
- Includes complete abdominal region, allowing delineation of peri- and extra-pancreatic changes which are common in inflammatory and neoplastic conditions
- Can be used for guidance of minimally invasive percutaneous biopsy and drainage

Disadvantages of CT :

- Radiation exposure
- Requires injection of iodinated iv. contrast material
- Limited delineation of ductal changes

Chapter Outline

Imaging Techniques for the Pancreas: Ultrasound (US)

Ultrasound (US) has a key role in patients with suspected acute pancreatitis, because it is the method of choice for the detection of cholecystolithiasis, a common cause of acute pancreatitis, as well as bile duct obstruction.

A careful US examination may also reveal a variety of pathologic changes in the context of inflammatory and neoplastic pancreatic disease. However, visualisation of the pancreatic region with transcutaneous US is often incomplete because obesity and interposition of bowel gas may partially obscure the pancreas, especially the distal portions.

In the case of an adequate sonographic window, Doppler US can be helpful to delineate the presence or absence of blood flow in the major peripancreatic vessels and detect vascular abnormalities such as arterial pseudoaneurysms. Analysis of parenchymal perfusion may be enhanced by the iv. injection of US-specific contrast material.

=> See e-book chapter on contrast media!

In addition, US can be used for guiding percutaneous biopsy and drainage procedures.

Chapter Outline

Imaging Techniques for the Pancreas: Ultrasound (US)

Advantages of US :

- Wide availability, low cost
- No radiation exposure, no iodinated or Gd-based contrast materials
- May be used as first-line examination in children
- Method of choice for cholecystolithiasis and bile duct obstruction
- Careful examination may delineate a variety of pancreatic pathologies (parenchymal masses, fluid collections, thrombosis…)
- Doppler ultrasound delineates the presence or absence of blood flow in major vessels as well as perfusion abnormalities of parenchyma and may be enhanced by iv. injection of US-specific contrast material.

Disadvantages of US :

- Operator- and patient- dependent
- Inconsistent visibility of pancreatic region, especially distal (left) portion of pancreas
- Limited accuracy for parenchymal changes

Chapter Outline

Imaging Techniques for the Pancreas: Ultrasound (US)

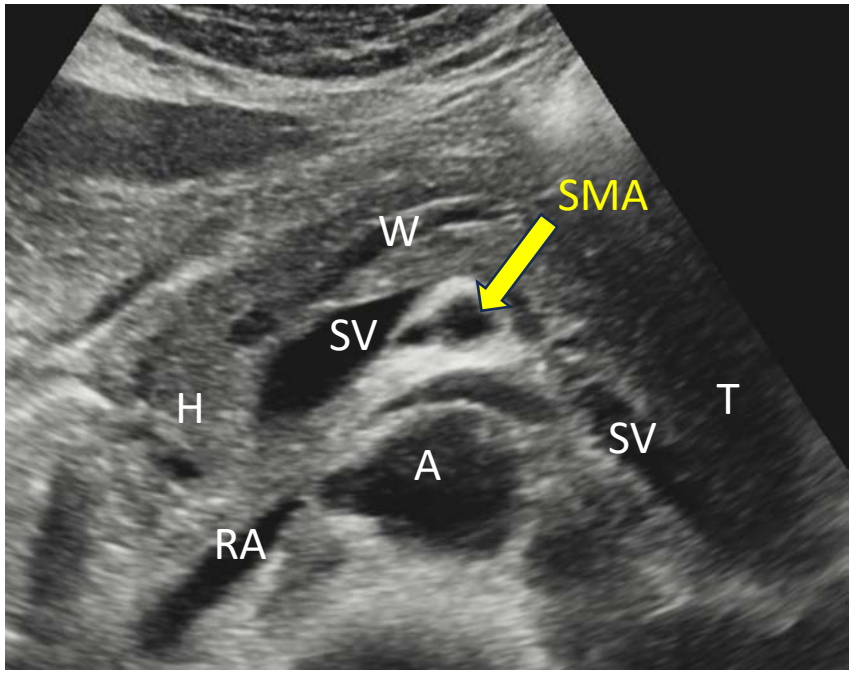

US (grey scale) showing the echogenicity of normal pancreatic tissue. H = head; T = tail; W = main pancreatic duct of Wirsung; A = aorta; SV= splenic vein. RA = right renal artery.

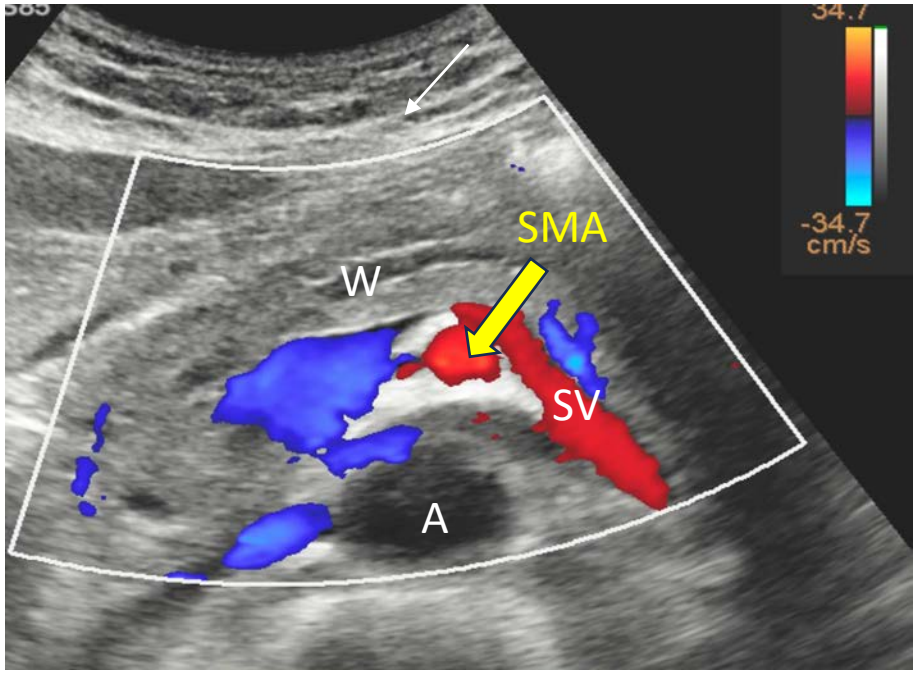

Doppler US showing the vascular flow. SMA = superior mesenteric artery; SV = splenic vein; A = aorta. Note that the direction of the blood flow towards the US probe is encoded in red (positive velocity values), whereas the direction of the blood flow away from the US probe is encoded in blue (negative velocity values). In the SV, the blood, therefore, flows from the right side of the image (tail area) to the left side of the image (head area), which is normal. Likewise, blood flow in the right renal artery is from the aorta away (normal).

Images courtesy: Gyorgi Varnay, MD, University Hospitals Geneva, University of Geneva, Switzerland

Chapter Outline

Imaging Techniques for the Pancreas: MRI

Magnetic Resonance Imaging (MRI) provides equivalent information compared with CT regarding most parenchymal abnormalities. MRI also offers multiphasic perfusion imaging with Gadolinium-based iv. contrast material and offers interrogation of the pancreatic tissue with different T1 and T2 weighted sequences. Diffusion imaging (DWI) may add useful information for the distinction between inflammatory and neoplastic masses.

Although intraparenchymal calcifications are less well depicted than with CT, MRI is the non-invasive method of choice for the depiction of the pancreatic ducts and allows examination of the biliary tree at the same time. Magnetic resonance cholangio-pancreatography (MRCP) is based on the natural high signal of biliary and pancreatic fluid (stationary fluids) on heavily T2 weighted sequences and does, therefore, not require any contrast material.

Dynamic repetitive MRCP after injection of secretin (hormone regulating water homeostasis throughout the body) allows evaluation of the exocrine pancreatic function because secretin stimulates the secretion of pancreatic juice.

Although MRI can replace CT for the diagnosis of pancreatic disease in most diagnostic settings, image acquisition takes more time as compared with CT. It also requires patient cooperation and has drawbacks in patients who are equipped with electronic devices, monitoring devices, some pacemaker types, or other electronic implants.

Chapter Outline

Imaging Techniques for the Pancreas: MRI

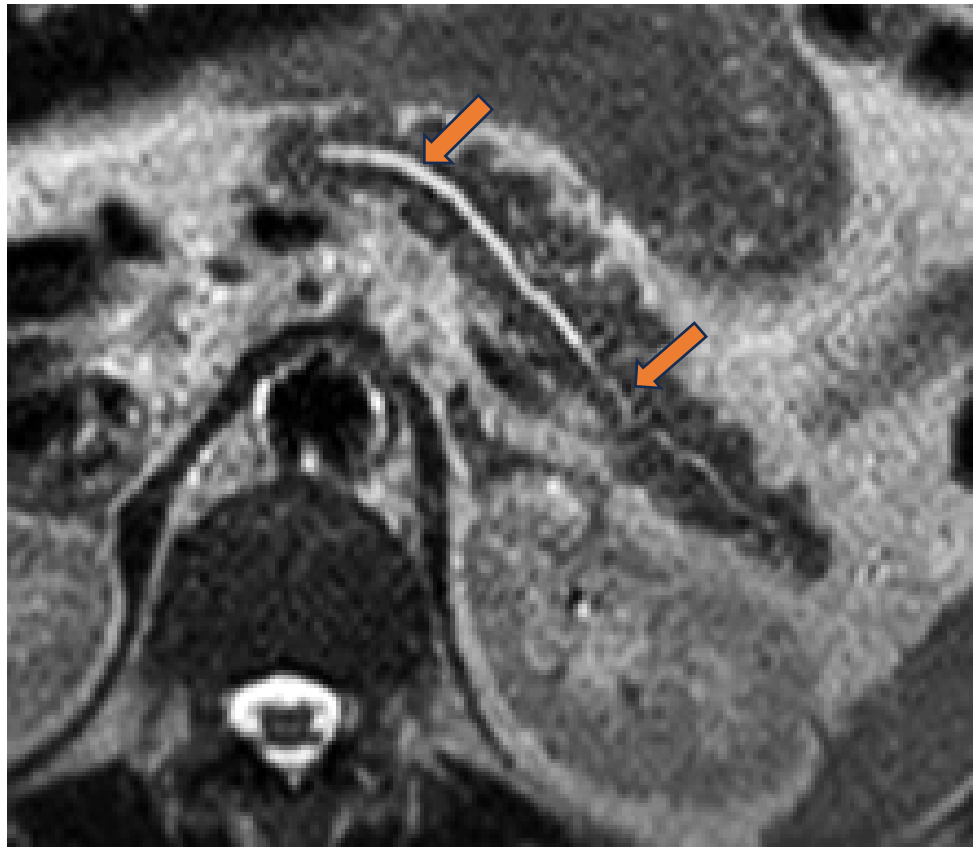

MRI (transverse T2-weighted image) showing the normal lobulated appearance of the pancreatic body and tail and a normal main pancreatic duct (arrows)

Chapter Outline

Imaging Techniques for the Pancreas: MRI

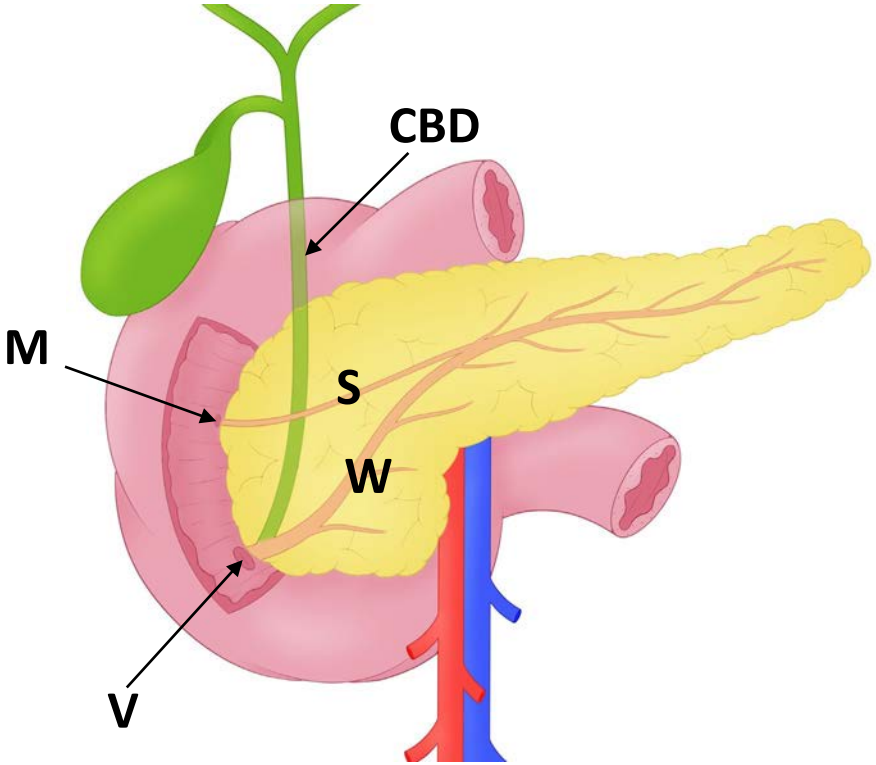

Schematic illustration of the normal anatomical relationship between the main pancreatic duct of Wirsung (W) and the accessory pancreatic duct of Santorini, (S), the common bile duct and the duodenum. V = ampulla of Vater; M = minor papilla.

Illustration by Emma Tabone, Mater Dei Hospital, University of Malta, Malta.

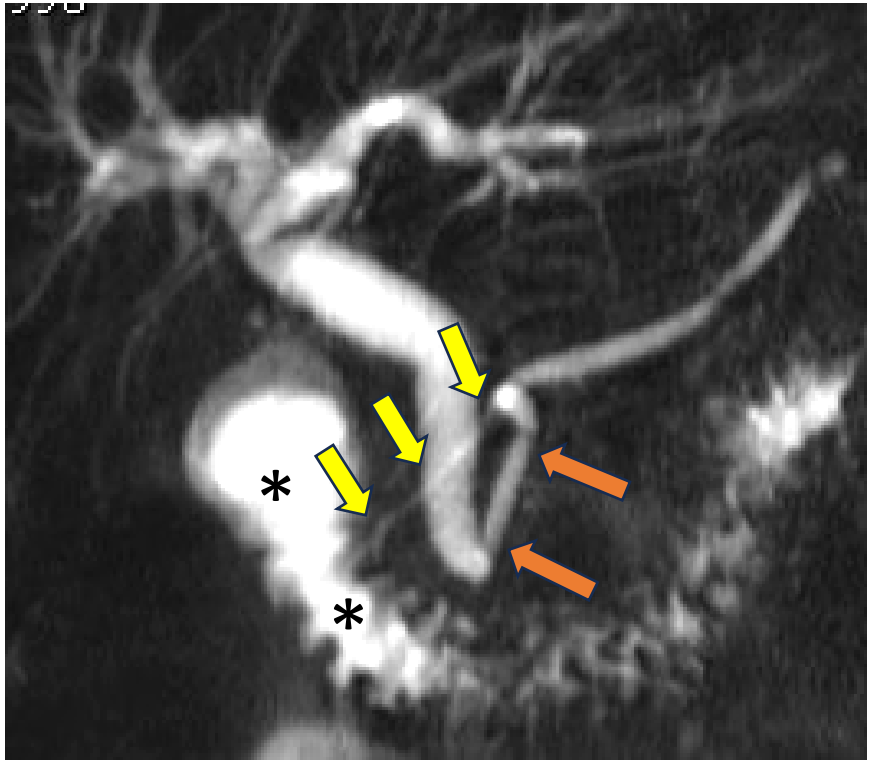

MRCP of the normal ductal anatomy with the duct of Wirsung (orange arrows) communicating with the duct of Santorini (yellow arrows). Asterisks correspond to fluid contents in the duodenum.

Chapter Outline

Imaging Techniques for the Pancreas: MRI

Advantages of MRI :

- No radiation exposure. May be used instead of CT if iodinated contrast material is contraindicated
- Interrogation of pancreatic tissue with several different sequences, including perfusion and diffusion mapping allows for differentiated information about inflammatory and neoplastic changes
- MRCP enables non-invasive depiction of the pancreatic and biliary ductal pathologies at the same time.

Disadvantages of MRI :

- Limited accessibility, cost
- Use of Gadolinium-based iv. contrast material
- Restrictions in claustrophobic patients and in patients with electronic implants

Chapter Outline

Other Imaging Techniques for the Pancreas

Endoscopic ultrasonography (EUS) uses a transducer which is mounted on a flexible gastrointestinal endoscope which is inserted into the lumen of the upper gastrointestinal tract (stomach and duodenum for pancreas assessment). The ultrasound transducer has a very high resolution at a limited field depth. Since EUS is done from the inside of the stomach and duodenum, it is much less hampered by bowel gas than standard transcutaneous US.

EUS can be used as a complement to CT or MRI for the diagnosis of pancreatic pathologies, including guided biopsy and minimally invasive drainage procedures.

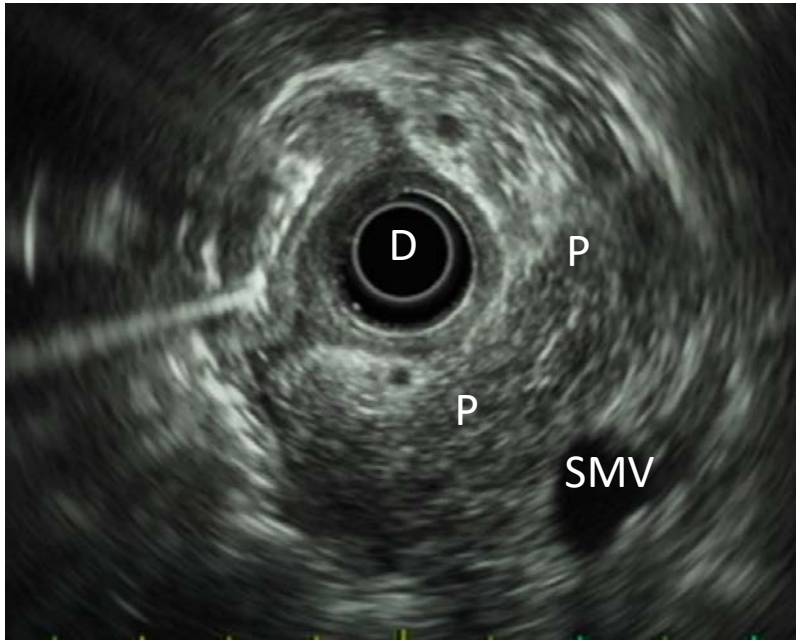

Radial EUS of the pancreatic head (P) viewed from the position of the endoscope, which is in the duodenum (D). SMV= superior mesenteric vein

Chapter Outline

Other Imaging Techniques for the Pancreas

Endoscopic retrograde cholangio-pancreatography (ERCP) is based on the combination of flexible endoscopy of the upper gastrointestinal tract and fluoroscopy. The technique is mainly used for minimally invasive endoscopic interventions. After cannulation of the papilla of Vater, the ductal system is opacified under fluoroscopic control with iodinated contrast material.

Intraductal interventional procedures can be performed through an instrumentation channel under direct and fluoroscopic vision and include electrocautery of the sphincter Oddi (endoscopic sphincterotomy), stone extraction, balloon dilatation and stenting of post-inflammatory ductal strictures, ductal system tissue sampling, and internal drainage procedures with catheters.

Although the technical success rate is quite high in experienced hands, ERCP is an invasive technique and may be complicated by bleeding, infection, perforation or acute pancreatitis.

Chapter Outline

Other Imaging Techniques for the Pancreas

Digital subtraction angiography (DSA) is a minimally invasive technique in which a 1.7 mm catheter is inserted via the femoral artery into the CA or SMA under fluoroscopic control.

Because the major pancreatic vessels are well delineated with CT and MRI, DSA is not frequently required for diagnostic purposes. It is mainly indicated in the context of intra-arterial interventions e.g., for pseudoaneurysms complicating pancreatitis or for haemostatic embolisation in acute haemorrhage.

DSA shows the anatomic detail of pancreatic head including the pancreaticoduodenal arcades (arrows) originating from the gastroduodenal artery (GDA).

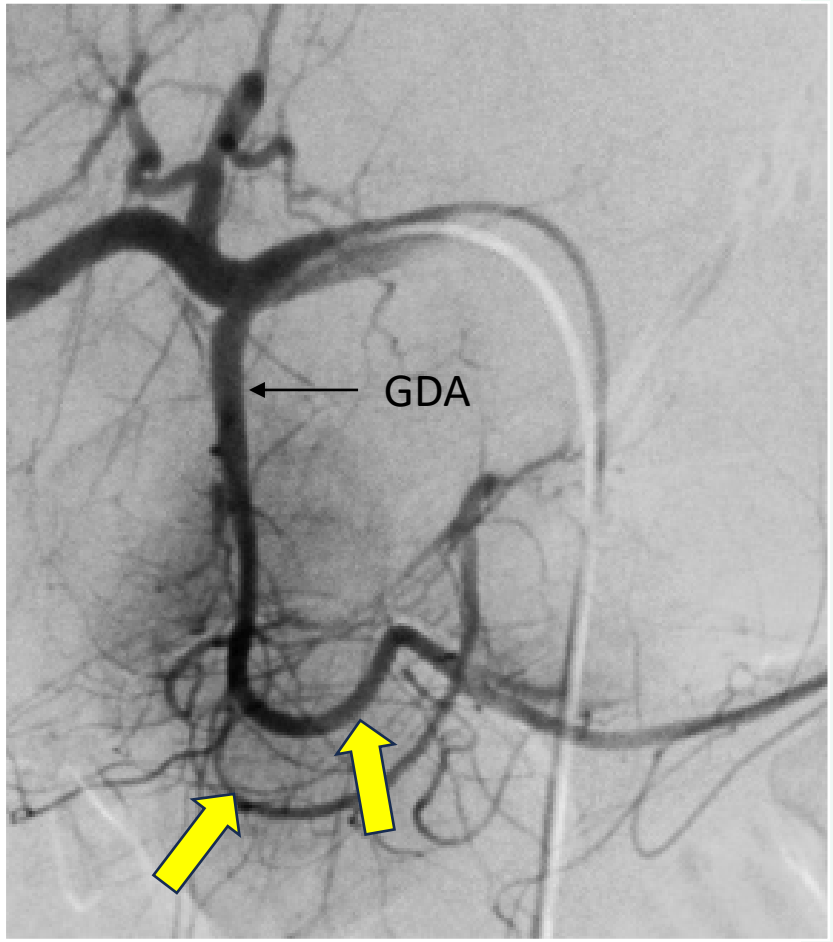

Chapter Outline

Other Imaging Techniques for the Pancreas

Positron emission tomography - computed tomography scan (PET/CT) combines PET with CT to provide information about the distribution of radioactive functional biomarkers. The choice of the biomarkers depends on the indication. In the presence of pancreatic tumours, PET with 18F-fluorodeoxyglucose (FDG) can be used to detect intrapancreatic exocrine neoplasms and extra-pancreatic focal uptake in lymph nodes or in distant locations, whereas PET with 68-Ga DOTATATE has the potential to delineate functionally active endocrine pancreatic neoplasms.

=> See also e-book chapter on nuclear medicine!

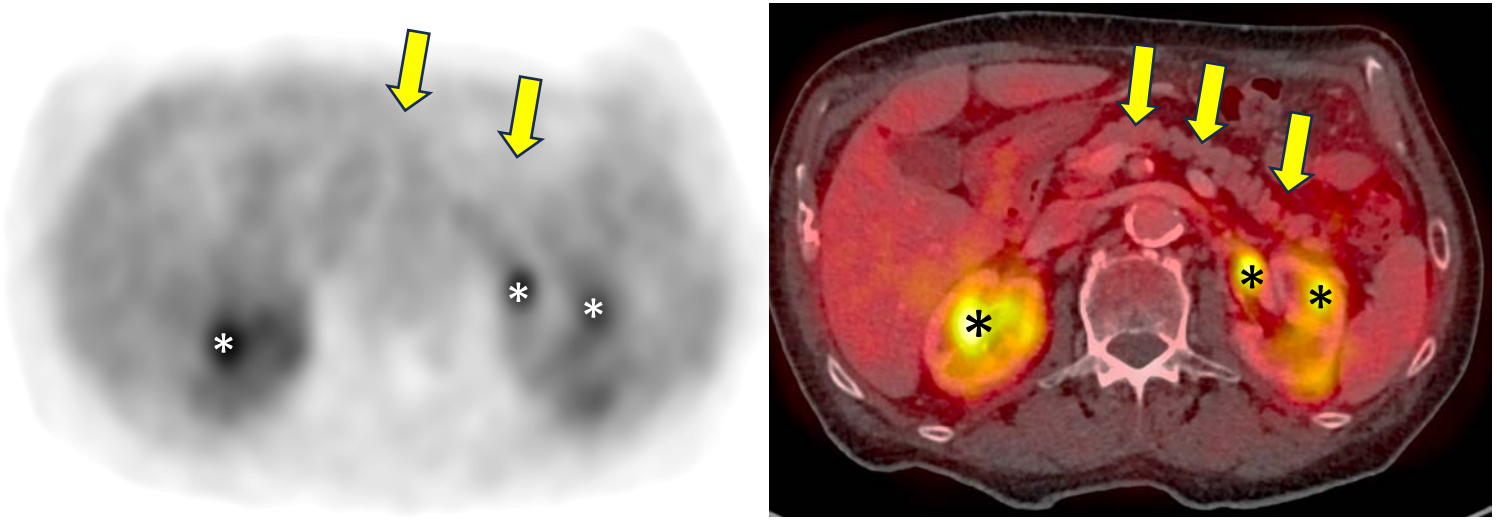

18-FDG PET/CT (axial PET image on the left, fused PET and corresponding CT image on the right) shows a normal pancreas (arrows) without hypermetabolic foci. Note normal FDG excretion via the kidneys (asterisks.

Chapter Outline

Imaging Techniques for the Spleen

Ultrasonography (US) usually allows visualisation of the splenic tissue via an intercostal acoustic window without interference due to bowel gas. Doppler-US with or without contrast material may add useful information about the patency of vessels and the homogeneity of parenchymal perfusion.

Complete, contrast-enhanced CT and MRI of the upper abdomen always include the spleen and the major splenic vessels and can detect a variety parenchymal abnormalities
and variants such as ectopic splenic tissue. The advantages and disadvantages of CT and MRI for the spleen are the same as for the pancreas.

Scintigraphy can be used to identify ectopic splenic tissue by the uptake of Tc-99 sulphur colloid

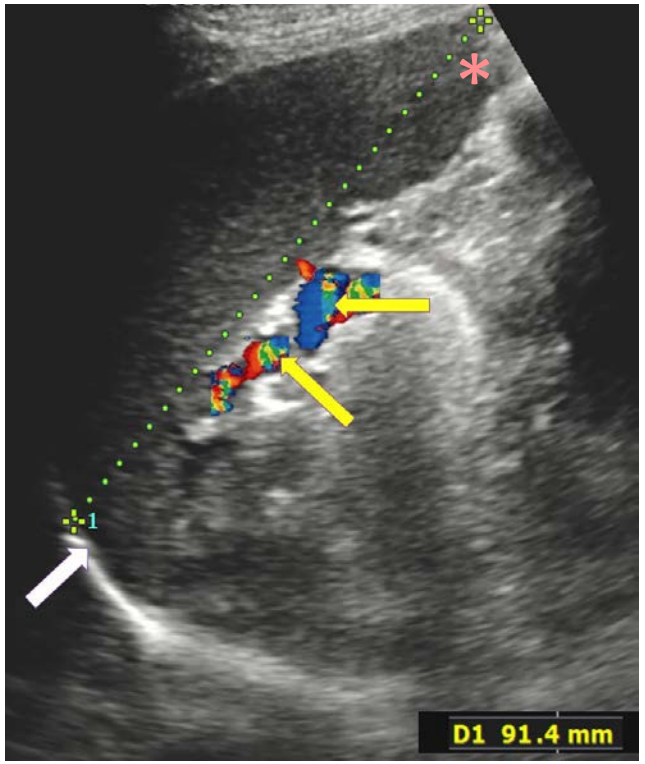

Doppler US of the spleen (longitudinal view) shows a normal, fine, homogenous organ texture with smooth margins and a pointed inferior edge (asterisk). Splenic hilum with splenic arteries and veins (yellow arrows). White arrow points at the diaphragm. Normal spleen size.

Chapter Outline

Imaging Techniques for the Spleen

During the arterial phase of contrast-enhanced CT, MRI or US, the spleen shows an inhomogeneous enhancement, also called "tiger spleen" or "zebra spleen". This enhancement pattern is caused by the fact that red pulp enhances earlier than while white pulp (see anatomy). In the portal venous phase, the normal spleen will typically show homogenous enhancement.

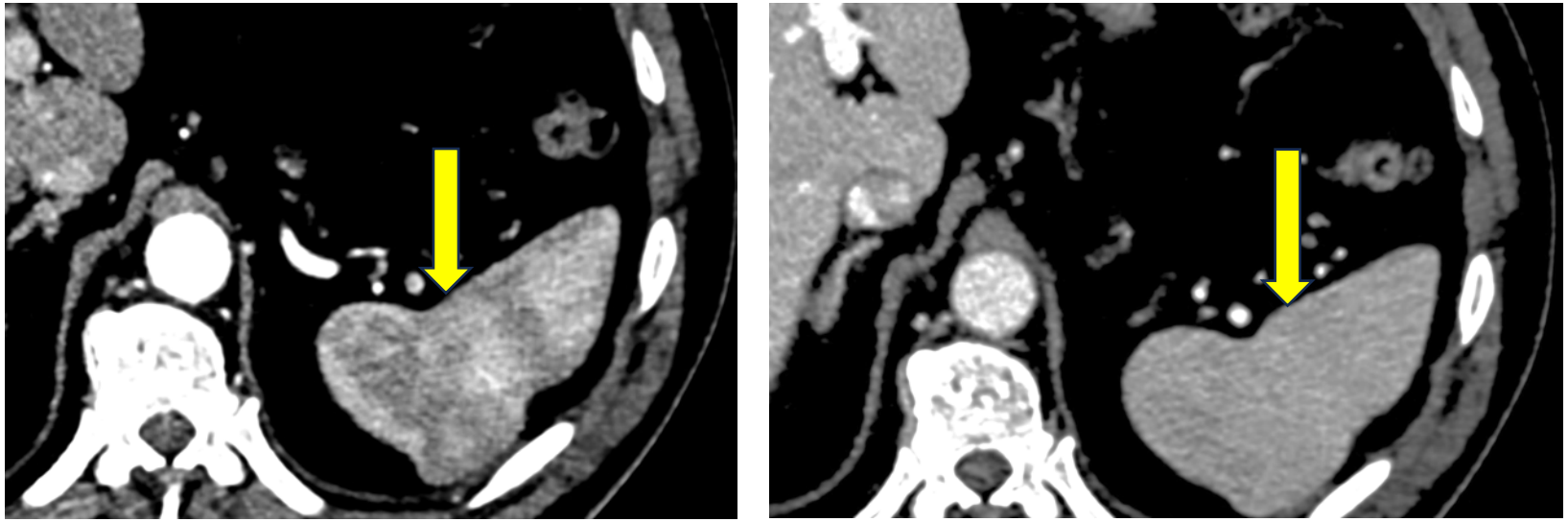

Multiphasic contrast-enhanced CT showing the arterial (image on the left) and portal (image on the right) phases of contrast enhancement. Note inhomogeneous enhancement in the arterial phase and homogenous enhancement in the portal venous phase (arrows).

Chapter Outline

Variants of Diagnostic Importance

Some variants of pancreatic and splenic anatomy are of diagnostic importance, either because they may predispose to complications or because they may give rise to differential diagnosis with other conditions. Such variants include those of the pancreatic ductal system and the parenchyma of the pancreas and spleen.

The pancreatic duct of Wirsung is usually dominant and forms a major papilla with the common bile duct to join the duodenum. Due to fusion of the dorsal and ventral pancreatic ducts, the duct of Santorini usually communicates with the duct of Wirsung and joins the duodenum with a minor papilla. However, many variants exist regarding ductal anatomy. Pancreas divisum occurs due to non-fusion of the dorsal and ventral pancreatic ducts and results in separation of the ducts of Santorini and Wirsung; this variant may predispose to pancreatitis. Pancreas divisum occurs in about 10% of the population.

Annular pancreas is a variant in which the parenchyma of the pancreatic head encircles the duodenal lumen.

Accessory splenic tissue (splenunculus) may give rise to differential diagnostic problems.

Chapter Outline

Pancreas Divisum

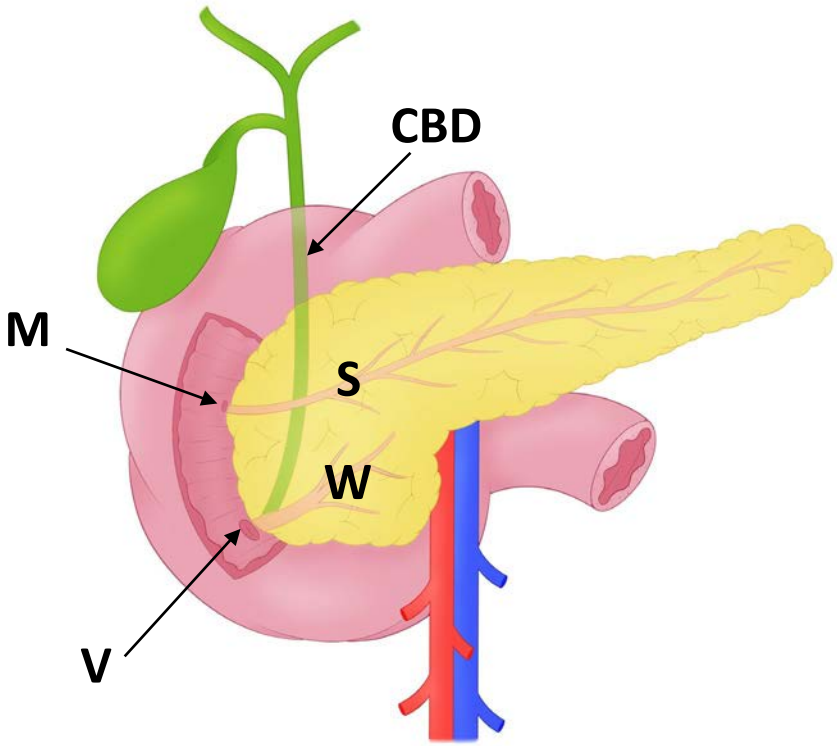

Schematic illustration of the anatomical relationship between the main pancreatic duct of Wirsung (W), the accessory pancreatic duct of Santorini, (S), the common bile duct (CBD) and the duodenum in pancreas divisum. V = ampulla of Vater; M = minor papilla

Illustration by Emma Tabone, Mater Dei Hospital, University of Malta, Malta.

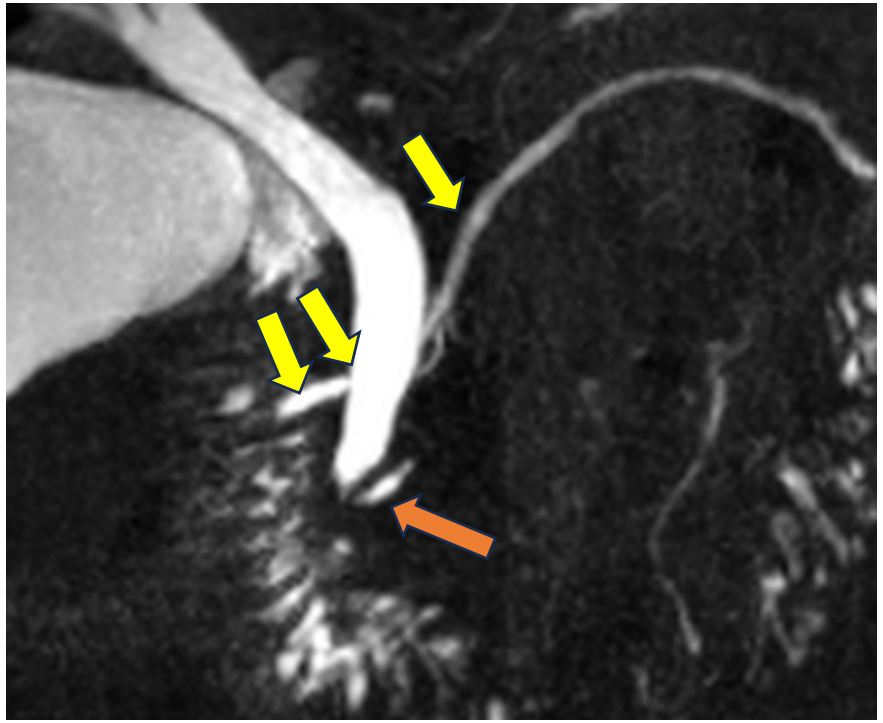

MRCP showing pancreas divisum. Duct of Santorini drains as main duct into minor papilla (yellow arrows). Duct of Wirsung drains in the lower pancreatic head and joins the common bile duct (orange arrow).

Chapter Outline

Annular Pancreas

Annular pancreas is a morphological anomaly that results in pancreatic tissue completely or incompletely encircling the duodenum.

Although it is often asymptomatic it can also be responsible for clinical symptoms such as abdominal pain, postprandial fulness or vomiting due to duodenal obstruction, or pancreatitis. The condition is often recognised in adult life as an unexpected finding on CT or MRI.

Regarding ductal anatomy, the annular duct may either join the duct of Wirsung or the duct of Santorini.

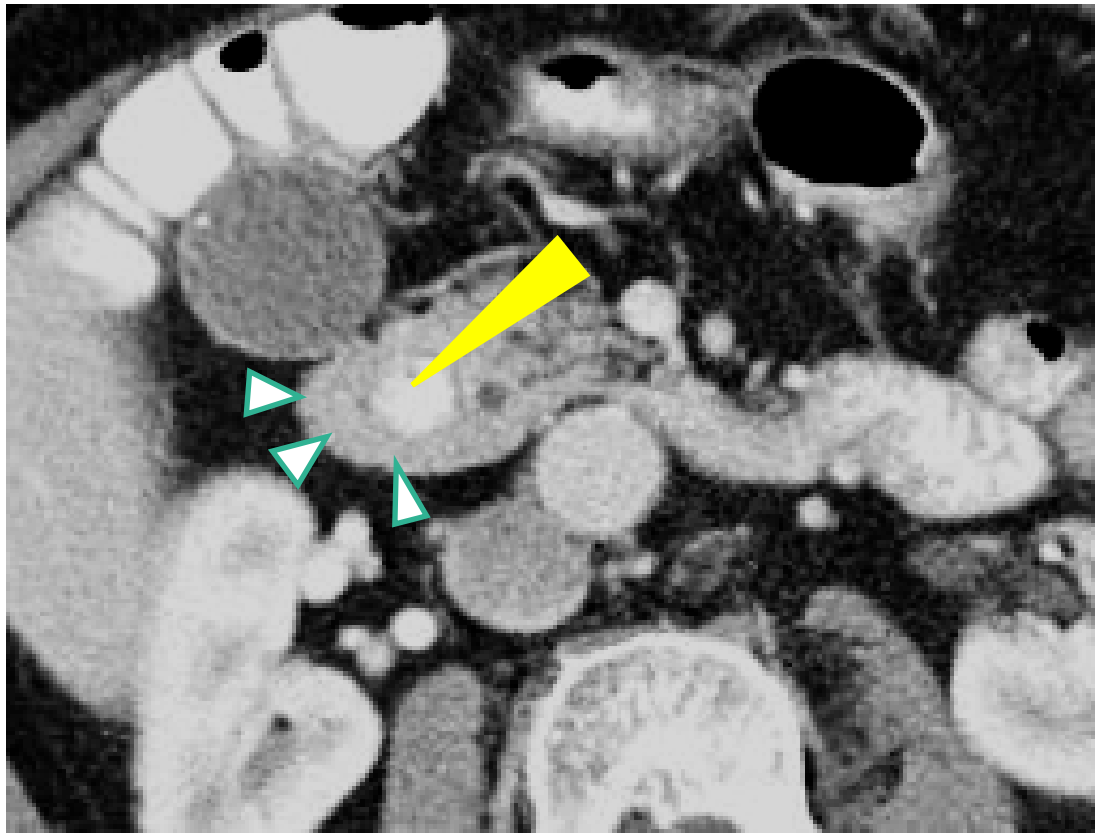

Contrast-enhanced CT (axial image) showing annular pancreas. Pancreatic head tissue (small arrowheads) entirely surrounds the duodenum. Large arrowhead points to contrast-filled duodenal lumen.

Image courtesy: Oskar Bożek, MD, Department of Radiodiagnostics and Invasive Radiology, Faculty of Medical Sciences in Katowice, Medical University of Silesia.

Chapter Outline

Accessory Splenic Tissue (Splenunculus)

Accessory ectopic splenic tissue (splenunculus) are nodules of normal splenic tissue that may occur in many sites of the abdomen, including the peritoneal surface, ligaments, and the omental structures. A common site is the vicinity of the splenic hilum or the pancreatic tail.

Although no treatment is usually required, ectopic splenic tissue may be mistaken for a mass lesion of another origin including neoplasm. Furthermore, depending on its location, accessoray splenic nodules may cause acute complications such as torsion or infarction, presenting in the form of acute abdominal pain.

At cross-sectional imaging with US, CT or MRI , ectopic splenic tissue shows the same tissular pattern and the same dynamic enhancement pattern as the main splenic tissue.

If necessary, 99-Tc sulfur colloid scintigraphy may be used to confirm the splenic nature of a lesion.

Chapter Outline

Accessory Splenic Tissue (Splenunculus)

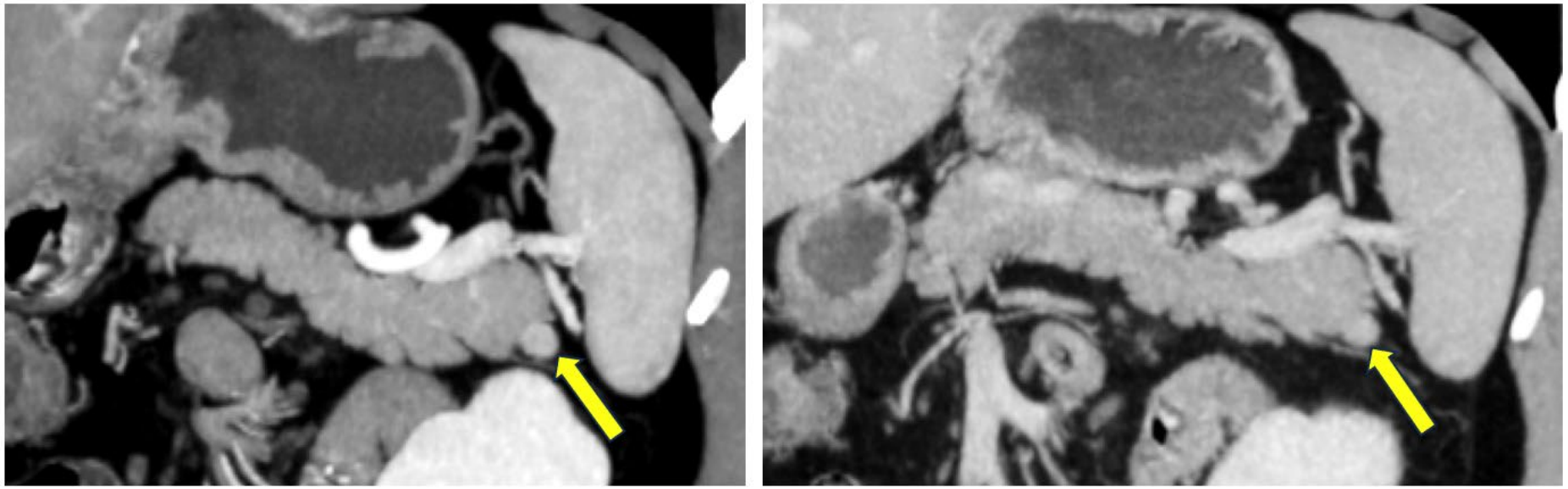

Abdominal multiphasic CT (coronal multiplanar reconstruction) showing a nodule of accessory spleen in the tail of the pancreas. In all phases of contrast enhancement, the enhancement pattern of the lesionin the pancreatic tail is the same as the spleen.

Images courtesy: Oskar Bożek, MD, Department of Radiodiagnostics and Invasive Radiology, Faculty of Medical Sciences in Katowice, Medical University of Silesia.

Chapter Outline

Acute Pancreatitis

Acute pancreatitis is a common cause of admission for acute abdominal pain, the most common aetiologies for pancreatitis being migration of gallstones and alcohol use. Other aetiologies may include iatrogenic instrumentation of the ampulla of Vater, neoplastic obstruction of the main pancreatic duct, or ductal injury with extravasation of pancreatic juice in the context or blunt abdominal trauma.

Acute pancreatitis in adults can be classified according to the revised Atlanta classification. From a clinical point of view the severity of acute pancreatitis may be graded as mild (no local or systemic complications); moderately severe (local or systemic complications but without organ failure) and severe (including persistent organ failure).

Regarding local complications it is important to distinguish the more self-limited, interstitial oedematous form of acute pancreatitis from the necrotising form, which occurs in ≤10% but has a much higher morbidity and mortality. Patients with necrotising pancreatitis are often in a critical clinical state and require intensive care. This may cause some limitations to the use diagnostic imaging modalities from a logistic point of view (patient transfer, monitoring, collaboration, etc).

Local complications of severe acute pancreatitis include the formation of large or infected fluid collections which may compress adjacent abdominal organs or become superinfected, with the risk of sepsis and extensive retroperitoneal fat necrosis. Vascular complications include thrombosis of major peripancreatic vessels and formation of arterial pseudoaneurysms with the risk of severe acute intra-abdominal haemorrhage.

Chapter Outline

Imaging in Acute Pancreatitis

The diagnosis of acute pancreatitis at emergency admission is usually based on clinical symptoms and laboratory findings. Since cholelithiasis is the most common cause of acute pancreatitis, US is indispensable and should be performed in all patients with suspected acute pancreatitis. However, contrast-enhanced CT is the imaging method of choice for further characterisation of acute pancreatitis and detection of local complications. If the diagnosis can be established clinically, patients with mild pancreatitis may not require CT imaging at the time of admission. However, acute pancreatitis is an evolving, dynamic condition which may change in severity over time. In moderately severe and severe acute pancreatitis follow–up CT imaging is, therefore, often required to assess the course of the disease and detect developing complications

According to the revised Atlanta classification, imaging has a key role in distinguishing between acute interstitial oedematous pancreatitis in which contrast enhancement of the gland on CT is intact and where key diagnostic findings may include diffuse or focal swelling of the gland, infiltration of the peripancreatic fat and acute peripancreatic fluid collections or pseudocysts (of homogeneous liquid content) from acute necrotising pancreatitis in which variable portions of the parenchyma lack contrast enhancement on CT and where key diagnostic findings may include solitary or multiple intra- or peripancreatic necrotic collections or walled- of necrotic areas with heterogeneous liquid/non-liquid content. The non-liquid content of these lesion is more conspicuous on US and MRI than on CT.

MRI may be used as an alternative to CT if iv. injection of iodinated contrast material is contraindicated. MRCP is the method of choice for non-invasive delineation of ductal anomalies. Unlike CT, however, MRI is not always possible in severely ill patients who cannot cooperate and who are equipped with electronic and ferromagnetic accessory devices that are incompatible with use in the magnetic field.

Chapter Outline

Acute Oedematous vs. Acute Necrotising Pancreatitis

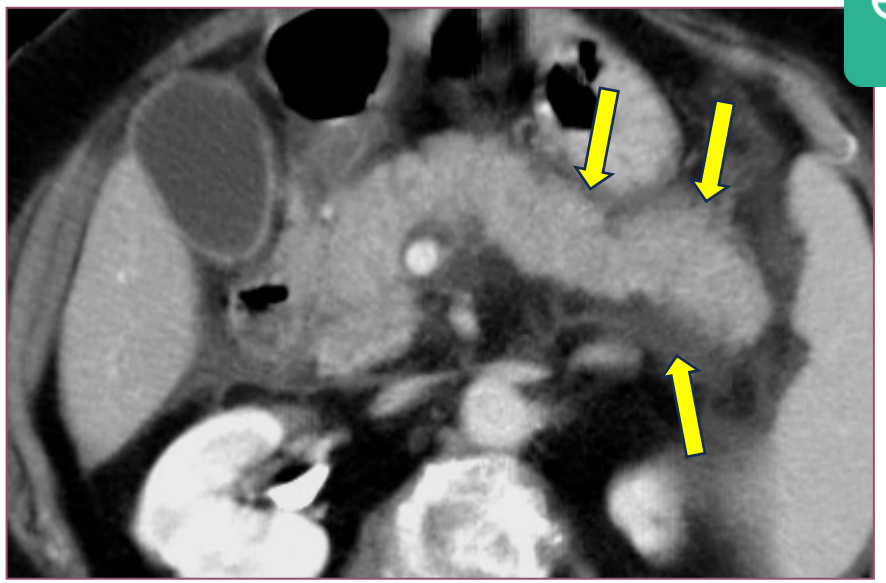

CT (portal phase) showing oedematous acute pancreatitis. Glandular swelling, moderate infiltration of peripancreatic fat (arrows) no major peripancreatic fluid collections, homogeneous enhancement of gland.

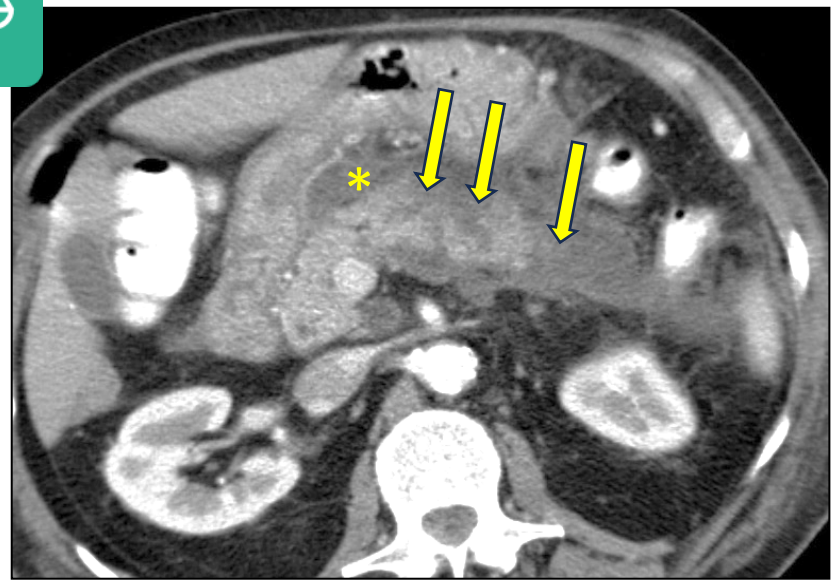

CT (pancreatic phase) showing necrotising acute pancreatitis. Inhomogeneous, incomplete enhancement of the gland with non-enhancing areas (arrows). Intra- and peri-pancreatic fluid collections (*) due to haemorrhage and exudate.

Chapter Outline

Local Complications of Acute Pancreatitis

Fluid collections in interstitial oedematous pancreatitis can be distinguished according to the revised Atlanta classification as

- non-encapsulated peripancreatic fluid collections (in the first 4 weeks) and
- encapsulated peripancreatic or remote fluid collections or well-defined pseudocysts (after 4 weeks).

Fluid collections in necrotising pancreatitis are defined as

- acute necrotic collections (occurring in the first 4 weeks) which are not encapsulated and contain heterogeneous non-liquefied material, as opposed to
- walled-off necrosis (developing after 4 weeks) in which collections are encapsulated and contain heterogeneous non-liquefied material

All of these collections may cause clinical symptoms, either due to compression of the adjacent common bile duct (jaundice) or gastrointestinal tract (vomiting) or due to infection (sepsis).

The distinction between infected and noninfected collections can often be made by image-guided percutaneous fine needle aspiration. Although infected pancreatic fluid collections can be drained externally by percutaneous catheters under CT or US guidance, minimally invasive treatment of established pseudocysts is preferably done by means of EUS-guided internal drainage into the gastrointestinal tract.

Vascular complications of acute pancreatitis include thrombosis of major peripancreatic arteries or veins and formation of arterial pseudoaneurysms, as well as acute haemorrhage. Potential or active sources of arterial bleeding are best treated with angiographic embolisation.

Chapter Outline

Pancreatic and Peripancreatic Collections after Acute Oedematous and Acute Necrotising Pancreatitis

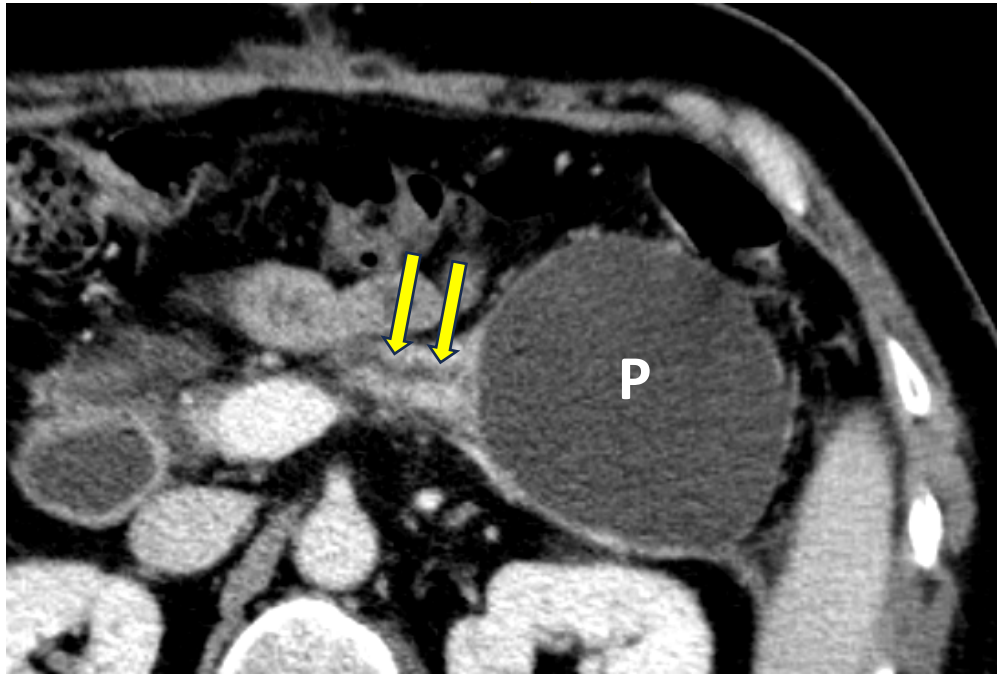

Pancreatic pseudocyst (>4 weeks). CT (portal phase) showing a large rounded encapsulated collection 5 weeks after acute oedematous pancreatitis, corresponding to a pseudocyst (P) in the pancreatic tail. Pancreatic duct (arrows).

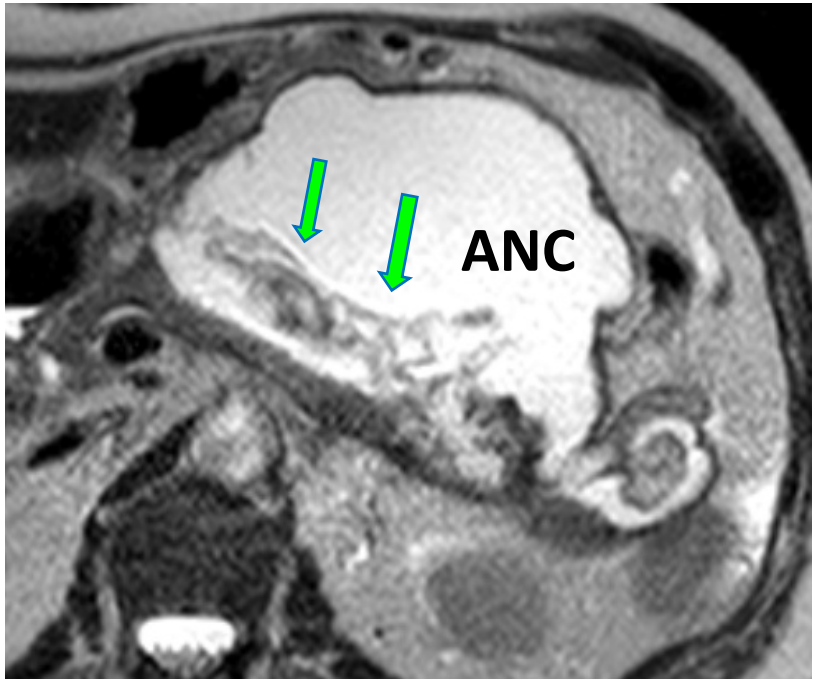

Acute necrotic collection (<4 weeks). MRI (transverse T2-weighted image) showing a large irregular-shaped acute necrotic pancreatic collection (ANC) containing heterogeneous debris due to haemorrhage or exudate (arrows) 3 weeks after the onset of necrotising pancreatitis.

Chapter Outline

Pancreatic and Peripancreatic Collections After Acute Necrotising Pancreatitis

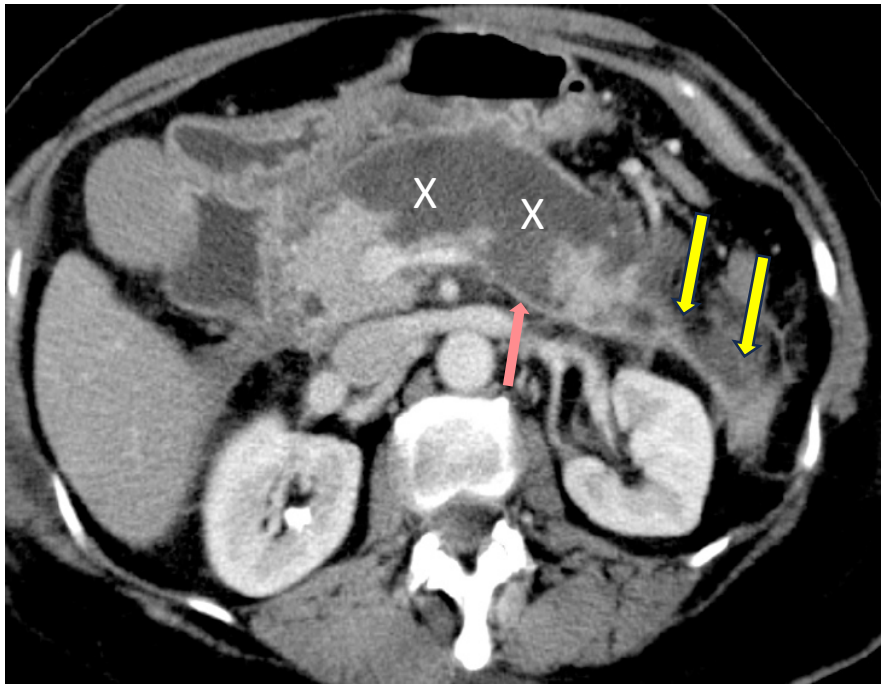

Acute necrotic collection (<4weeks). CT (portal phase) shows a large devascularised portion of the pancreatic body and formation of an acute necrotic collection (X), thrombosis of the splenic vein (pink arrow) and fat stranding of the anterior pararenal space (yellow arrows), 2 weeks after the onset of acute necrotising pancreatitis

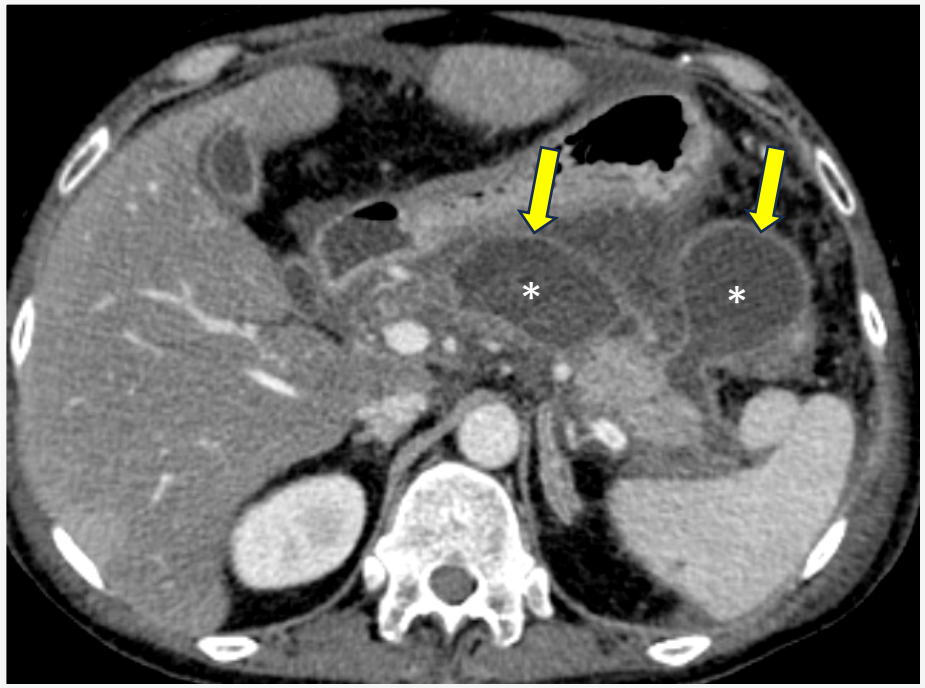

Walled-off necrotic collections (>4weeks). CT (portal phase) shows acute walled-off pancreatic and peripancreatic necrotic collections (asterisks) 6 weeks after the onset of acute necrotising pancreatitis. The collections have a slightly enhancing defined wall of granulomatous tissue (arrows).

Chapter Outline

Further Complications of Acute Pancreatitis

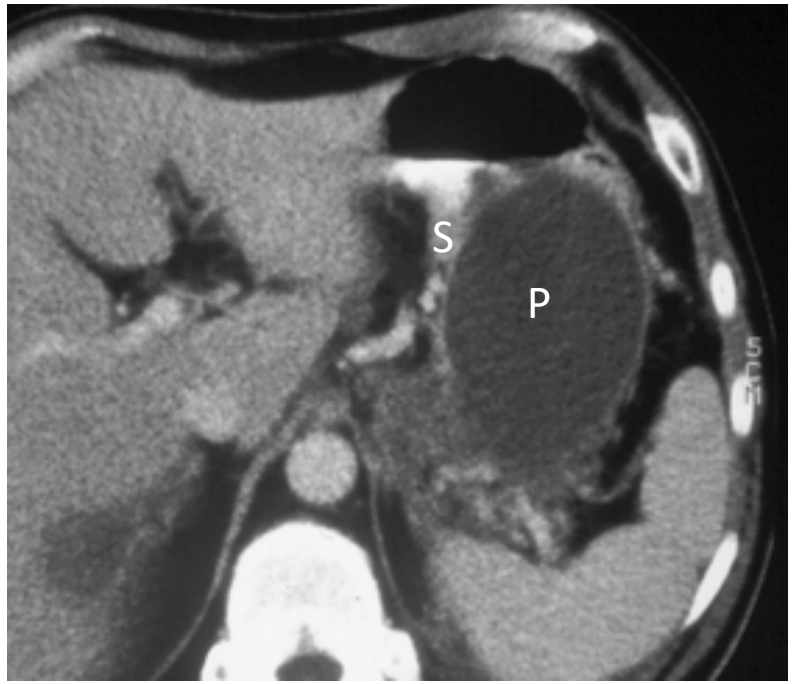

Pancreatic pseudocyst compressing the stomach. CT (portal phase) showing a large rounded encapsulated collection 5 weeks after acute oedematous pancreatitis, corresponding to a pseudocyst (P) in the lesser sac, compressing the stomach (S)

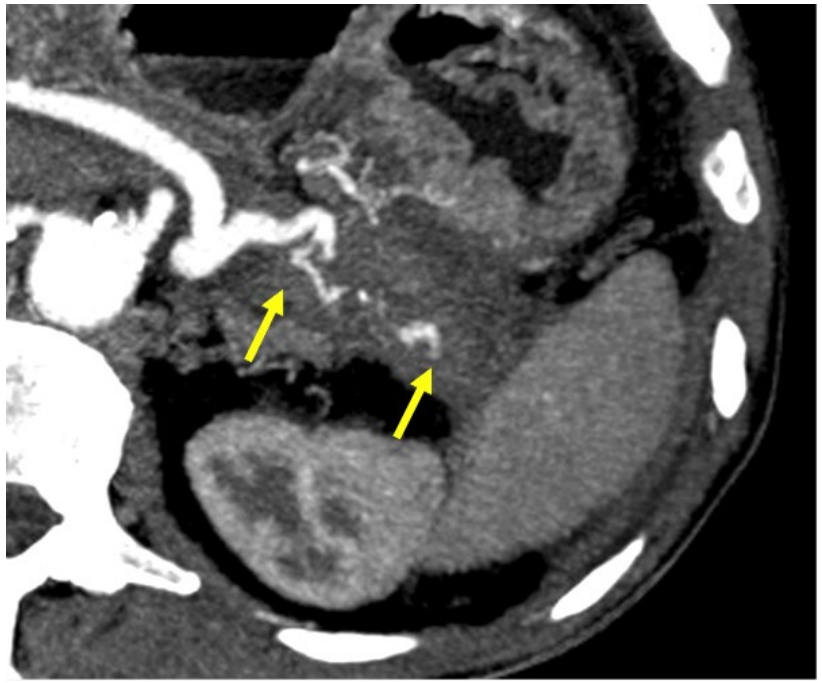

Thrombosis of splenic artery. Dynamic contrast-enhanced CT (arterial phase) shows complete occlusion of the splenic artery with beginning collaterals (arrows) complicating acute pancreatitis.

Chapter Outline

Image-Guided Fluid Aspiration in Acute Pancreatitis

Bacterial superinfection occurs commonly in necrotising pancreatitis and carries a high risk of abdominal sepsis. CT-guided fine-needle aspiration allows for the diagnosis of infection and specification of germs.

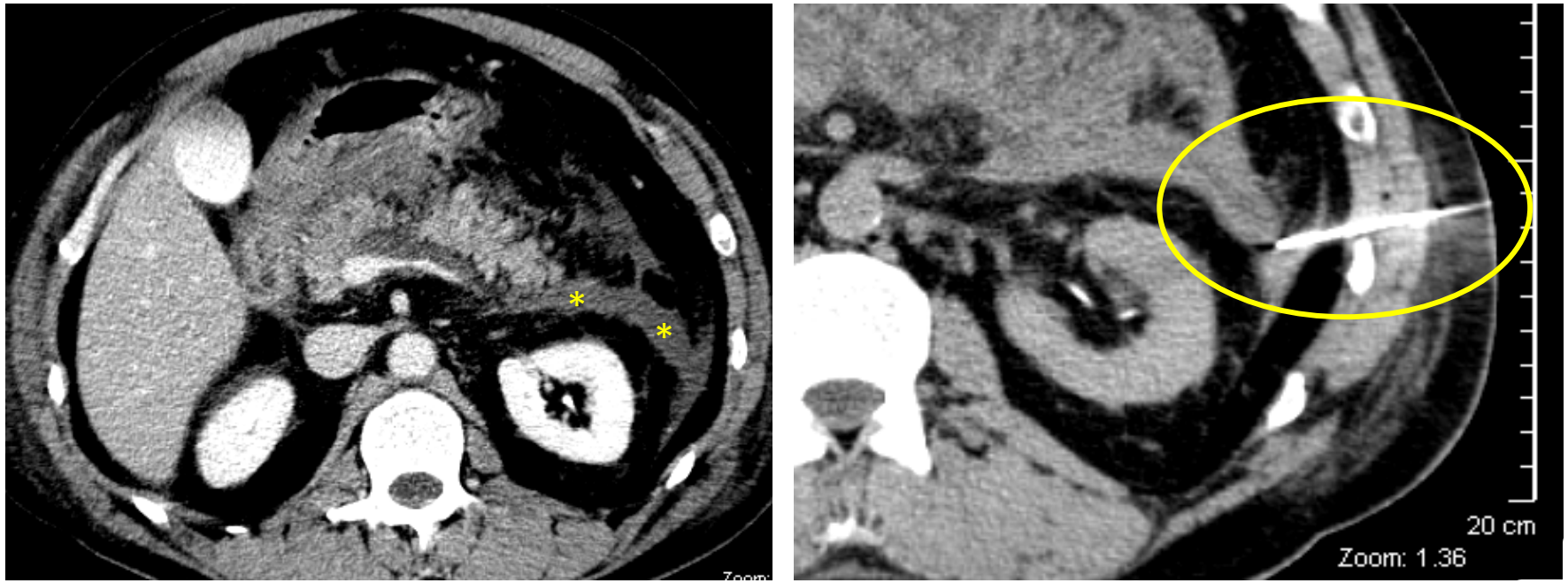

CT-guided fluid aspiration. Left image: CT (portal phase) showing free fluid (asterisks) in the presence of clinical signs of infection. Right image: CT-guided needle placement within the fluid collection (yellow ellipse) for the diagnosis of infection and specification of germs..

Chapter Outline

Percutaneous Drainage of Complicated Pancreatic Fluid Collections

CT-guided percutaneous drainage with an indwelling pigtail catheter can be indicated as a temporary alternative to internal drainage during the first weeks in:

- large or increasing collections (>5cm diameter)
- symptomatic collections causing pain, gastric or duodenal compression
- infected collections

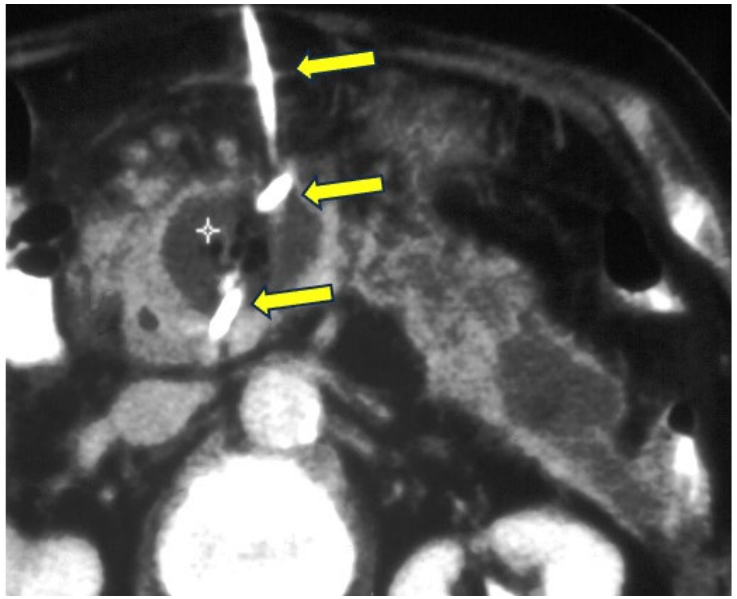

Pigtail catheters



Image on the left illustrates the CT set-up for an interventional procedure with the interventional radiologist targeting the area to punction under CT guidance. Image on the right illustrates the correct position of the pigtail catheter (arrows) in the infected pancreatic collection (+).

Chapter Outline

Chronic Pancreatitis

Chronic pancreatitis is the result of a recurrent inflammatory process leading to fibrosis, calcification, pseudocyst formation and ductal changes and eventually exocrine functional insufficiency of the pancreas. The aetiology of chronic pancreatitis is not fully understood and includes idiopathic but also toxic-metabolic causes (e.g., chronic alcohol consumption), and congenital predispositions such as pancreas divisum or pancreas annulare, as well as autoimmune diseases.

On cross-sectional imaging parenchymal changes include lack of perfusion due to fibrotic changes in chronically inflamed areas, atrophy, calcifications and fluid collections. Although these changes can be visualised on both CT and MRI, calcifications are better visualised with CT. The morphologic changes of the pancreatic parenchyma in the context of chronic pancreatitis may sometimes be very difficult to distinguish from pancreatic adenocarcinoma, and even a negative image guided biopsy cannot reliably rule out malignancy.

Ductal changes can be graded according to the Cambridge classification as equivocal, mild, moderate or severe, based on the extent of dilatation and stenosis, calculi and pseudocysts. Irregular calibre due to stenoses and dilated segments may appear as a "string of beads". Although the Cambridge classification was initially developed for ERCP, ductal changes may also be delineated noninvasively by means of MRCP.

Dynamic evaluation with MRCP after secretin stimulation may be used in selected cases to allows semi-quantitavie estimation of the exocrine secretory function and enhances anatomic detail.

Para-duodenal or "groove"-pancreatitis is an uncommon focal form of chronic pancreatitis in the space between the duodenum and pancreas. Cross-sectional imaging shows cystic thickening of the duodenal wall with or without duodenal stenosis. The fibrous tissue within the pancreatico-duodenal groove may show late enhancement after contrast administration. The inflammatory mass should not be confused with a neoplastic lesion.

Chapter Outline

Chronic Pancreatitis: Imaging Features

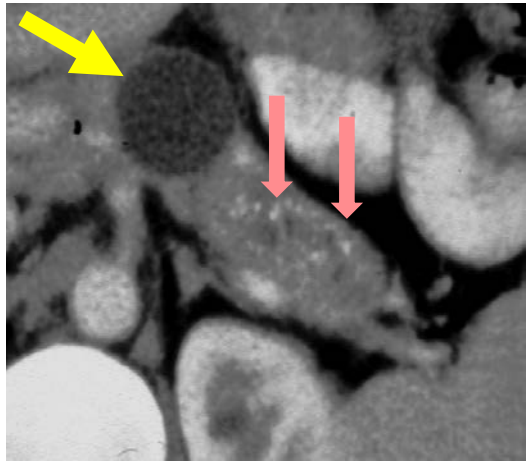

CT (pancreatic phase) shows **pseudocyst of pancreatic body** (yellow arrow) and multiple parenchymal **calcifications** (pink arrows).

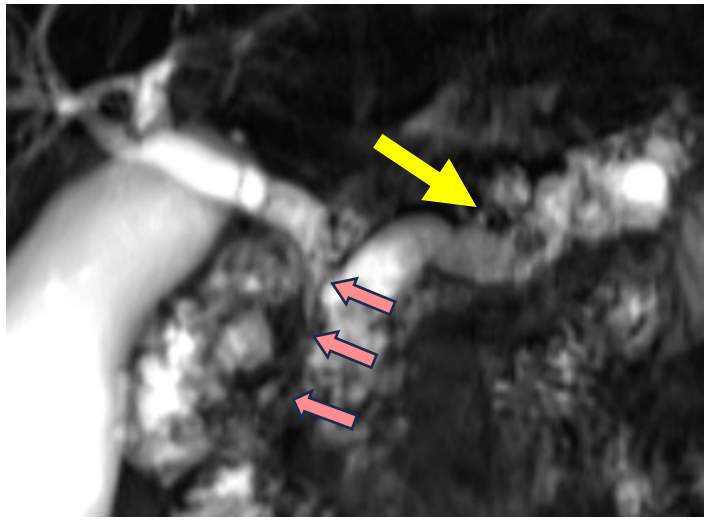

MRCP shows dilated main pancreatic duct with calculi (yellow arrow) as well as compression of distal common bile duct (pink arrows) .

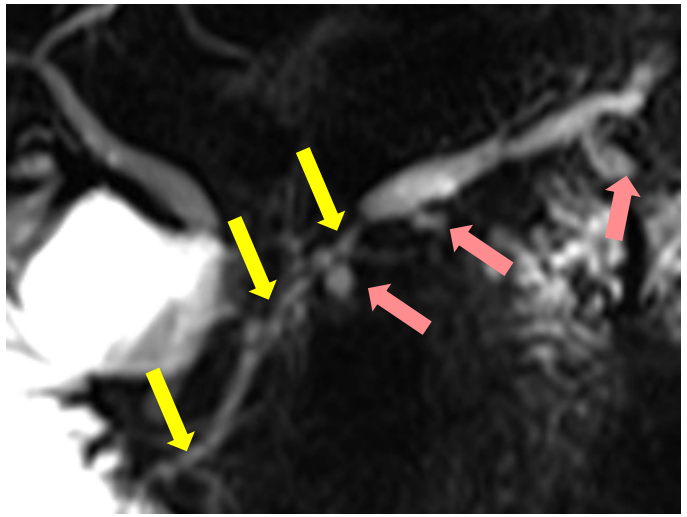

MRCP shows stenosis of main pancreatic duct, which has a « string of beads » appearance (yellow arrows) and shows dilatation of its distal portion. Note also dilatation of second order branches (pink arrows).

Chapter Outline

Chronic Pancreatitis: Imaging Features

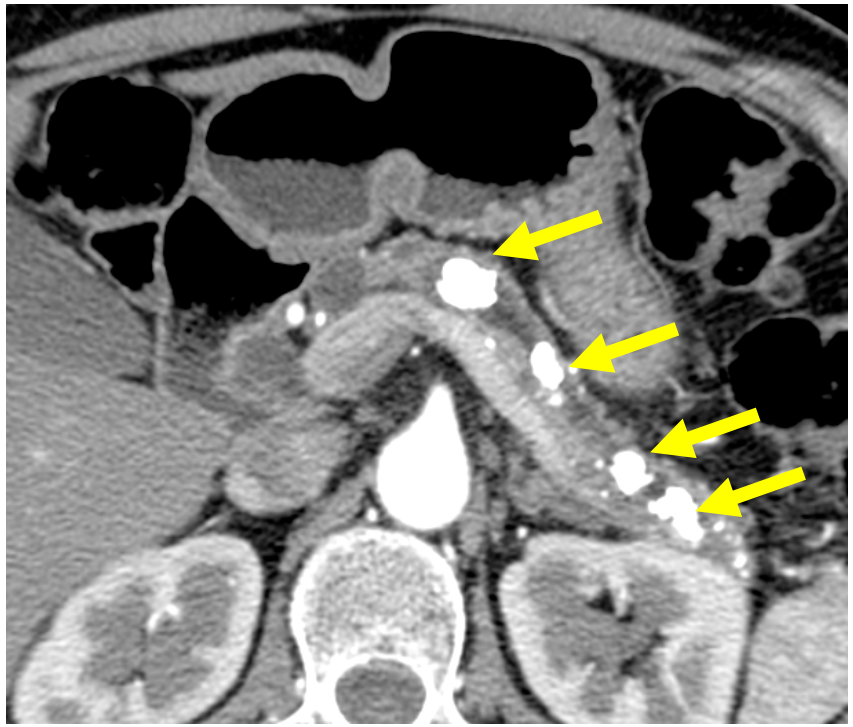

Contrast-enhanced CT (pancreatic phase) shows calcified calculi (arrows) within the dilated main pancreatic duct.

CT image courtesy: Oskar Bożek, MD, Department of Radiodiagnostics and Invasive Radiology, Faculty of Medical Sciences in Katowice, Medical University of Silesia.

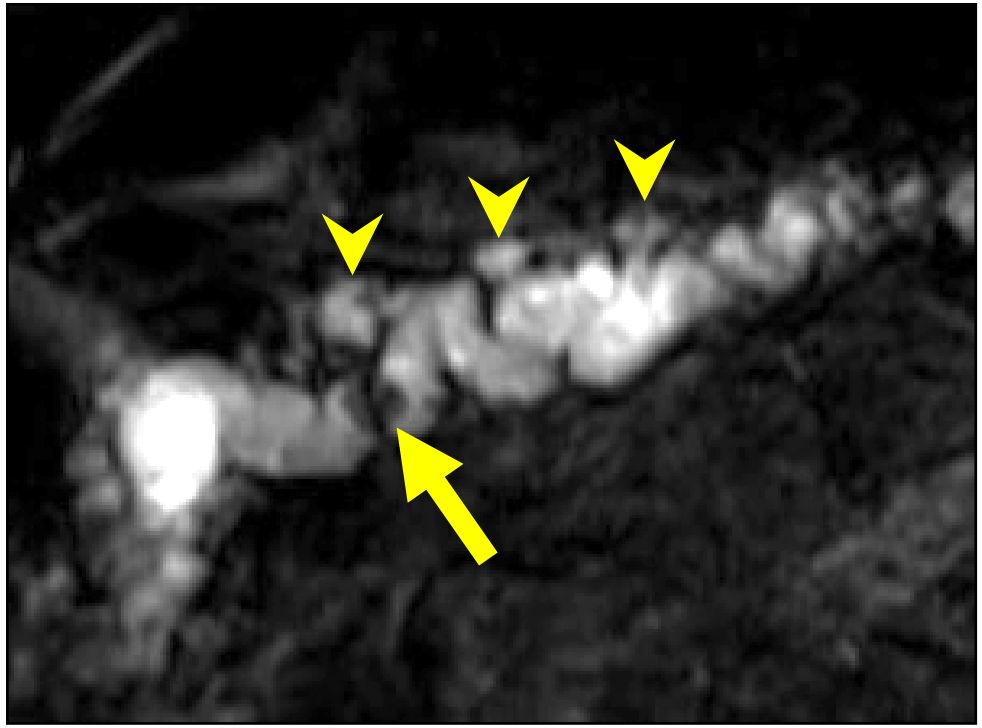

MRCP in a different patient shows a dilated main pancreatic duct and dilatations of second order branches (arrowheads), as well as ductal calculi, which present as filling defects (arrow).

Chapter Outline

Chronic Pancreatitis: Dynamic MRCP with Secretin Stimulation

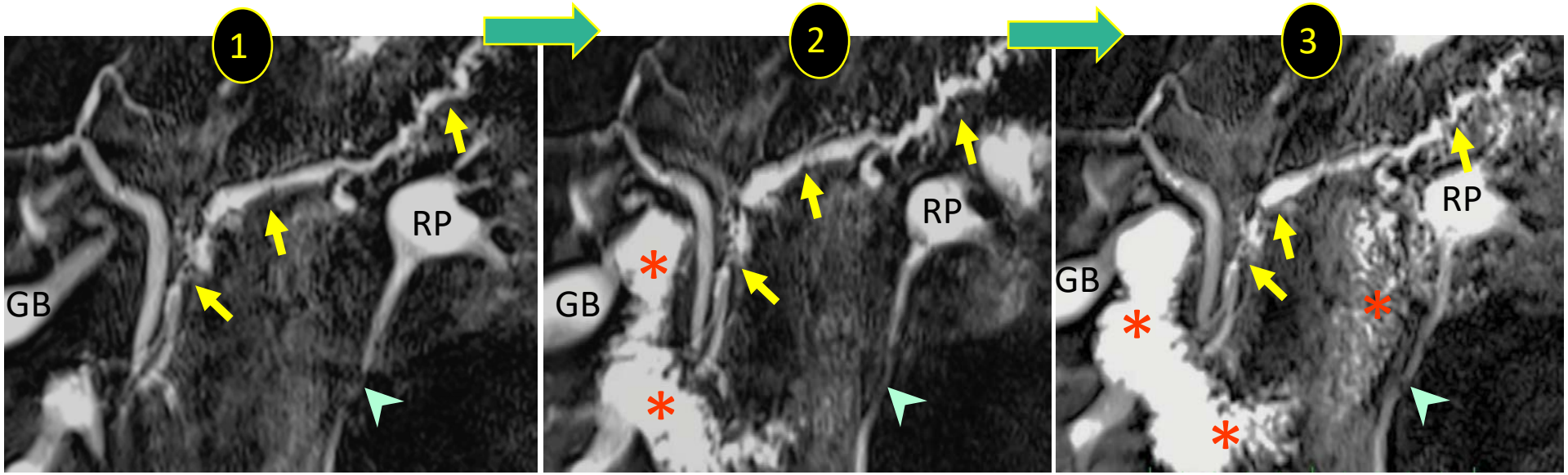

Selected frames (1-3) of a dynamic MRCP (coronal view) with secretin stimulation show stenosis and inflammatory irregularities of main pancreatic duct and secondary ducts (arrows) in chronic pancreatitis. Note increasing secretion of pancreatic juice after iv. injection of secretin with improved visualisation of ductal detail and progressive filling of the duodenum. Duodenum marked by asterisks. GB = gallbladder. RP = left renal pelvis. Left ureter (arrowhead).

Chapter Outline

Focal Chronic Pancreatitis of the Uncinate Process in Pancreas Divisum

Although patients with pancreas divisum are usually asymptomatic, about 25% - 35% of these patients experience recurrent pancreatitis, which may lead to the development of chronic pancreatitis.

Pancreas divisum can explain why chronic pancreatitis changes can be limited to the lower part of the pancreatic head and uncinate process.

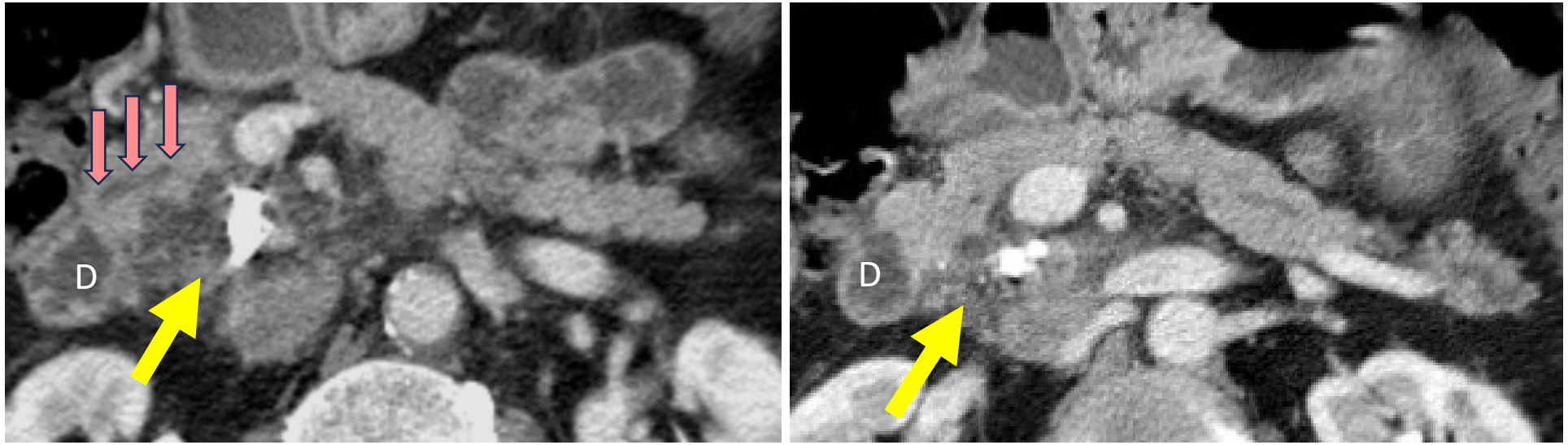

Multiphasic contrast-enhanced CT (pancreatic phase image on the left and portal phase image on the right) shows reduced enhancement and calcifications of the uncinate process (yellow arrow) compared with the rest of the pancreas which is drained by Santorini's duct (pink arrows) into the duodenum (D).

Chapter Outline

Focal Chronic Pancreatitis of the Uncinate Process in Pancreas Divisum

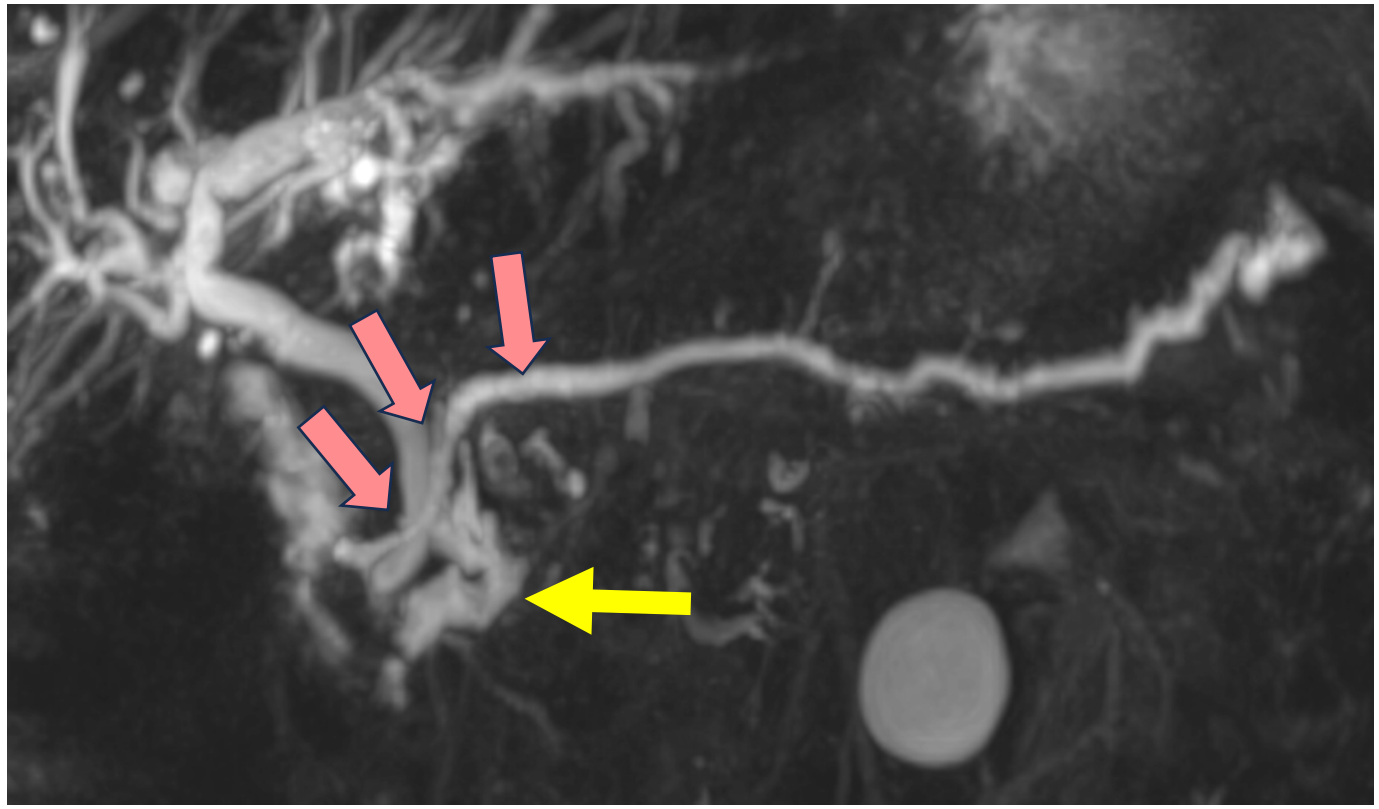

MRCP showing normal duct of Santorini and main pancreatic duct (pink arrows). Dilated duct of Wirsung due to chronic pancreatitis in the uncinate process (yellow arrow).

Chapter Outline

Paraduodenal ("Groove-") Pancreatitis: Imaging Features

Groove pancreatitis is a form of chronic inflammation involving the anatomic space between the duodenal wall and the pancreatic head. Although it can have cystic components, it may also appear as a mass and therefore, be difficult to distinguish from a malignant tumour.

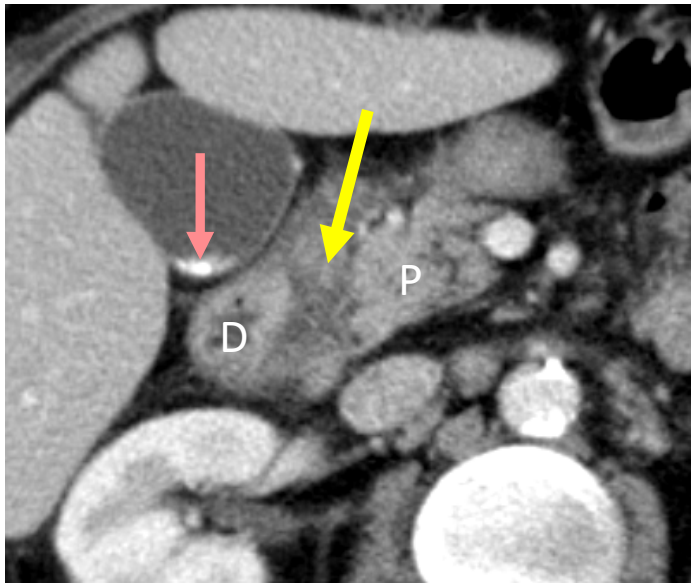

Contrast-enhanced CT (axial pancreatic phase image) shows a hypodense zone (yellow arrow) between the duodenum (D) and the pancreatic head (P). Note the presence of gallbladder stones (pink arrow).

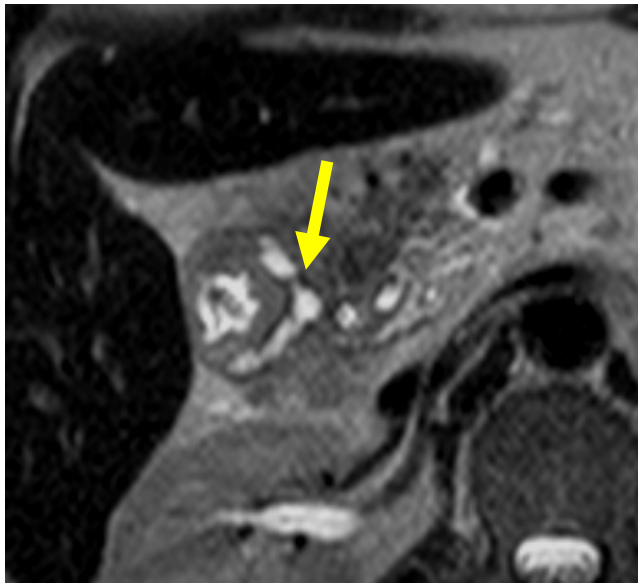

MRI (T2-weighted, transverse image) shows cystic thickening of the duodenal wall and cyst-like changes within the paraduodenal groove (arrow).

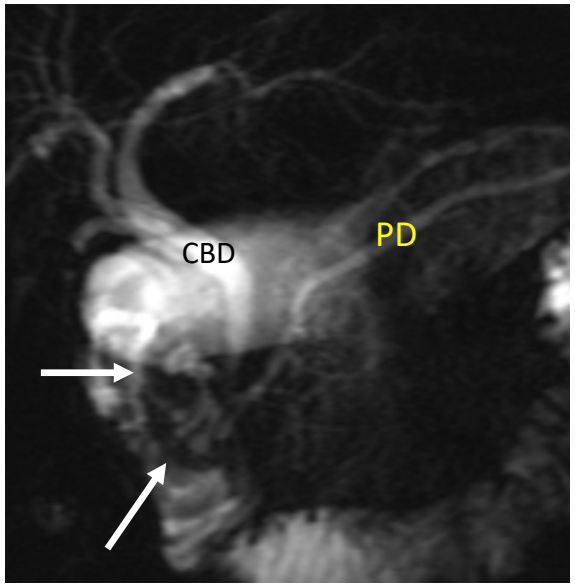

MRCP shows a mass protruding into the duodenal lumen due to thickening of the duodenal wall (arrows). Common bile duct (CBD); Pancreatic Duct (PD).

Chapter Outline

Paraduodenal ("Groove-") Pancreatitis: Imaging Features

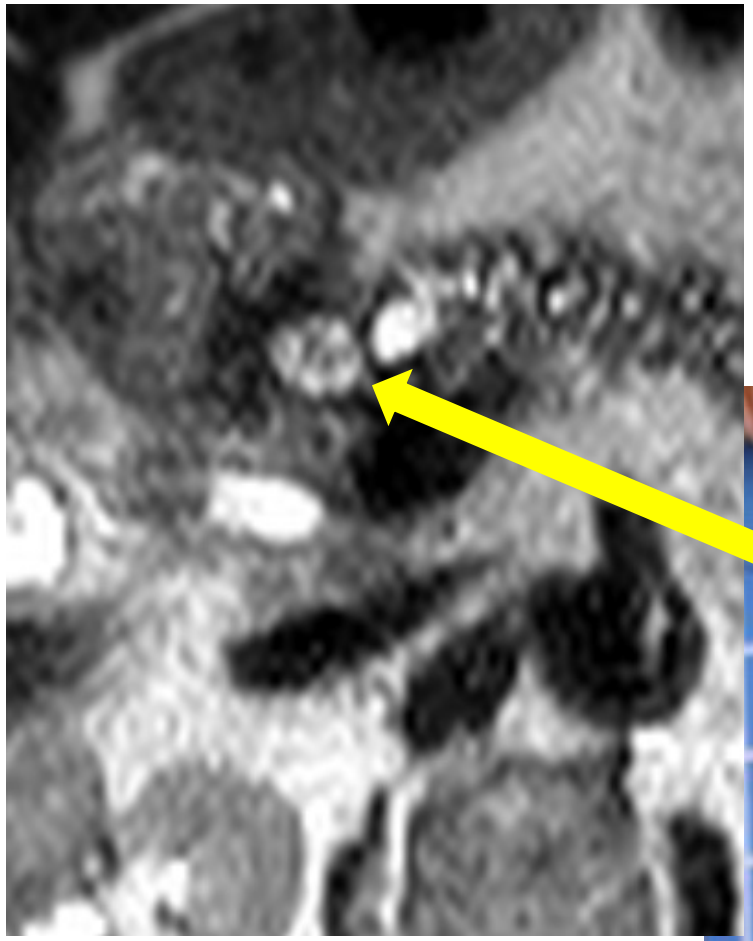

MRI (T2-weighted, transverse image) shows cystic thickening of the duodenal wall (arrow).

Resected specimen confirmed cystic and fibrotic changes due to chronic inflammation within the pancreatico-duodenal groove.

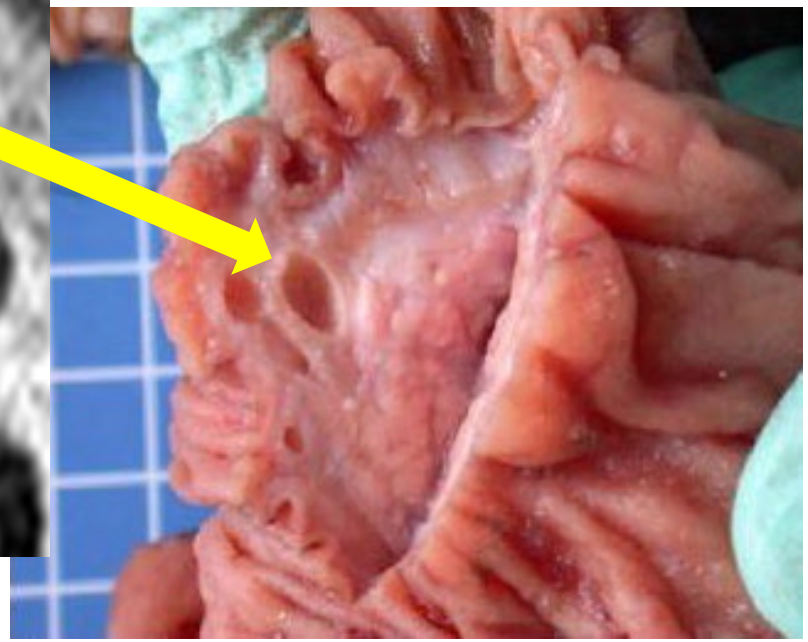

Chapter Outline

Pancreatic Neoplasms

A wide variety of pancreatic neoplasms exists that can be classified

- according to their functional origin as exocrine and endocrine,
- according to their location as intra- or extraductal,
- according to their tissular components as solid or cystic, and
- according to their behaviour as benign or malignant.

Ductal adenocarcinoma, a solid, tumour originating from the exocrine pancreatic tissue is by far the most common tumour and is always malignant, often with a serious prognosis at the time of the diagnosis. It is important, however, to distinguish pancreatic ductal adenocarcinoma from adenocarcinoma of the ampulla of Vater which usually has much more favourable prognosis if completely resected, thus warranting a more aggressive therapeutic approach even in elderly patients.

Pancreatic neuroendocrine neoplasms (PanNENs) are much less common solid tumours originating from the pancreatic islets. They can be functionally active or inactive and can be either benign or malignant.

Cystic tumours of the pancreas have no systemic functional activity. Although serous multicystic tumours are benign, mucinous cystadenoma and intraductal mucinous neoplasms (IPMN) can undergo malignant transformation.

Chapter Outline

Pancreatic Ductal Adenocarcinoma

Typical findings at CT or MRI consist of a solid parenchymal mass with usually less enhancement compared with the surrounding pancreatic tissue. However, contrast behaviour may also sometimes result in an isodense or hyperdense mass. Because a common location is in the pancreatic head, the tumours may compress the common bile duct, leading to painless jaundice. Simultaneous compression of the common bile duct and the main pancreatic duct may be seen on diagnostic imaging studies and has been termed as the "double duct sign".

Imaging has an important role for the staging of pancreatic ductal adenocarcinoma, which is done according to the "Tumour" "Node" "Metastasis" (TNM) classification of the Union for International Cancer Control (UICC) / American Joint Cancer Committee (AJCC). Criteria for primary tumour (T) staging are based on tumour size, extension beyond the organ, and involvement of the adjacent major arteries. Criteria for nodal (N) staging are based on the number of regional lymph nodes that are involved by malignancy. Imaging signs of advanced disease include infiltration of the peripancreatic fat, bile ducts, duodenum, or major pancreatic vessels, enlarged locoregional lymph nodes, and metastases in remote lymph nodes, liver, or other organs. Detection of metastases in remote lymph nodes, liver or other organs (M-staging) can be facilitated by PET/CT.

Pancreatic adenocarcinomas are often unresectable for cure at the time of imaging diagnosis. Depending on the clinical situation, minimally invasive palliative treatment including endoscopic or percutaneous biliary stenting may be favoured in advanced cases over attempts at major curative resection, which carries a high morbidity.

Chapter Outline

Pancreatic Ductal Adenocarcinoma: Imaging Features

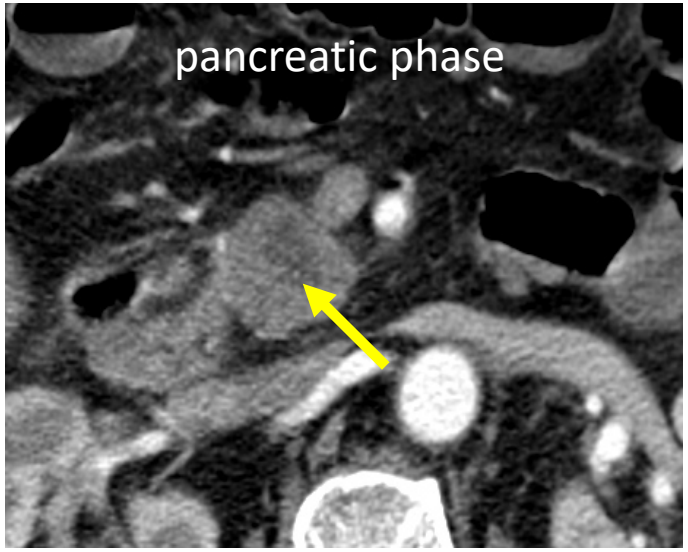

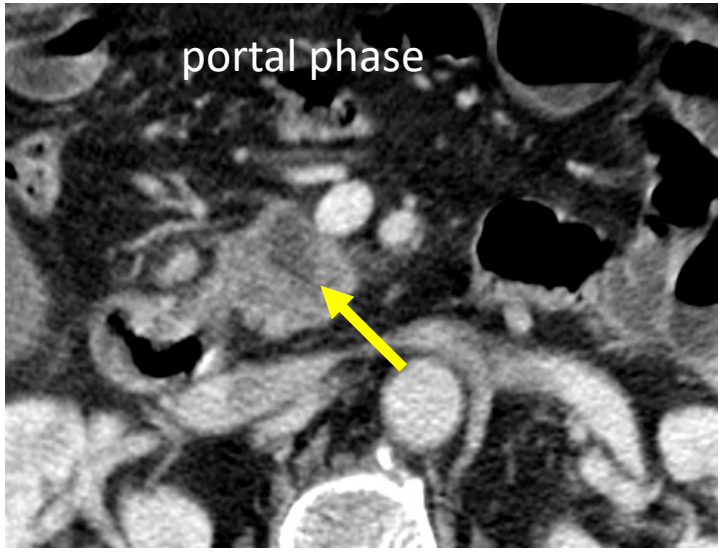

Multiphasic contrast-enhanced CT showing a solid mass in the pancreatic head (arrows), enhancing less than the surrounding pancreatic tissue. The tumour is limited to the pancreatic head.

Pancreatic ductal adenocarcinoma typically enhances less than the surrounding pancreatic tissue!

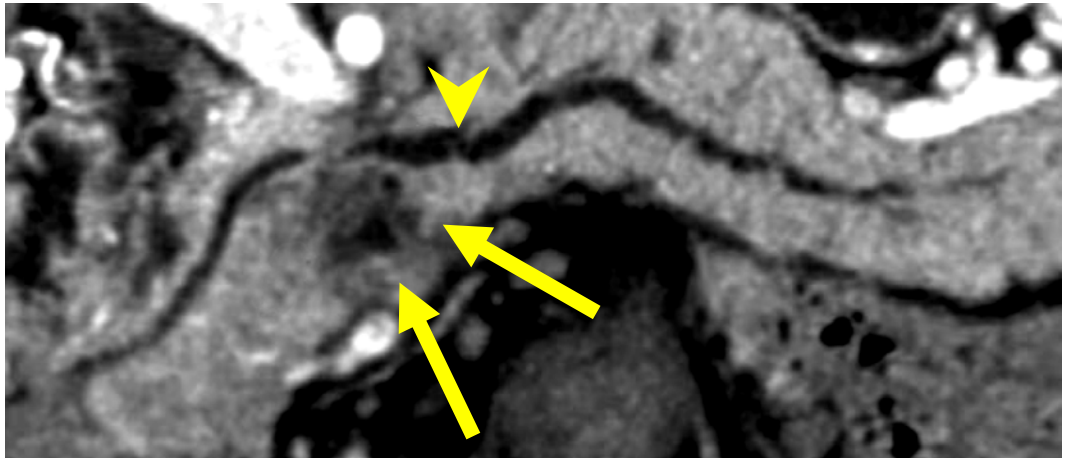

MRI (T1-weighted with Gd-enhancement) showing a solid hypointense mass in the pancreatic body (arrows). Note beginning dilatation of main duct (arrowhead)

Chapter Outline

Pancreatic Ductal Adenocarcinoma: Imaging Features

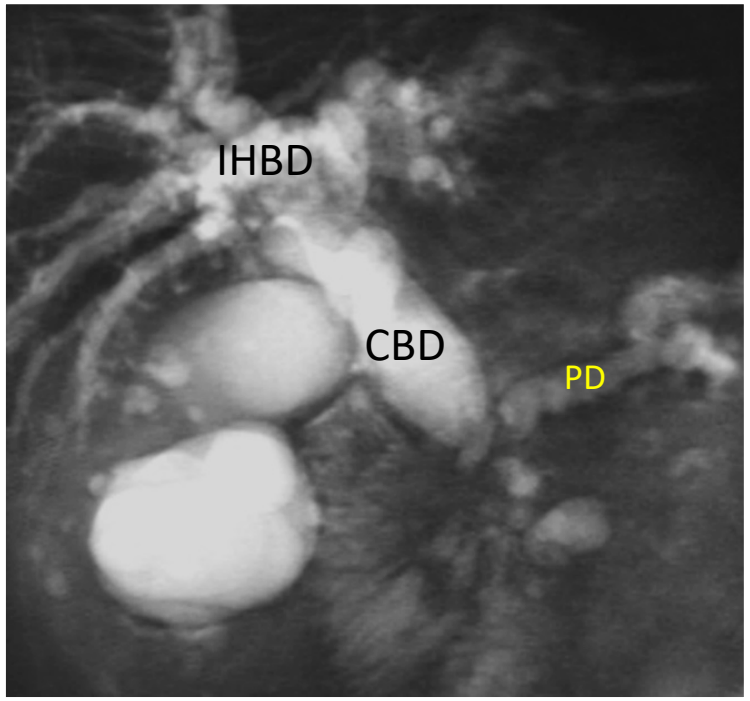

MRCP shows dilated common bile duct (CBD) and main pancreatic duct (PD) In a patient with painless jaundice (= "double duct sign"). Note also dilatation of intrahepatic bile ducts (IHBD)

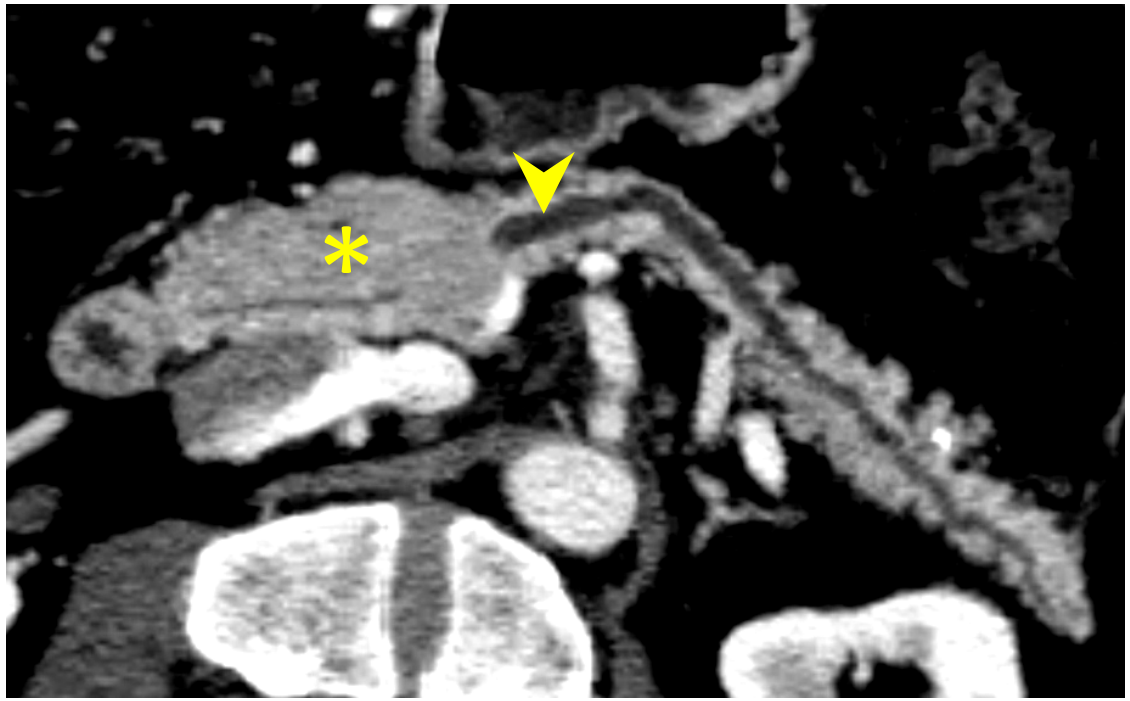

Contrast-enhanced CT (curved reconstruction) shows an isodense solid mass involving the pancreatic head and body (asterisk) and dilatation of the distal main pancreatic duct (arrowhead).

Chapter Outline

Pancreatic Ductal Adenocarcinoma: Imaging Features

Pancreatic ductal adenocarcinoma often shows increased glucose metabolism at PET/CT.

PET/CT is mostly used for the detection of distant metastases (M-staging) rather than for locoregional staging. PET/CT has a limited value for the distinction between tumour and inflammation.

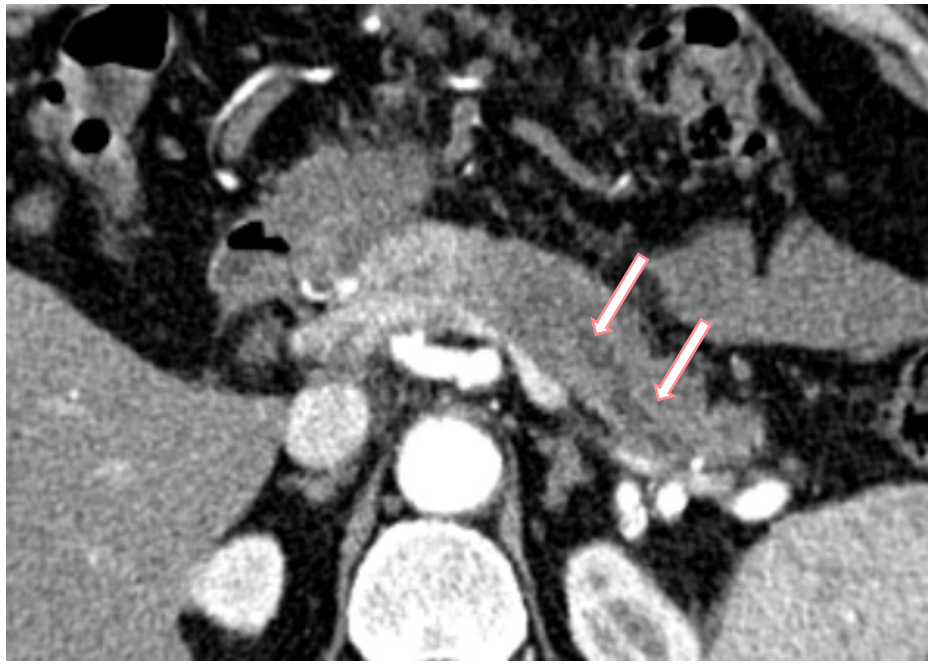

Contrast-enhanced CT (pancreatic phase) shows a hypodense lesion of the left portion of the pancreatic body and dilatation of the distal pancreatic duct (arrows) in a patient with pancreatic adenocarcinoma.

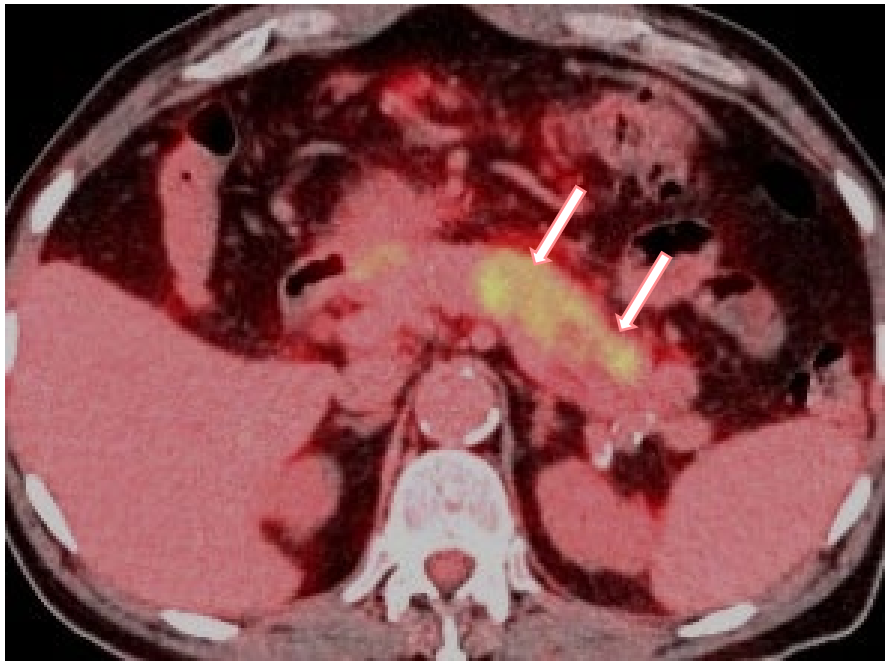

Same patient as in the image on the left. 18-FDG PET/CT shows increased FDG uptake of the left portion of the pancreatic body (arrows).

Chapter Outline

Pancreatic Ductal Adenocarcinoma: Imaging Features

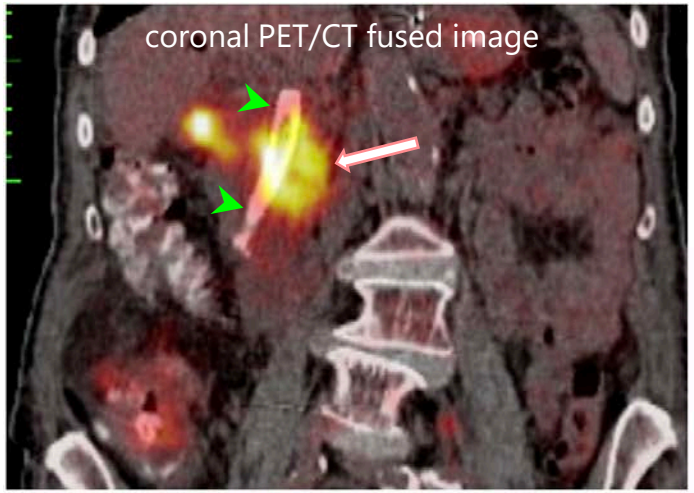

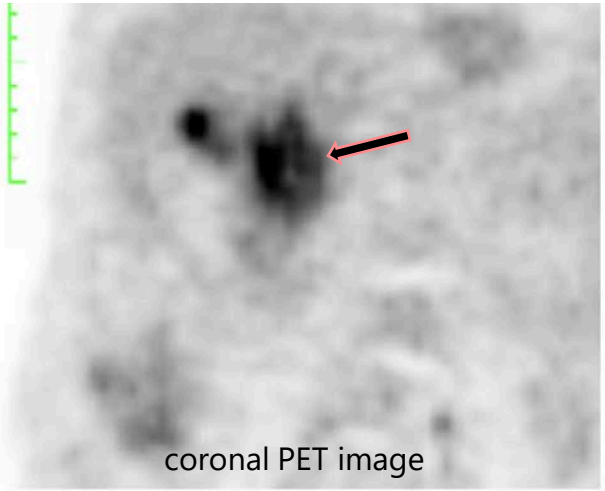

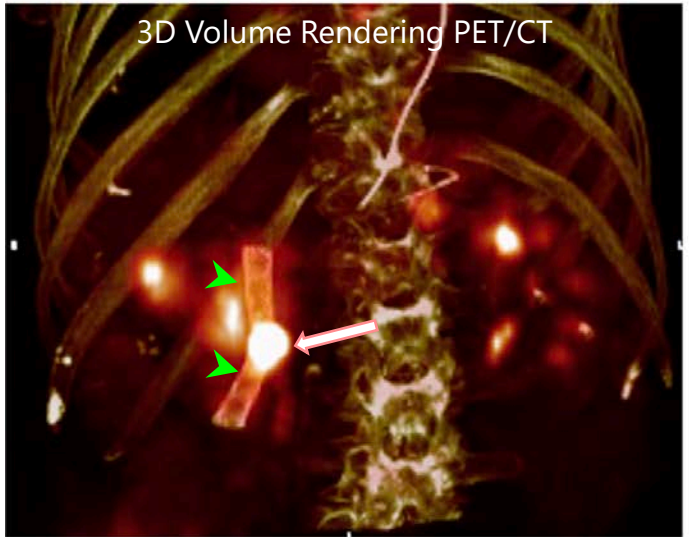

18-FDG PET/CT of advanced pancreatic tumour after palliative placement of biliary metallic endoprosthesis (arrowheads) for obstructive jaundice. Increased glucose metabolism of the tumour (arrows). Note position of the tumour around the biliary endoprosthesis.

Chapter Outline

Staging of Pancreatic Ductal Adenocarcinoma

By showing infiltration of the peripancreatic tissues and organs and of nearby large vessels, cross-sectional imaging provides important information regarding advanced tumour manifestations indicating non-resectability for cure.

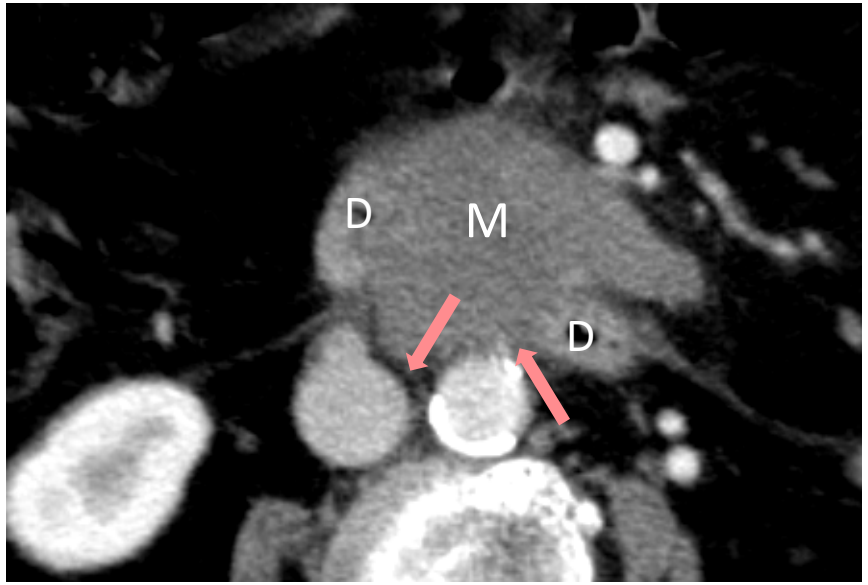

Abdominal CT (pancreatic phase). Large non-enhancing solid mass of the pancreatic head and uncinate process (M), infiltrating the retroperitoneal fatty tissue (arrows) indicating advanced disease (T3). D = duodenum.

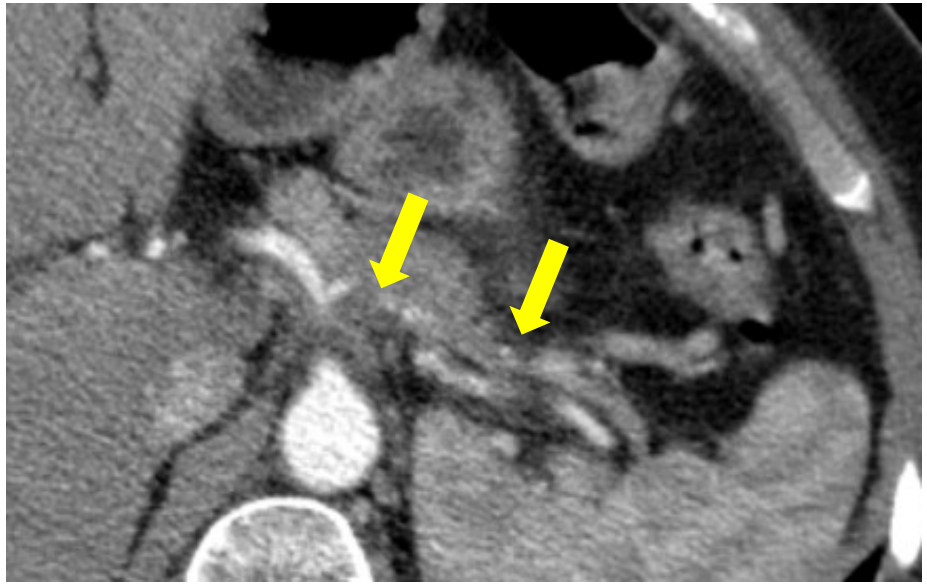

Abdominal CT (arterial phase). The tumor infiltrates the celiac axis and the splenic artery (arrows) indicating advanced disease (T4) and unresectability for cure.

Chapter Outline

Ampullary Adenocarcinoma

Ampullary adenocarcinomas often present at imaging with a double duct sign. Large tumours may protrude into the 2nd part of the duodenum; however, smaller lesions may be entirely occult. Endoscopic biopsy is the method of choice to distinguish between ampullary carcinoma and pancreatic ductal adenocarcinoma.

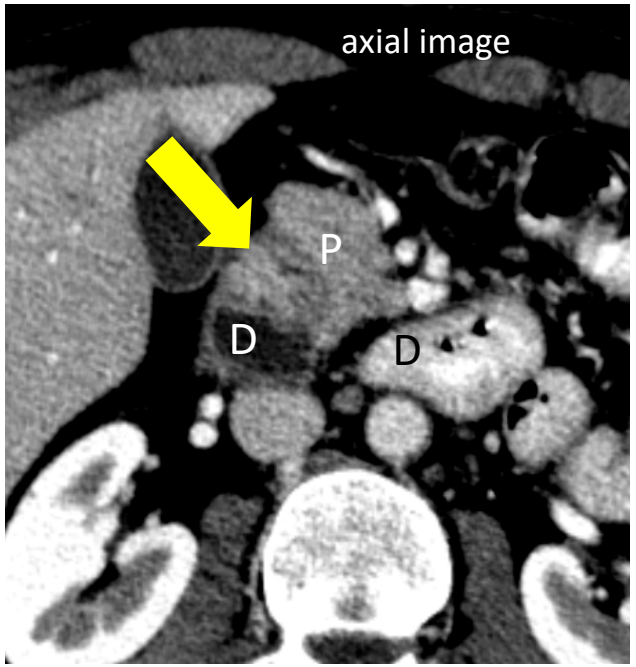

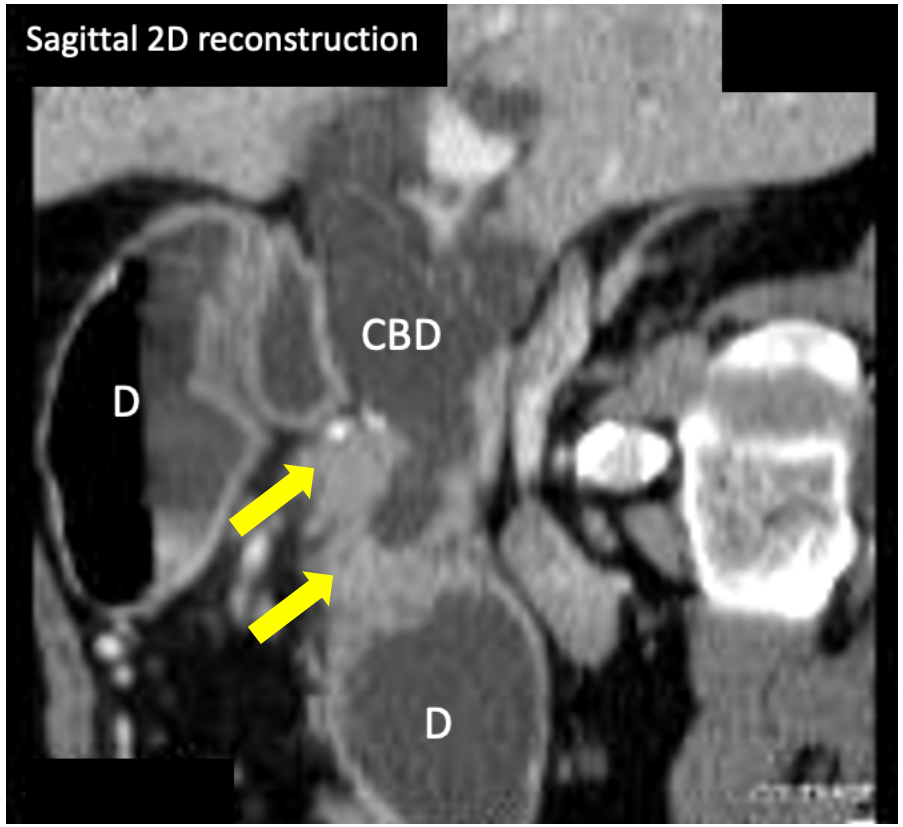

Contrast-enhanced CT shows poorly delineated mass lesion infiltrating the ampulla of Vater and duodenum (arrows). D = duodenum, CDB = common bile duct, P = pancreas

Chapter Outline

Pancreatic Neuroendocrine Neoplasms (panNENs)

Among solid epithelial pancreatic tumours, pancreatic neuroendocrine neoplasms (panNENs) are much less common than ductal adenocarcinoma. The WHO classification distinguishes between well-differentiated variants of neuroendocrine tumours (panNETs), poorly differentiated variants or neuroendocrine carcinomas (panNECs), and mixed neuroendocrine/non-neuroendocrine neoplasms (MiNENs). Well differentiated panNETs may be functionally active, producing clinical symptoms according to their cellular origin and peptide production e.g.,

- Insulinoma => hypoglycemia
- Glucagonoma => glucose intolerance,
- Gastrinoma => Zollinger-Ellison syndrome,
- Vasoactive intestinal peptide tumours (VIPoma) => watery diarrhoea.

Because of their symptoms, these tumours are often diagnosed in an earlier stage than functionally inactive tumours. Although the majority of panNETs is sporadic, around 10% occur in the context of an endocrine syndrome such as multiple endocrine neoplasia (MEN-1), neurofibromatosis or tuberous sclerosis.

On cross-sectional dynamic imaging panNETs typically appear as solid, hypervascular tumours. However, it must be kept in mind that they can also be of cystic appearance and that they can be multiple. Multiphasic contrast-enhanced CT is considered the first choice for imaging although multiphasic MRI is very well suited to detect even very small panNENs. Scintigraphy and 68-Ga DOTATATE–PET may be used to localise small functional panNETs.

Chapter Outline

PanNET: Insulinoma

Most insulinomas are hypervascular!

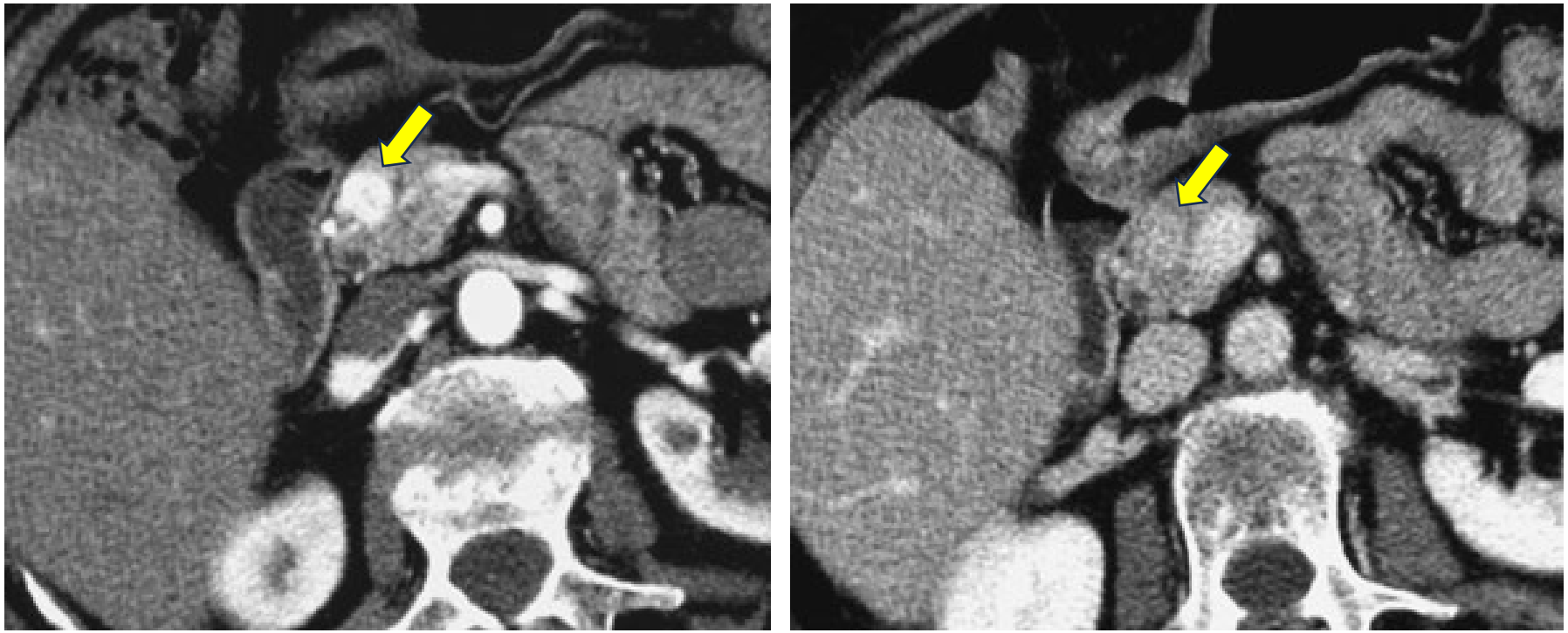

Multiphasic CT (pancreatic phase) shows a rounded, solid strongly enhancing mass in the pancreatic head (arrow). Portal phase shows decreased enhancement of the mass (arrow), so-called "washout phenomenon".

Chapter Outline

Multifocal Insulinoma of the Pancreatic Body and Tail

Insulinomas can be multifocal!
Insulinomas can be cystic!

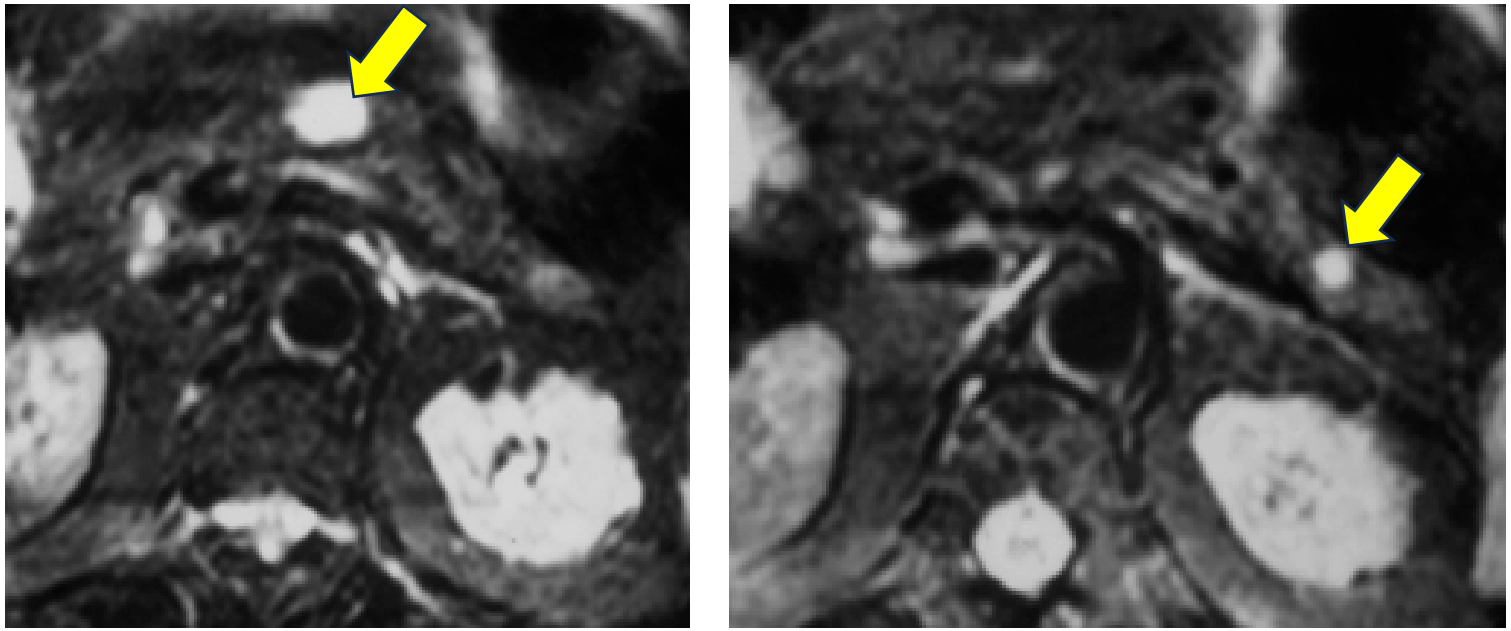

MRI (axial T2-weighted images with fat saturation) shows multiple rounded, hyperintense lesions in the, body and tail of the pancreas (arrows)

Chapter Outline

Cystic Neoplasms of the Pancreas

True cystic pancreatic neoplasms are much less common than pancreatic ductal adenocarcinoma and include a variety of different entities.

Examples for benign lesions are serous microcystic adenomas. Although mucinous cystic neoplasm and the intraductal papillary mucinous neoplasm (IPNM) are also of benign origin, they are potentially malignant as they may undergo transformation into mucinous cystadenocarcinoma.

Because high resolution MRCP is increasingly being used for biliary conditions, ductal cystic lesions are a common unexpected finding and must be distinguished from potentially malignant lesions. Follow-up of ductal cysts >1cm is, therefore, often recommended although guidelines regarding follow-up may differ.

Although some cystic pancreatic neoplasms e.g., serous microcystic adenomas or ductal IPMN have characteristic imaging features, others may be difficult to characterise regarding their aetiology. Follow-up and/or image-guided aspiration biopsy may thus be needed because treatment depends on precise lesion characterisation.

Chapter Outline

Serous Microcystic Adenoma

Serous microcystic adenomas are benign tumours which have a characteristic sponge-like or 'honeycomb' structure with multiple fibrous septa caused by small cysts. The size of individual cysts is usually <10mm in diameter.

Typical cross-sectional imaging features include moderately enhancing septa within a microcystic structure, commonly including calcifications in the central area. Despite their often-considerable size these tumours do not tend to displace or infiltrate the adjacent anatomical structures. e.g., bile ducts or vessels.

Serous adenomas contain a glycogen-rich, non-viscous fluid without mucinous components which can be analysed by means of image-guided fine-needle aspiration.

Chapter Outline

Serous Microcystic Adenoma: CT Features

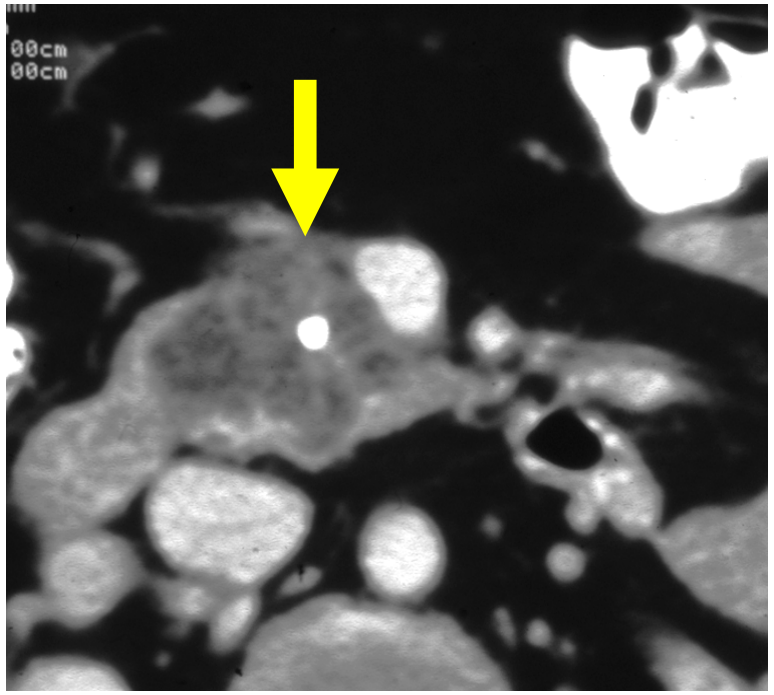

Contrast-enhanced CT (portal phase) showing the typical pattern of serous microcystic adenoma of the pancreatic head with a central calcification (arrow).

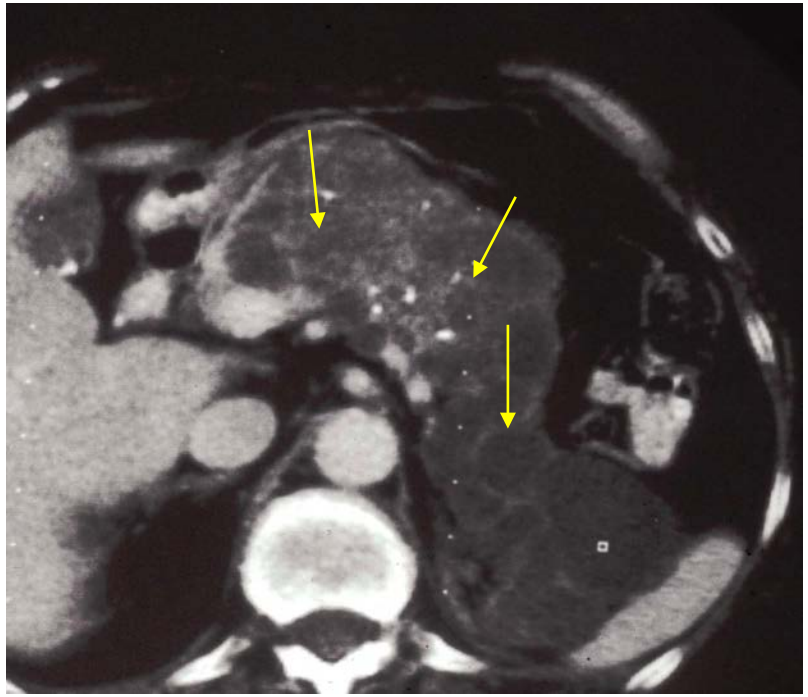

Contrast-enhanced CT (portal phase) showing. large serous microcystic adenoma of the pancreatic corpus and tail. Note multiple septal calcifications (arrows).

Chapter Outline

Serous Microcystic Adenoma: MRI Features

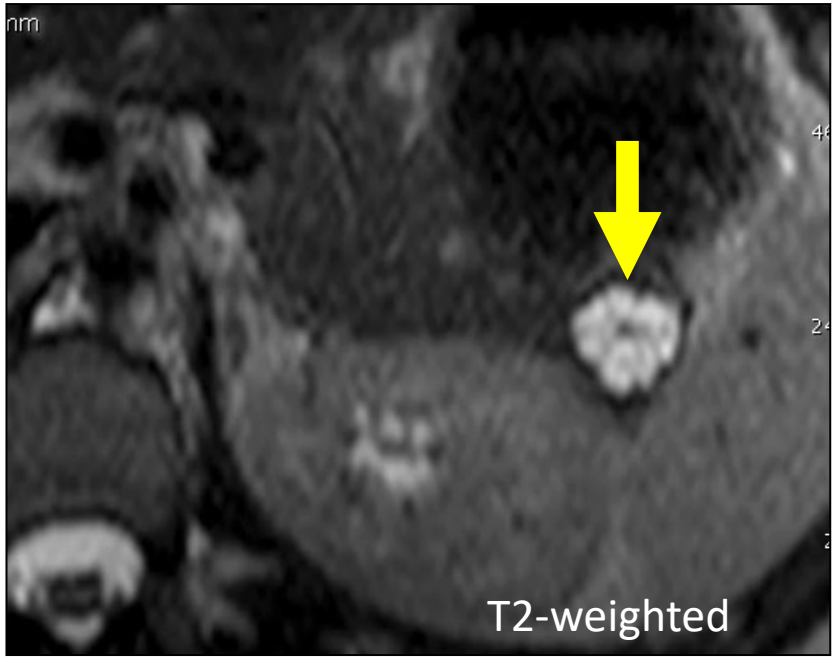

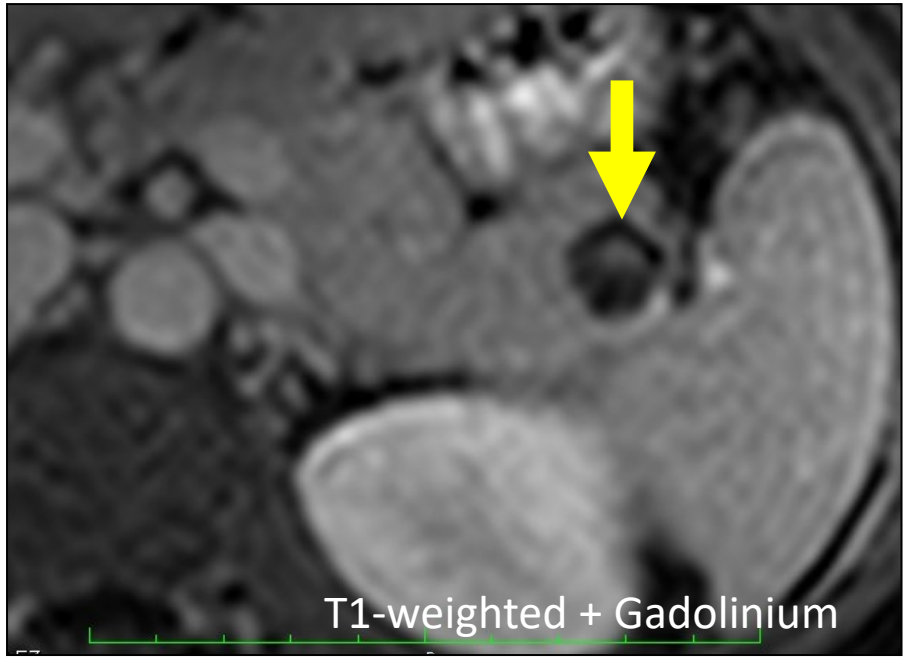

MRI T2-weighted image (left) showing the typical pattern of a microcystic septated lesion in the pancreatic tail. T1-weighted image after injection of a Gd-based contrast material (right) shows a mainly hypovascular lesion with some central enhancement. These MRI features are typical of microcystic adenoma.

Chapter Outline

Mucinous Cystic Neoplasms

Pancreatic mucinous cystadenoma is a benign condition which occurs mainly in women and is characterised by mucin-producing epithelial cells and an ovarian-type stroma. However, it may undergo malignant transformation into carcinoma in situ or invasive mucinous cystadenocarcinoma. Therefore, surgical removal is usually indicated. The prognosis after resection is favourable.

Percutaneous or endoscopically-guided fine-needle aspiration can be used to confirm the nature of these lesions by examining aspirated fluid for carcino-embryonic antigen (CEA), viscosity, mucin content, and cytology.

On cross-sectional imaging, mucinous cysts have typically no communication with the pancreatic ductal system; they are often larger than 2 cm and have an enhancing wall.

A thick irregular wall and intracystic polypoid masses are signs of malignant transformation.

Chapter Outline

Mucinous Cystadenoma: CT Imaging Features

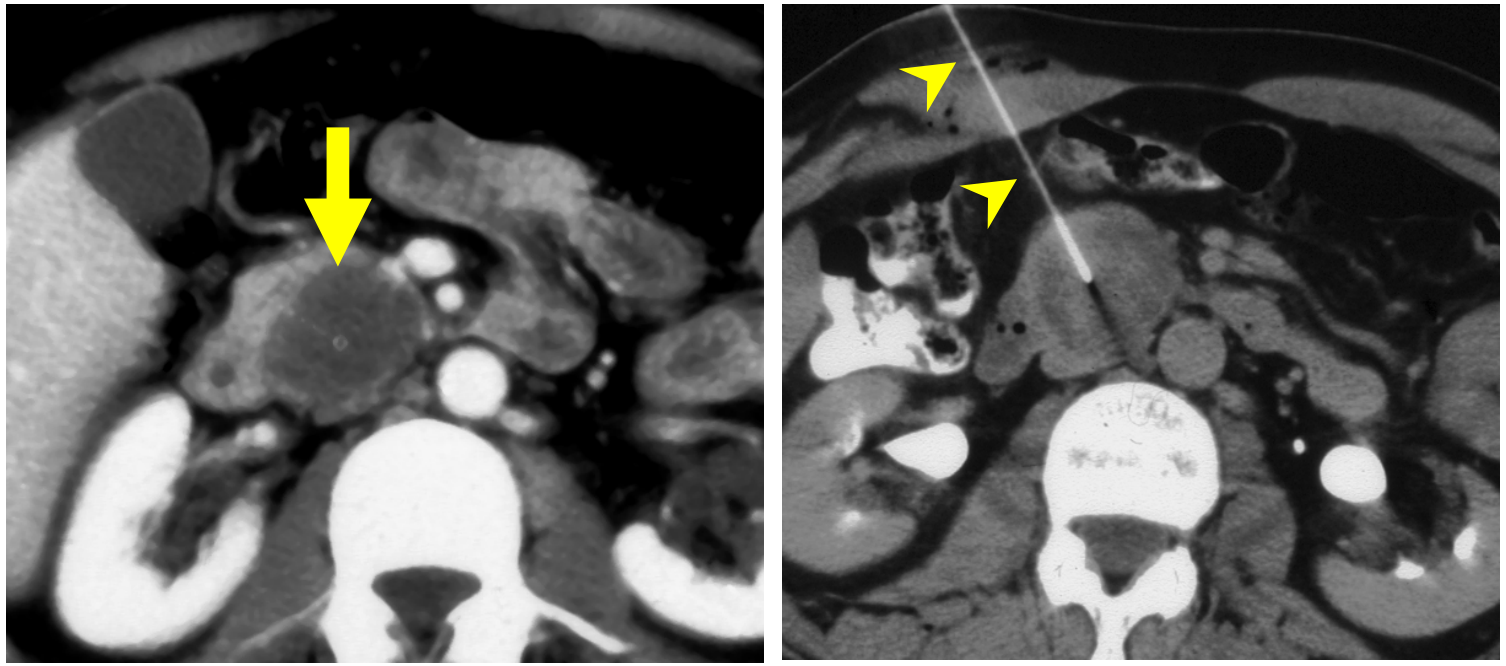

CT (pancreatic phase) showing a large slightly inhomogeneous cystic mass without clear internal structure (arrow, left image). No specific clinical signs of pancreatitis. Result of CT-guided fine-needle aspiration confirmed the diagnosis of mucinous cystadenoma. Arrowheads point at aspiration needle placed under CT guidance (right image).

Chapter Outline

Mucinous Cystadenocarcinoma

Malignant transformation of a mucinous cystadenoma of the pancreas => Note irregular wall thickening!

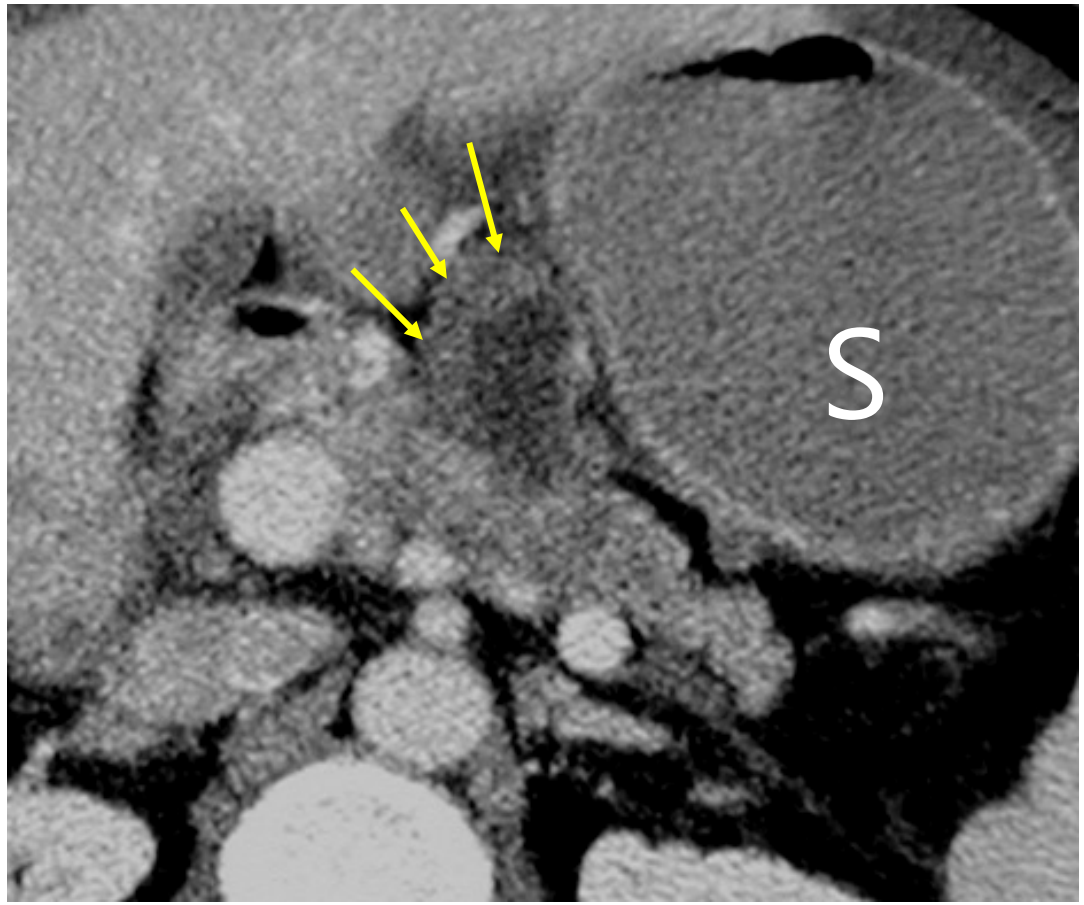

CT (portal phase) showing cystic lesion of the pancreas with inhomogeneous wall thickening (arrows) indicating malignancy. S = stomach

Chapter Outline

Benign Pancreatic Ductal Cyst (Branch Duct Type)

MRI shows a non-enhancing small cystic lesion of 2nd order branch in contact with main duct.

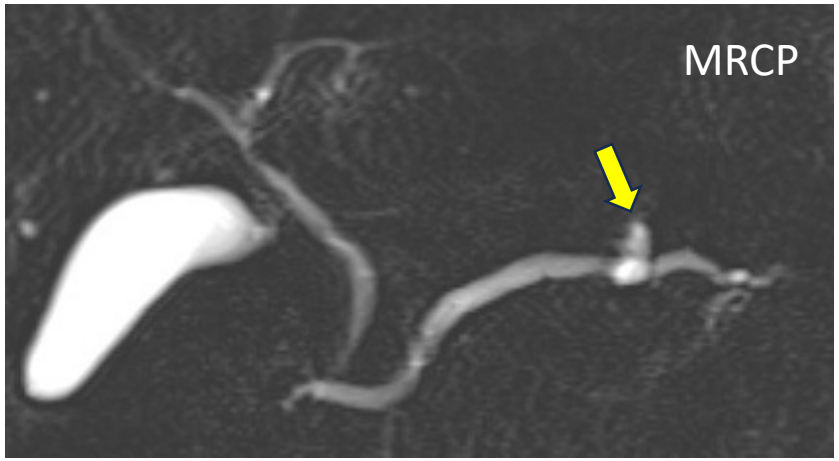

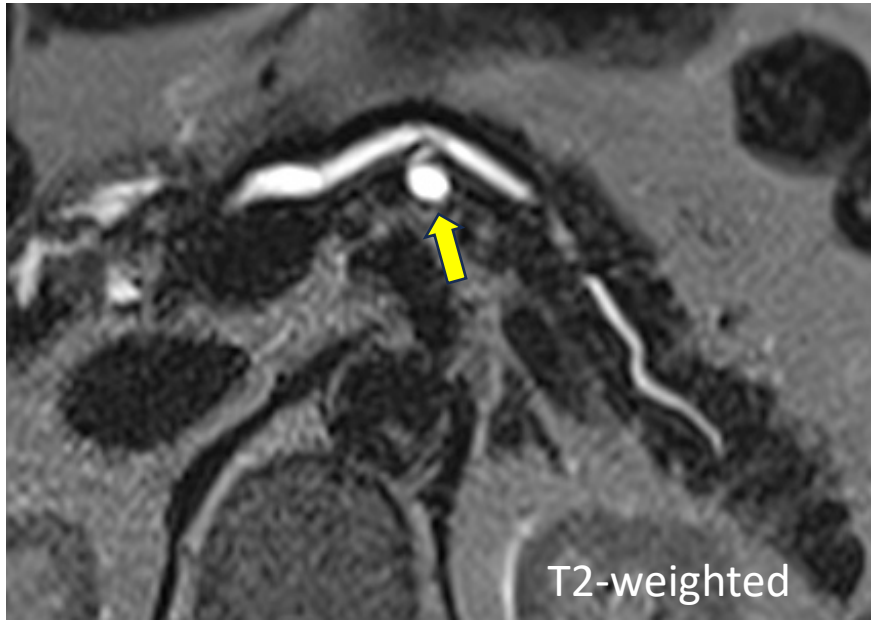

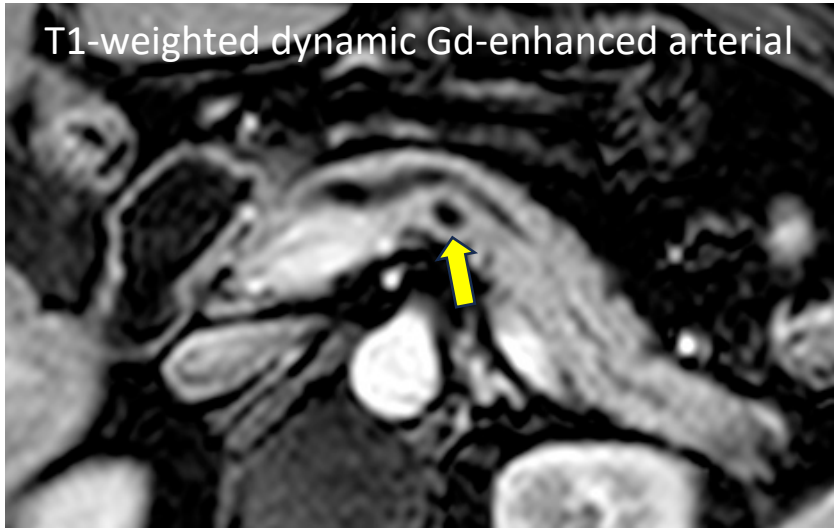

Chapter Outline

Intraductal Papillary Mucinous Neoplasia (IPMN)

Intraductal papillary mucinous neoplasias (IPMN) are caused by papillary proliferation of intraductal dysplastic mucinous cells, leading to ductal dilatation. Based on their macroscopic appearance, they can be divided into main duct type, branch duct type and mixed-type lesions. Histologically, IPMN may undergo transition from cystadenoma to borderline malignant cystic neoplasms and to intraductal papillary mucinous adenocarcinoma with or without invasion of the surrounding tissues.

On cross-sectional imaging studies with CT, MRI, US or EUS, IPMN may appear as single or multiple cystic lesions. Typically, there is communication with the pancreatic ductal system. IPMN may also appear as diffuse or segmental ectasia of the main pancreatic duct or side branches.

Depending on the degree of papillary proliferation, the lesions may have an inhomogeneous internal enhancement and and enhancing wall. Advanced malignancies may show irregularities in the structure of their wall and even invasion of the adjacent tissue.

Chapter Outline

IPMN, Segmental Main Duct Type

In main duct type IPMN (main duct dilatation >5mm), there is segmental pancreatic duct ectasia. Solid enhancing mural ductal nodules are suspicious for malignant transformation.

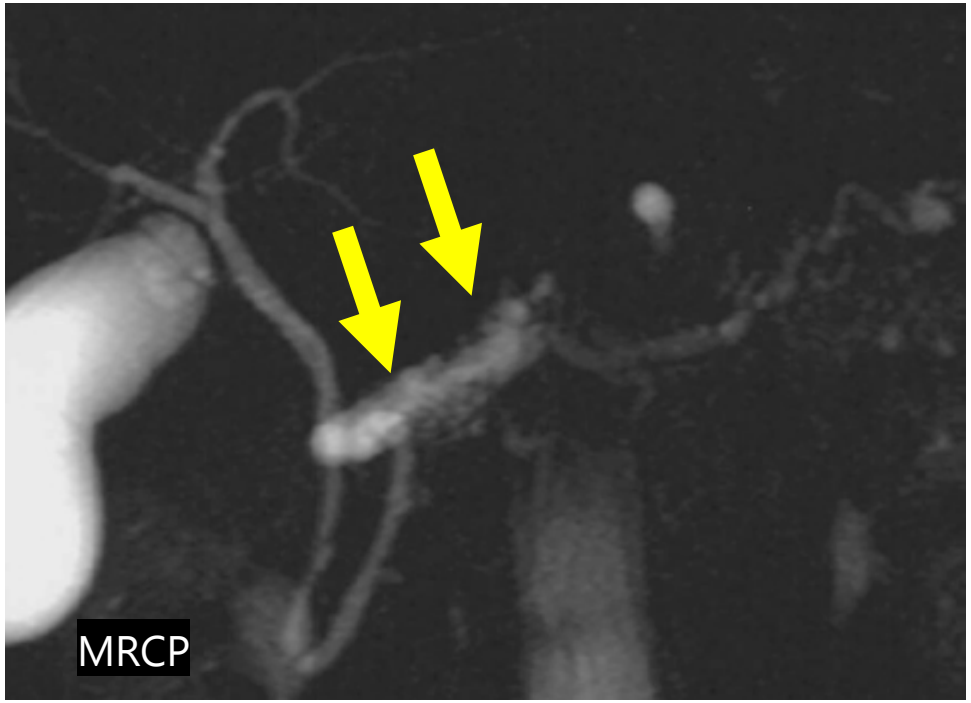

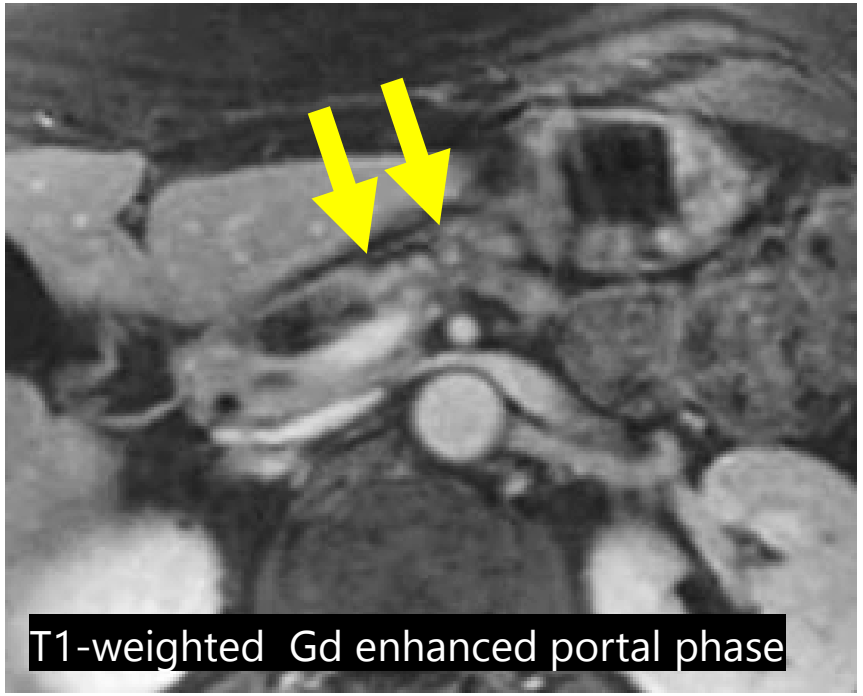

MRI shows segmental ectasia of main pancreatic duct on MRCP and irregular intraductal enhancement after injection of a Gadolinium-based contrast material

Chapter Outline

Cystic Pancreatic Neoplasm with Internal Papillary Proliferation: MRI Features

MRI (different sequences) shows a small rounded, cyst-like mass adjacent to the main pancreatic duct but without proof of ductal communication.
Note papillary-shaped, inhomogeneous enhancing content, with partly solid enhancing wall (arrow).

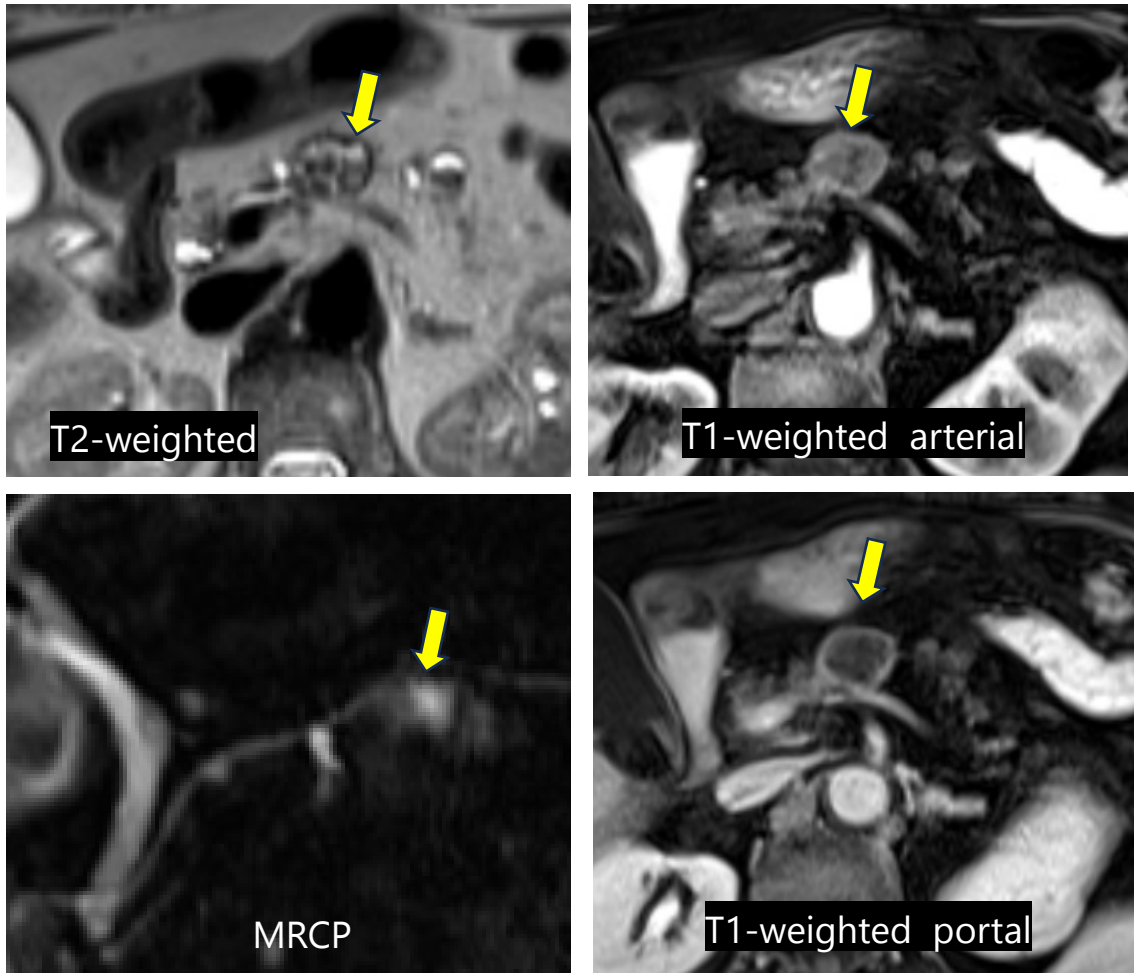

Chapter Outline

Malignant IPMN, Main Duct Type

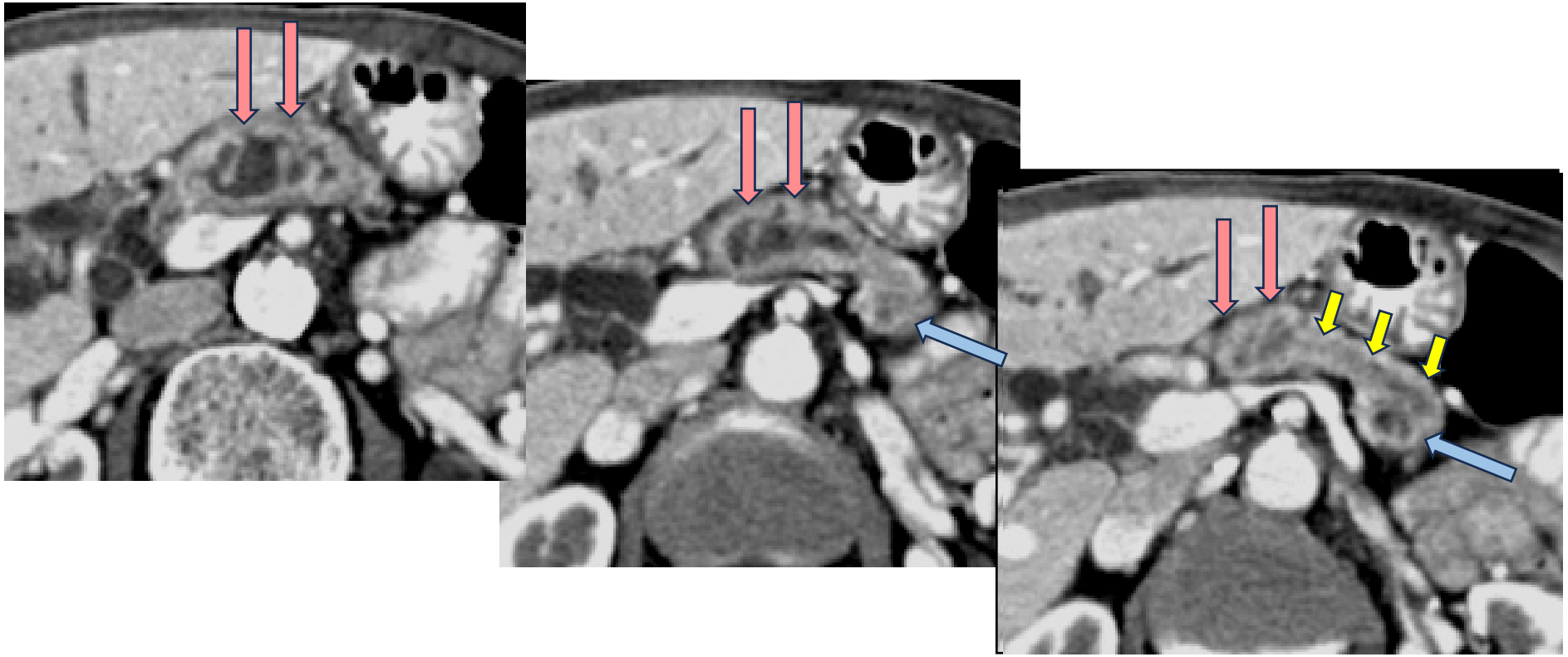

CT (portal phase) showing a lesion (pink arrows) with contact to the main pancreatic duct (yellow arrows). Note irregular internal enhancement of the lesion, thickening of the wall, as well as beginning infiltration of surrounding fatty tissue. Note that there is a second lesion more distally (blue arrow).

Chapter Outline

Cystic Lesions of the Pancreas: Analysis of Aspirated Material

	Amylase	CEA*	Viscosity	Mucin	Cytology
Serous cystadenoma	+/-	-	-	-	glycogen-rich
Mucinous cystadenoma	+/-	+++	++	++	mucinous
Intraductal Papillary Mucinous Neoplasms (IPMN)	++	++	++	+	mucinous
Pseudocyst	+++	-	-	-	(inflammatory)

* Carcino-Embryonic Antigen

Chapter Outline

Splenic Pathologies

A variety of pathologic conditions can affect the spleen. Very often the spleen is the site of secondary manifestations of systemic disorders rather than the site of origin. Splenomegaly is a common feature in haematopoietic diseases (e.g., thrombocytosis, extramedullary haematopoiesis) but splenomegaly also occurs in the context of portal hypertension. Diffuse splenic infiltrative processes can also be the consequence of infectious, granulomatous and metabolic disorders or secondary manifestations of malignancy (e.g., lymphoma, leukaemia, metastatic melanoma).

Primary focal splenic lesions are infrequent and often present without symptoms. A pattern approach to the diagnosis of splenic lesions includes the distinction between single and multiple lesions, between cystic and solid lesions and between hypervascular and hypovascular lesions. Primary cystic lesions of the spleen are often benign (e.g., epithelial, hydatid cysts or lymphangioma). However, solid lesions can be benign (e.g., hamartoma, haemangioma, extramedullary haematopoiesis) or malignant (e.g., lymphoma, metastasis, sarcoma). Because the imaging features may overlap, distinguishing between benign and malignant lesions on the basis of imaging alone can be very challenging.

From a differential diagnostic point of view, it is important to mention splenunculus (accessory spleen) because it can be mistaken for a neoplastic mass.

Finally, traumatic splenic injuries are common in the context of severe blunt abdominal trauma, and imaging plays a crucial role in conservative management.

Chapter Outline

Splenomegaly

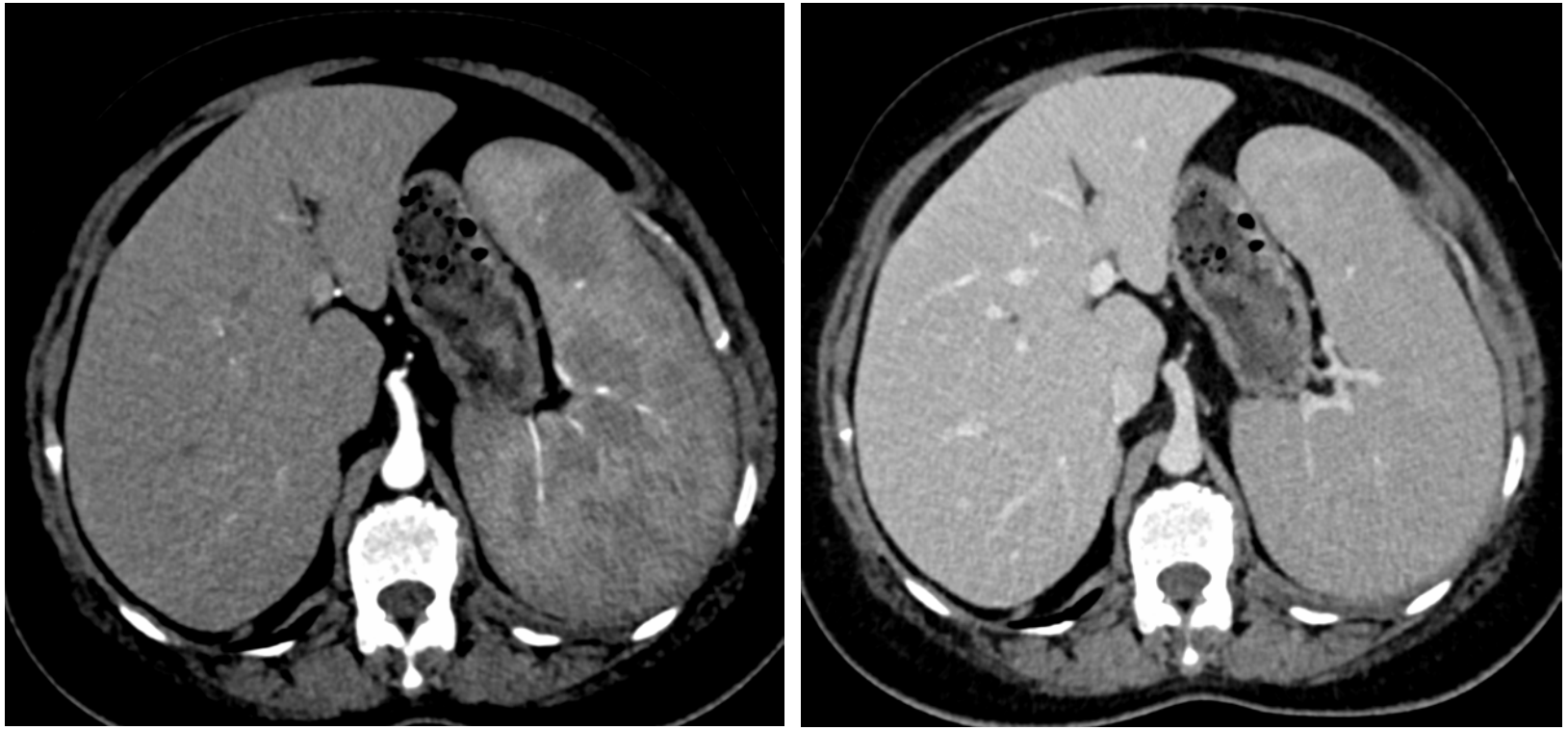

Multiphasic contrast enhanced CT (arterial phase on the left, portal venous phase on the right) show splenomegaly in a patient with acute myeloid leukaemia. Compare with images on page 8 showing a normal sized-spleen.

Chapter Outline

Focal Benign Splenic Lesions

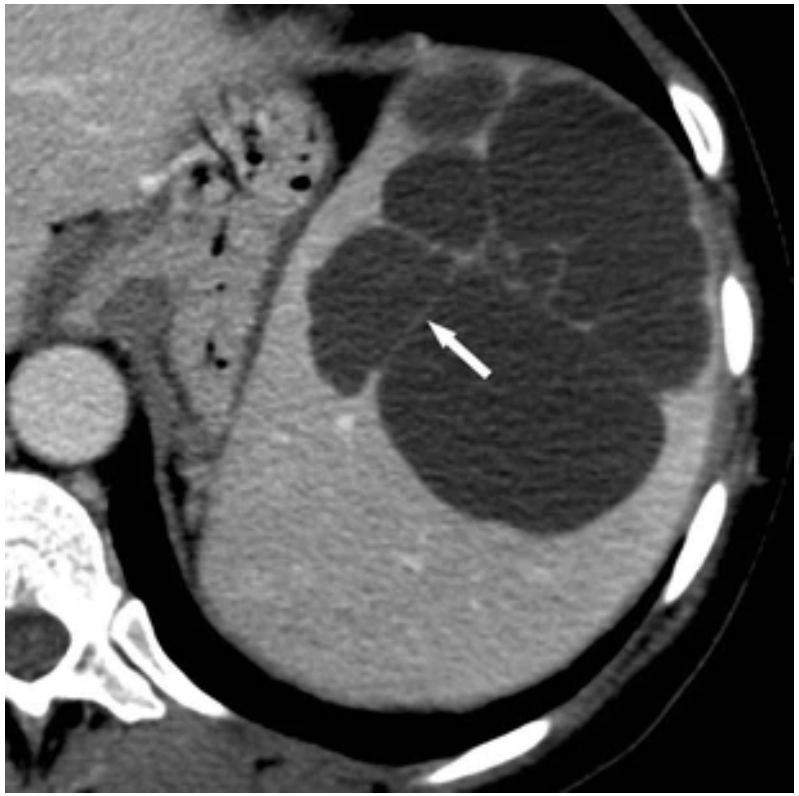

Lymphangioma: CT (portal venous phase) showing a hypodense cystic mass lesion of the spleen with thin septa (arrow).

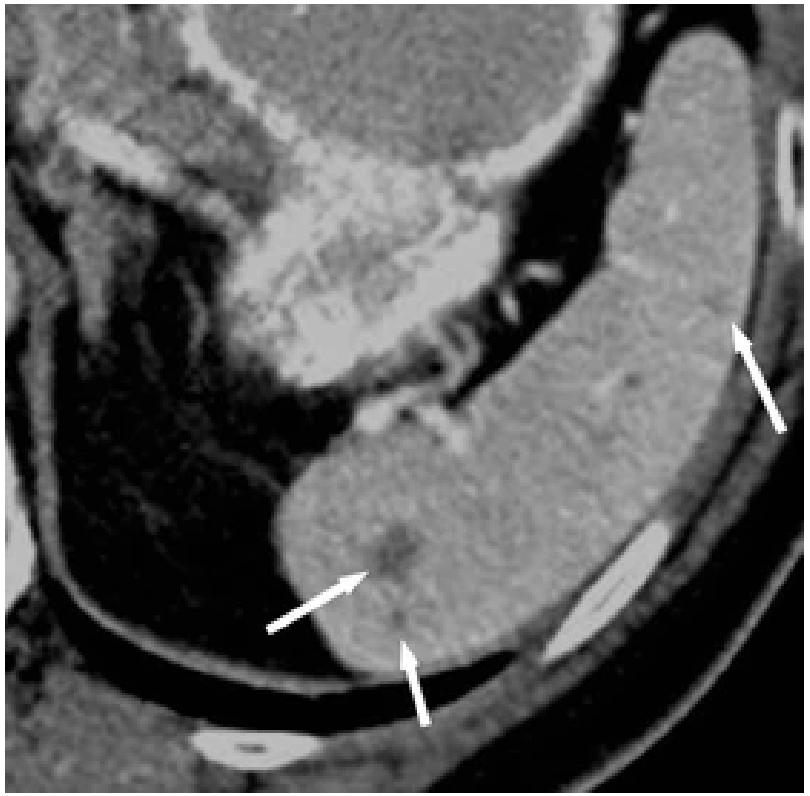

Sarcoidosis: CT (portal venous phase) showing multiple solid hypodense mass lesions of the spleen (arrows).

Images from: Karlo CA, Stolzmann P, Do RK, Alkadhi H. Computed tomography of the spleen: how to interpret the hypodense lesion. Insights Imaging (2013) 4:65–76

Chapter Outline

Focal Malignant Splenic Lesions

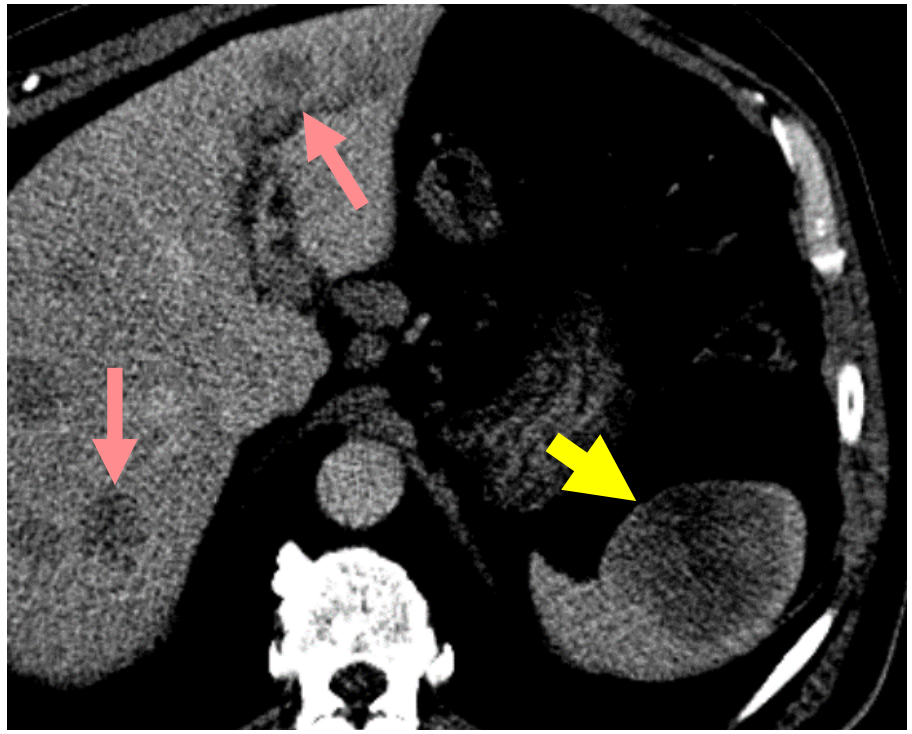

CT (portal venous phase) showing a hypodense solid mass lesion of the spleen (yellow arrow) in the context of sytemic malignant lymphoma. Note two additional nodules in the liver (pink arrows).

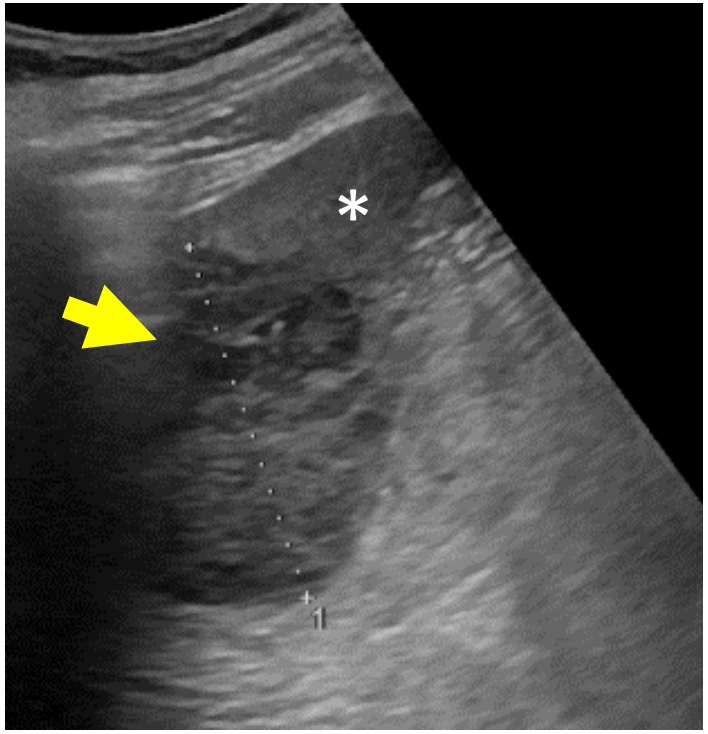

US showing the spleenic tumour (arrow). The tumour is solid and hypoechoic compared to normal splenic parenchyma (asterisk). Histologic diagnosis was spleen lymphoma.

Images courtesy: Oskar Bożek, MD, Department of Radiodiagnostics and Invasive Radiology, Faculty of Medical Sciences in Katowice, Medical University of Silesia.

Chapter Outline

Blunt Trauma: Pancreatic Injuries

Blunt pancreatic injuries usually occur in the context of severe deceleration through direct impact or a shearing mechanism against the spine and are much less common than blunt splenic injuries. According to the organ injury scale of the American Association for Surgery of Trauma (AAST) the severity of blunt pancreatic injuries ranges from contusion or laceration without ductal injury or tissue loss to complete transection including ductal rupture distally (= left of the SMV) complete proximal transection with ductal rupture proximally (= to the right of the SMV) and to massive disruption of the pancreatic head. Leakage of pancreatic juice may lead to posttraumatic acute pancreatitis.

CT is usually the first-line examination and well-suited for follow-up. However, the severity of blunt pancreatic injuries is often difficult to assess at the time of initial examination because morphologic changes in the form of acute posttraumatic pancreatitis develop only after hours or even days after trauma.

Follow-up imaging in the posttraumatic phase plays an important role conservative treatment monitoring. Potential complications are due to acute pancreatitis following ductal injuries and include pseudocysts, arterial pseudoaneurysms, haemorrhage, and infection.

MRCP is the method of choice for non-invasive assessment of posttraumatic ductal Injuries.

Chapter Outline

Blunt Pancreatic Injuries: Proximal Transection

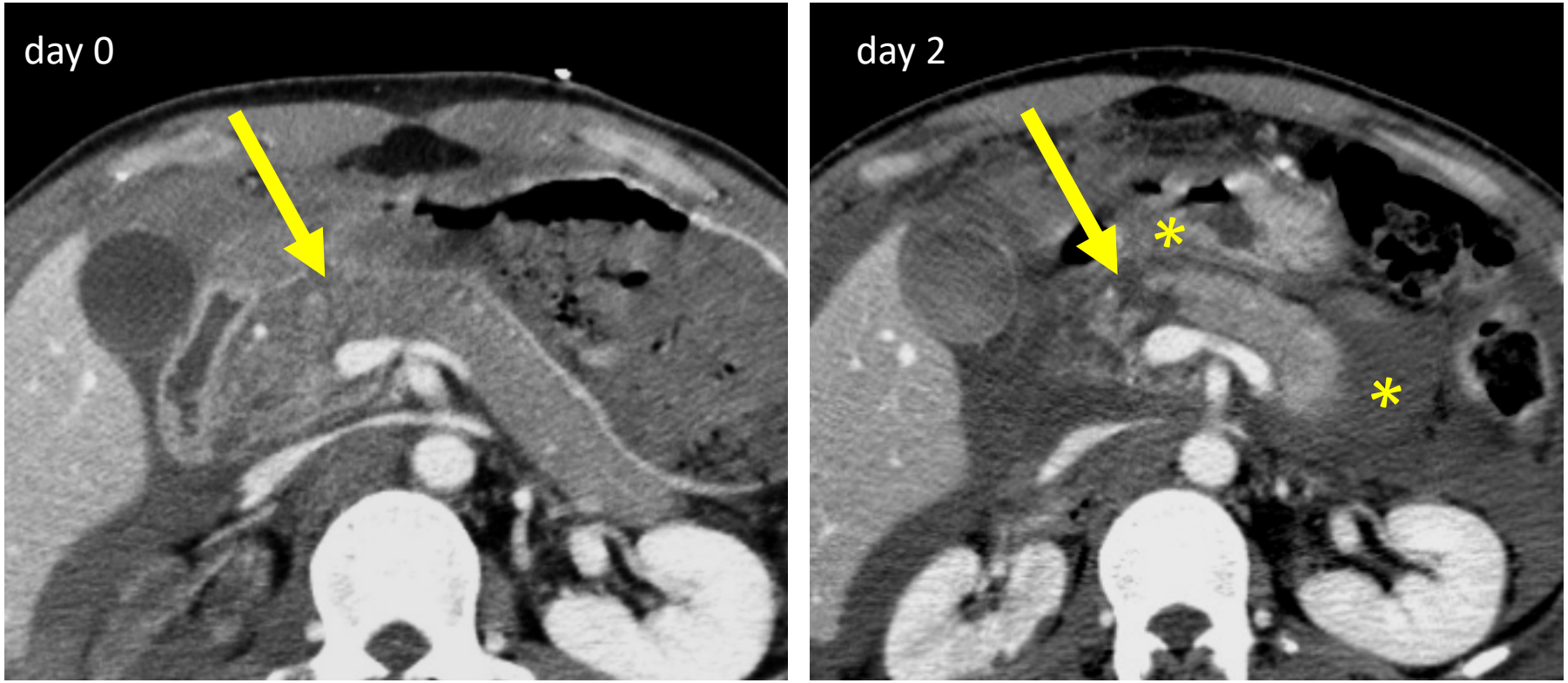

Importance of follow-up scanning in suspected pancreatic injury. CT obtained immediately after blunt abdominal trauma (day 0, left) shows diffuse swelling in the region of the pancreatic neck (arrow). CT after 48 hr (right) shows a devascularised portion of the pancreatic neck (arrow) indicating transection, as well as a peripancreatic fluid collection (asterisks), indicating the development of posttraumatic pancreatitis .

Chapter Outline

Blunt Pancreatic Injuries: Distal Transection

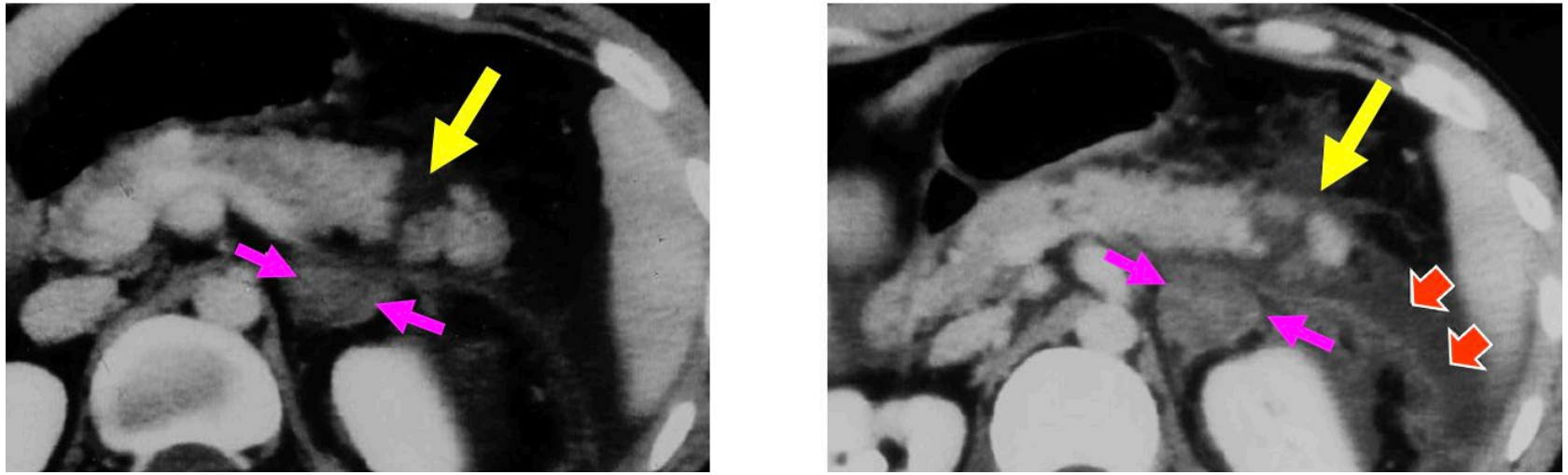

CT obtained immediately after blunt abdominal trauma (day 0, left) shows distal transection of the pancreas (yellow arrow). CT after 48 hr (right) shows the transection (yellow arrow) but also a fluid collection in the retroperitoneum (open red arrows) due to developing posttraumatic pancreatitis. Note swelling of left adrenal gland due to contusion (small pink arrows)

Becker CD, Mentha G, Schmidlin F, Terrier F. Blunt abdominal trauma in adults: role of CT in the diagnosis and management of visceral injuries Part 2: Gastrointestinal tract and retroperitoneal organs. Eur. Radiol. 8, 772- 780 (1998)

Chapter Outline

Blunt Pancreatic Injuries

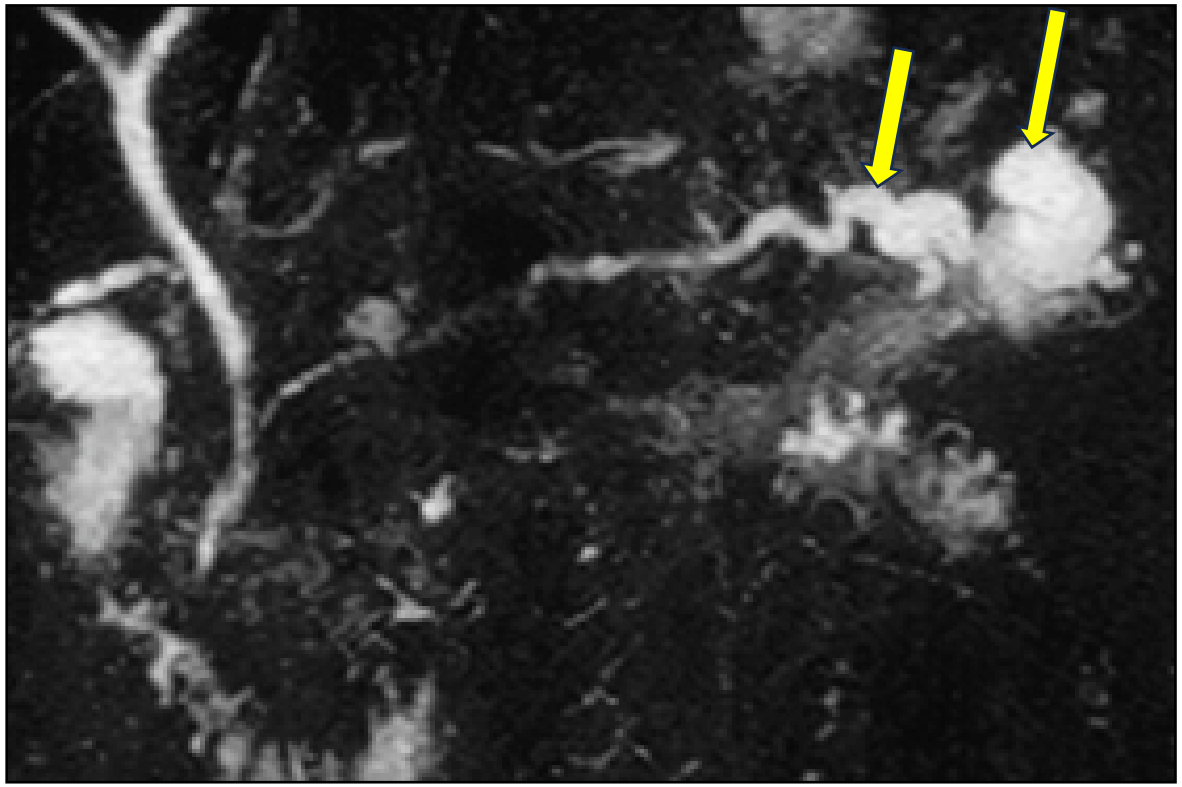

MRCP shows ductectasia and ductal leakage in the pancreatic tail (arrows) in a patient with posttraumatic acute pancreatitis.

Chapter Outline

Blunt Trauma: Splenic Injuries

The spleen is the most common site of organ injuries in severe blunt abdominal trauma. Focussed assessment with sonography in trauma (FAST) is the first-line imaging technique well suited to detect haemoperitoneum that may warrant surgery in haemodynamically unstable patients and may also detect major splenic injuries at the time of admission. Contrast enhanced CT offers a more complete overview of traumatic injuries and is the method of choice for the detection and grading of visceral injuries. However, it is usually not indicated in haemodynamically unstable patients except in a dedicated trauma care environment.

In haemodynamically stable patients, blunt splenic trauma is managed with conservative expectation whenever possible, the success rate being high in adults and even higher in children.

CT findings of blunt splenic injuries are classified using the organ injury scale of the of the World Society of Emergency Surgery and the American Association for Surgery of Trauma (AAST). Grading is mainly based on the size and extent of subcapsular haematoma and parenchymal laceration and signs of vascular injury (devascularisation). CT also plays an important role for the follow–up during conservative treatment of splenic injuries as it may detect delayed complications of splenic injuries such as expanding subcapsular haematoma, formation of pseudoaneurysms or continuous haemorrhage.

Intraarterial embolisation is a minimally invasive interventional radiologic method to provide haemostasis in delayed bleeding or to treat posttraumatic pseudoaneurysms.

Chapter Outline

Blunt Splenic Injuries

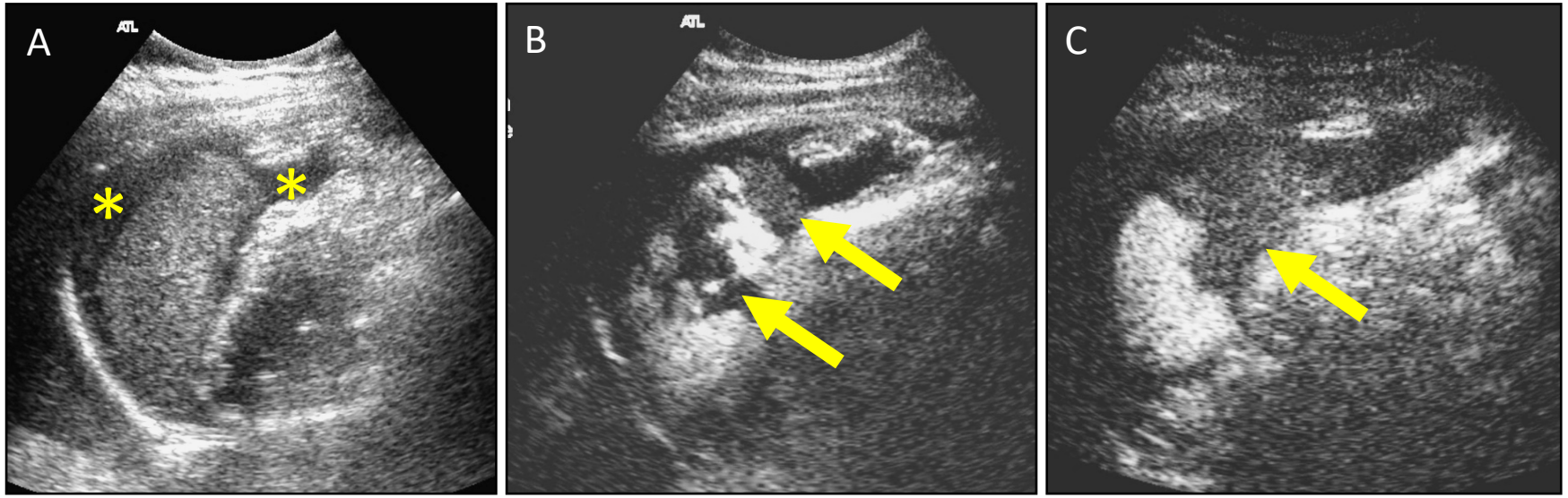

US after blunt abdominal trauma. US without iv. contrast material (A) shows haemoperitoneum (asterisk), but no parenhymal lesion. B (early phase contrast-enhanced US) and C (late phase contrast-enhanced CT) show hypoperfused areas (arrows) suggesting splenic laceration with devascularised areas.

Images courtesy of Alexandra Platon, MD, Geneva University Hospitals, Geneva, Switzerland

Chapter Outline

Posttraumatic Splenic Haematoma and Active Bleeding

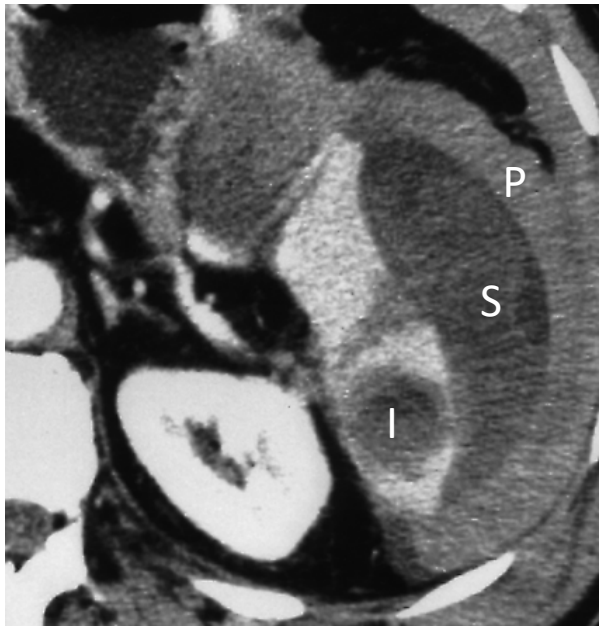

CT showing posttraumatic subcapsular (S), intraparenchymal (I) and perisplenic (P) haematoma. This patient was successfully treated conservatively.

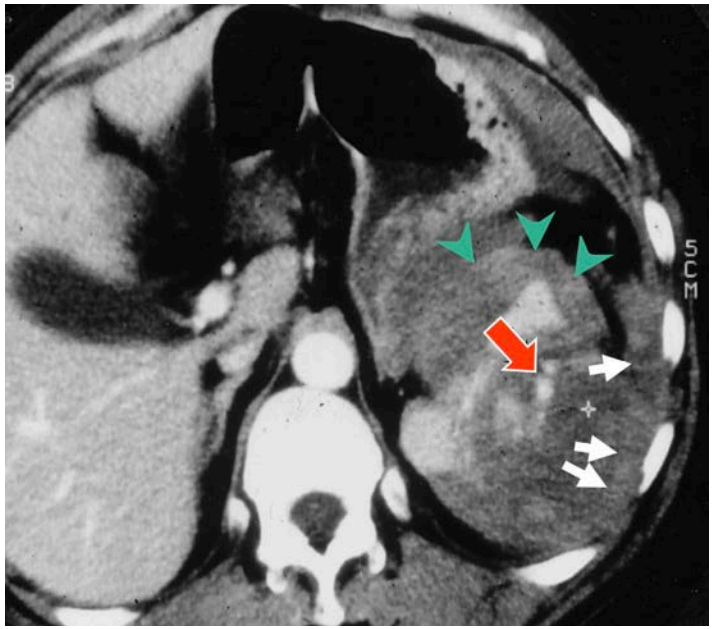

CT showing a shattered spleen requiring immediate splenectomy. Contrast-enhanced CT shows major devascularisation of splenic parenchyma with extravasation of contrast material (red arrow). Note subcapsular haematoma (green arrowheads) and free perisplenic blood (white arrows).

Chapter Outline

Blunt Splenic Injuries: Selective Arteriogram Before Minimally Invasive Treatment of Ruptured Posttraumatic Pseudoaneurysm

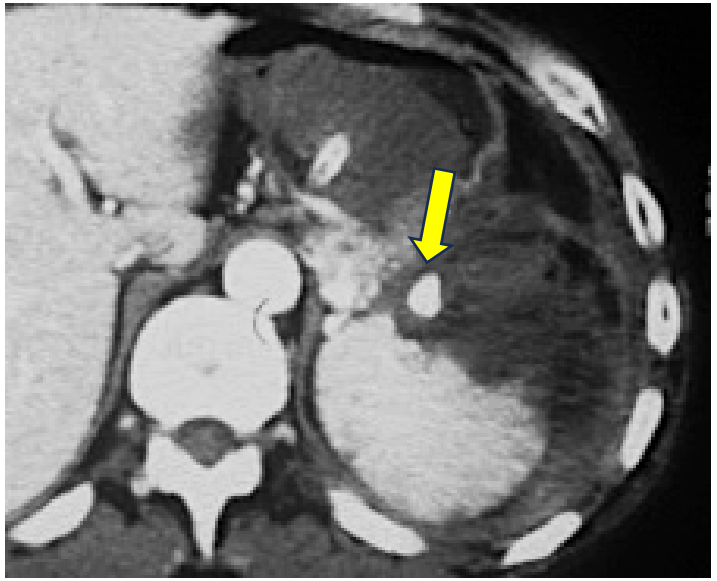

CT shows pseudonaeurym (arrow)

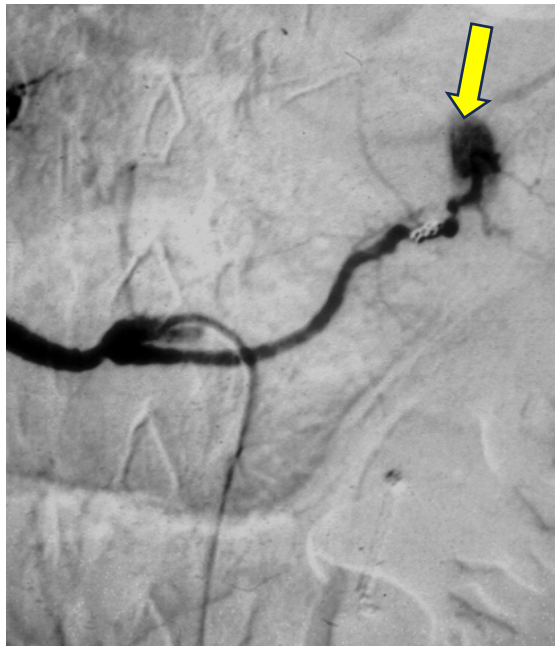

DSA of celiac axis shows pseudonaeurym (arrow).

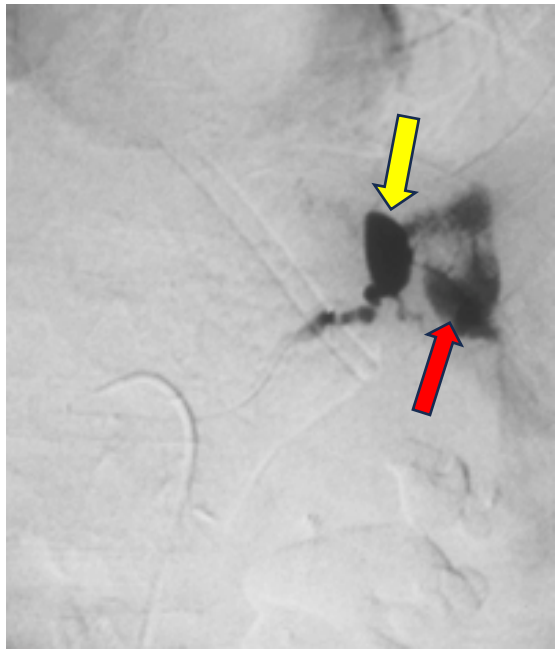

Selective DSA of peripheral splenic artery branch showing pseudonaeurym (yellow arrow) and extravastion indicating active haemorrhage (arrow).

Chapter Outline

Interventional Radiologic Treatment



Absorbable gelatine sponge



Microparticles

Microcatheter

Metallic coils

The interventional radiologist performing an embolisation procedure for acute haemorrhage. The left image shows the technical environment of the interventional radiology suite. The four images on the right illustrate the endovascular devices that are typically used for endoarterial occlusion of bleeding sources by means of a co-axial microcatheter, namely, absorbable gelatine sponge, polyvinyl alcohol microparticles or metallic coils.

Chapter Outline

Posttraumatic Splenic Vascular Complications and Interventional Radiologic Treatment

Depending on morphology and location, posttraumatic aneurysm of the spleen artery and its branches can be treated by micro-coils inserted for packing or excluded from arterial flow by using an expandable endovascular covered stent graft.

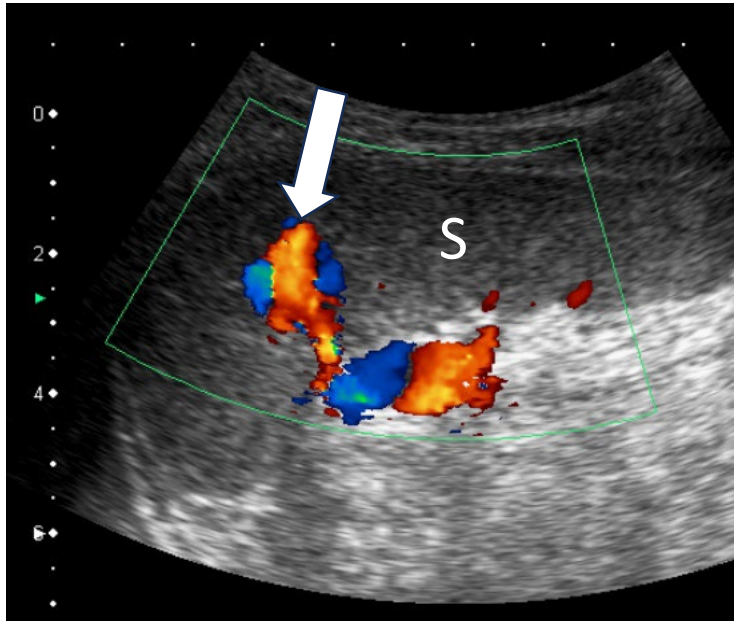

Colour Doppler- US shows posttaumatic intraparenchymal pseudoaneurysm of the spleen (arrow) S = spleen

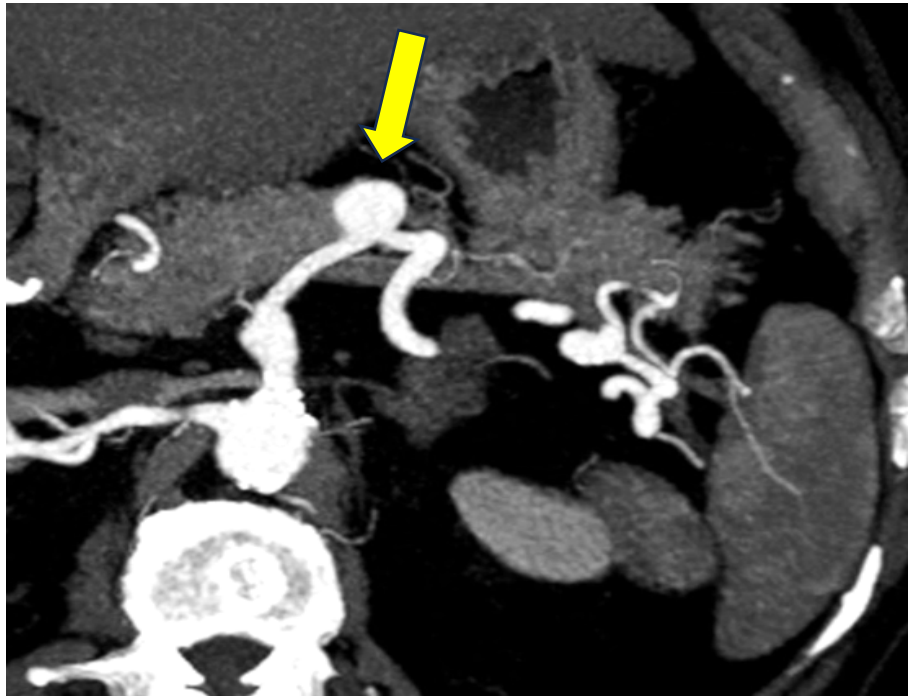

CT (arterial phase, MIP reconstruction) shows posttraumatic pseudoaneurysm of the main splenic artery (arrow).

Chapter Outline

Blunt Splenic Injuries: Transarterial Embolisation of Pseudoaneurysm Complicating Conservative Treatment

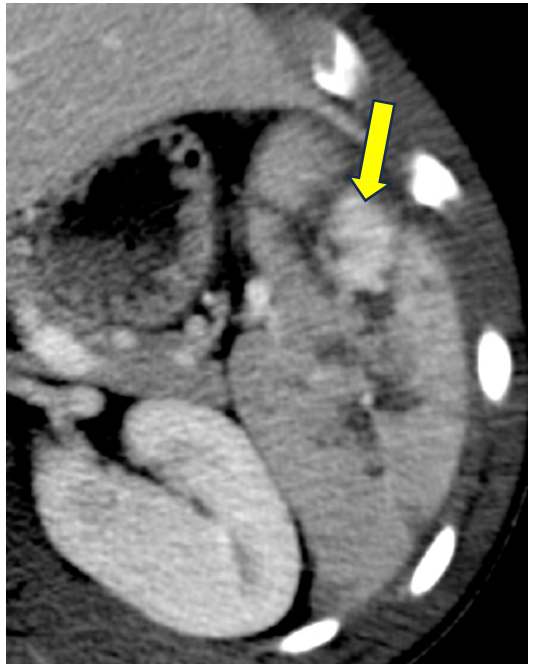

Contrast-enhanced CT (arterial phase). Postraumatic multiple intraparenchymal fractures and intraparenchymal haemorrhage (arrow).

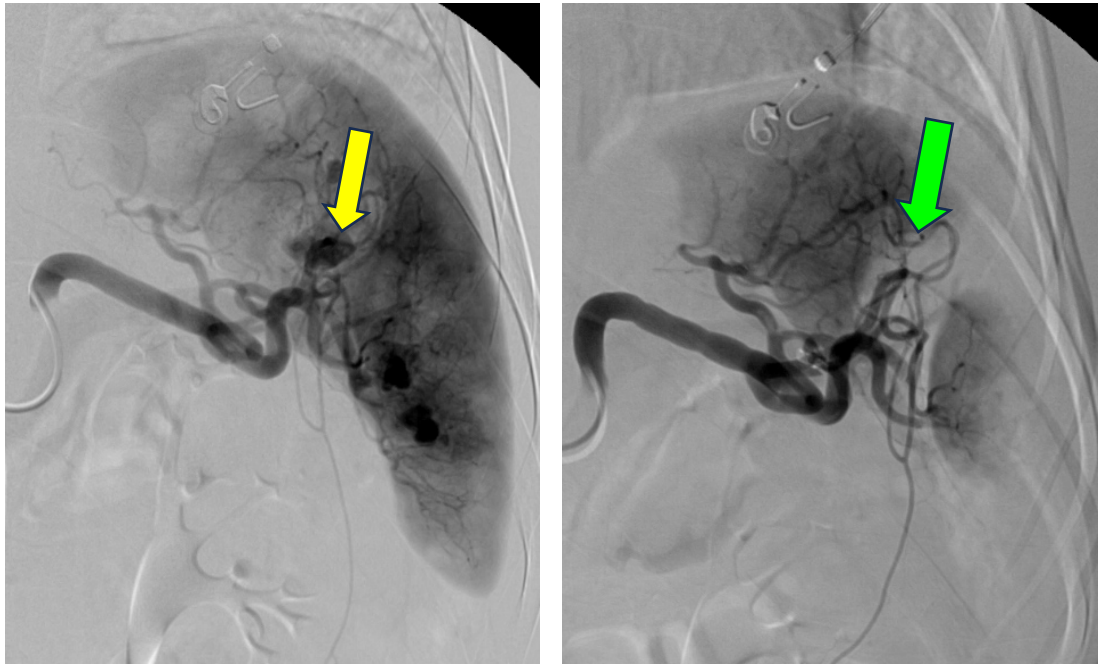

DSA before intravascular embolisation (left image) and after successful embolisation (right image). Before embolisation, note intrasplenic contrast extravasation (yellow arrow). After transarterial embolisation with sterile compressed absorbable sponge particles (Gelfoam), there is no contrast material extravasation (green arrow).

Chapter Outline

Interventional Radiologic Treatment of Posttraumatic Intrasplenic Pseudoaneurysm

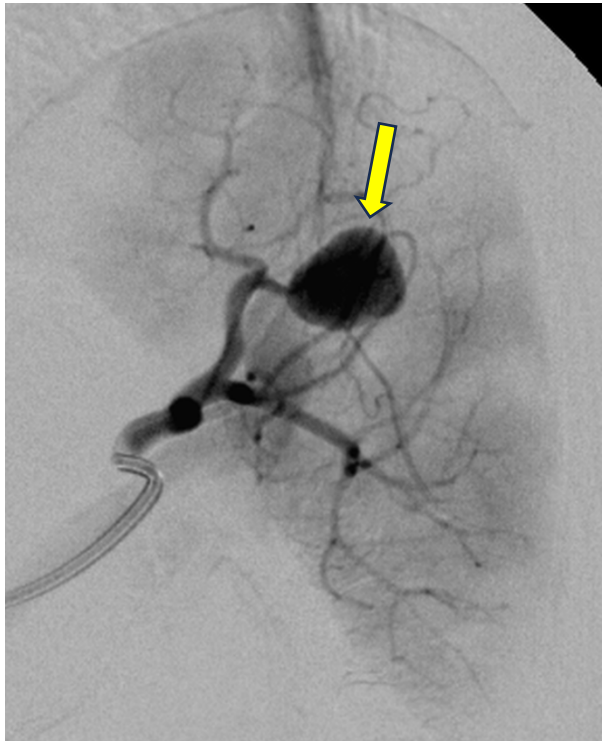

Splenic artery DSA showing large intrasplenic pseudoaneurysm (arrow).

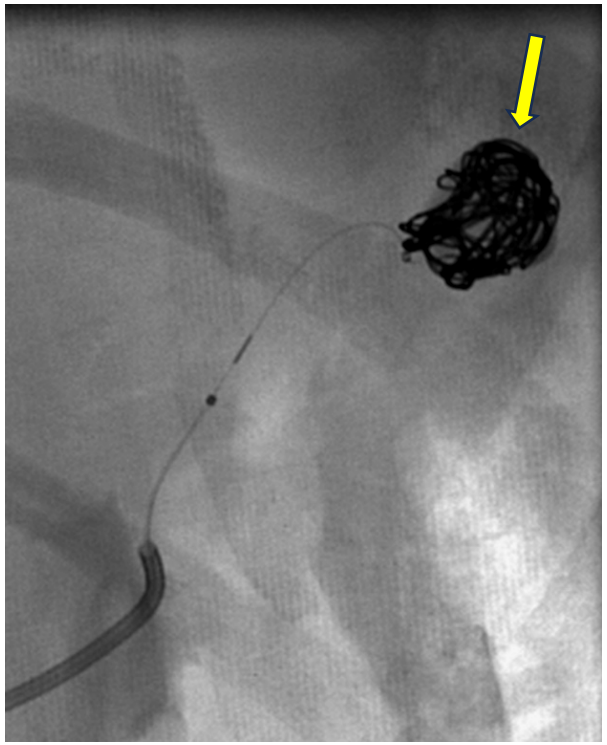

Metallic micro-coils inserted for packing of pseudoaneurysm (arrow).

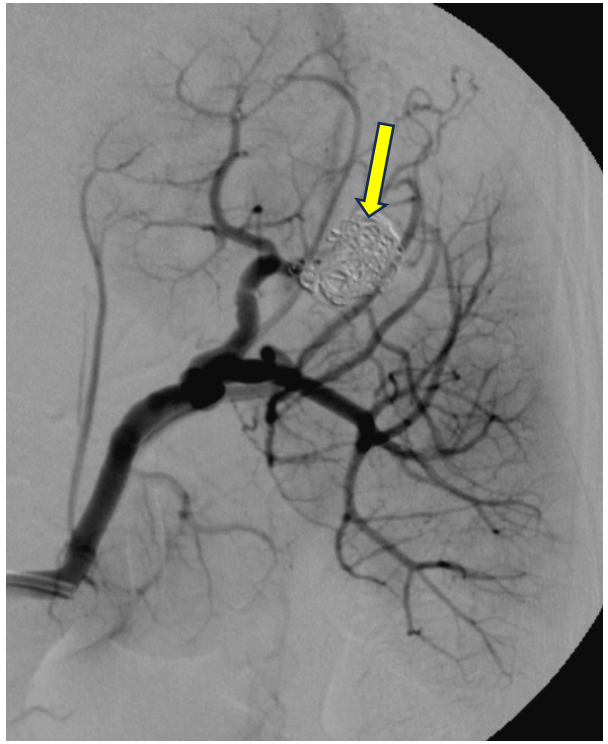

DSA: control after endovascular treatment showing coiled area (arrow).

Chapter Outline

Take-Home Messages

- Because US is the method of choice to detect gallbladder stones, it is the first-line imaging method in acute pancreatitis. However, the pancreas is cannot always be assessed entirely by means of transcutaneous US.
- Both multiphasic dynamic cross-sectional imaging with CT and MRI offer detailed and consistent demonstration of parenchymal pancreatic and splenic abnormalities.
- CT and MRI play a key role in the severity grading of acute pancreatitis, to distinguish the oedematous from the necrotising form and to detect complications during treatment.
- Image-guided fluid aspiration and drainage are useful techniques in the management of large, growing or infected fluid collections in the early phase after acute necrotising pancreatitis
- Imaging findings in chronic pancreatitis include both parenchymal and ductal changes. Although calcifications are easier to detect with CT, MRCP is more suitable to delineate and grade ductal changes such as strictures, cysts, and stones and to detect variants of the main pancreatic duct such as pancreas divisum that may predispose to pancreatitis.
- Imaging with CT and MRI and image-guided biopsy have an important role in the characterisation and staging of solid and cystic benign and malignant pancreatic neoplasms.

Chapter Outline

Take-Home Messages

- Ductal adenocarcinoma is the most common malignant pancreatic tumour, and CT and MRI are useful to distinguish potentially resectable tumours from those which are a priori unresectable for cure, thus indicating palliative treatment.

- Endocrine neoplasms of the pancreas (panNENs) include differentiated, benign tumours (functional or non-functional panNETs), undifferentiated malignant tumours (panNECs) or mixed neuroendocrine/non-neuroendocrine neoplasms (MiNENs). On cross-sectional contrast-enhanced images panNETs typically appear as hypervascular lesions within the pancreatic parenchyma, and it must be kept in mind that they may be multiple.

- Although serous, multicystic pancreatic adenomas are benign, mucinous cystadenomas and intraductal pancreatic mucinous neoplasms may undergo adenomatous proliferation, eventually transforming into carcinoma.

- The spleen is the most commonly injured abdominal organ due to blunt trauma. Initial imaging assessment is done with FAST. In haemodynamically stable patients undergoing conservative treatment CT is the method of choice for the detection and grading of the extent of splenic and pancreatic injuries and for early follow- up during non-surgical management.

- Transarterial embolisation is a well-established technique for minimally invasive and effective haemostasis in posttraumatic haemorrhage and for the treatment of pseudoaneurysms complicating inflammation and trauma of the pancreas and spleen.

Chapter Outline

References

1. Banks PA, Bollen TL, Dervenis C et al Classification of acute pancreatitis—2012:revision of the Atlanta classification and definitions by international consensus. Gut 2013;62:102–111. doi:10.1136/gutjnl-2012-302779
2. Shyu JY, Sainani NI, Sahni, VA, Necrotizing Pancreatitis: Diagnosis, Imaging, and Intervention RadioGraphics 2014; 34:1218–1239
3. Balci C. MRI assessment of chronic pancreatitis. Diagn Interv Radiol2011;17:249-54.
4. Kamat R, Gupta P, Rana S. Imaging in chronic pancreatitis:State of the art review. Indian J Radiol Imaging 2019;29:201-10.
5. Low G, Panu A , Millo N, Leen E (2011) Multimodality Imaging of Neoplastic and Non- Neoplastic Solid Lesions of the Pancreas. RadioGaphics 2011; 31:993-1015
6. Lee DW, Kim MK, Kim HG. Diagnosis of Pancreatic Neuroendocrine Tumors. Clin Endosc. 2017 Nov;50(6):537-545. doi: 10.5946/ce.2017.131. Epub 2017 Nov 30. PMID: 29207856; PMCID: PMC5719919.
7. Khanna L, Prasad SR, Sunnapwar A. Pancreatic Neuroendocrine Neoplasms: 2020 Update on Pathologic and Imaging Findings and Classification. RadioGraphics 2020; 40:1240–1262https://doi.org/10.1148/rg.2020200025
8. Miller FH, Lopes Vendrami C, Recht, HS. Pancreatic Cystic Lesions and Malignancy: Assessment, Guidelines, and the Field Defect RadioGraphics 2022; 42:87–105
9. Machado NO, Al Qadhi H, Al Wahibi K. Intraductal Papillary Mucinous Neoplasm of Pancreas. N Am J Med Sci. 2015 May;7(5):160-75. doi:
10. Kim N, Auerbach A, Manning MA. (2022) Algorithmic Approach to the Splenic Lesion Based on Radiologic-Pathologic Correlation. RadioGraphics 42, No. 3. https://doi.org/10.1148/rg.210071
11. Karlo CA, Stolzmann P, Do RK, Alkadhi H. Computed tomography of the spleen: how to interpret the hypodense lesion. Insights Imaging (2013) 4:65–76
12. Lee H, Kim JW, Hong JH et al. Cross-sectional Imaging of Splenic lesions. RadioGraphics 2018; 38:435–436 https://doi.org/10.1148/rg.2018170119
13. Becker CD, Mentha G, Terrier F (1998) Blunt abdominal trauma in adults: role of CT in the diagnosis and management of visceral injuries. Part 1: liver and spleen. Eur Radiol 8(4):553–562
14. Becker CD, Mentha G, Schmidlin F, Terrier F. Blunt abdominal trauma in adults: role of CT in the diagnosis and management of visceral injuries Part 2: Gastrointestinal tract and retroperitoneal organs. Eur. Radiol. 8, 772- 780 (1998)
15. Gamanagatti S, Rangarajan K, Kumar A, Jineesh. Blunt abdominal trauma: imaging and intervention. Curr Probl Diagn Radiol. 2015 Jul-Aug;44(4):321- 36. doi: 10.1067/j.cpradiol.2015.02.005. Epub 2015 Feb 12. PMID: 25801463.
16. Podda M, De Simone B, Ceresoli M, et al. Follow-up strategies for patients with splenic trauma managed non-operatively: the 2022 World Society of Emergency Surgery consensus document. World Journal of Emergency Surgery (2022) 17:52 https://doi.org/10.1186/s13017-022-00457-5

Chapter Outline

Test Your Knowledge

Q1 Which of the following statements are correct?

a) Multiphasic contrast – enhanced imaging of the pancreas can be done with both CT and MRI

b) The diagnosis of pancreatic ductal abnormalities with MRCP is based on the injection of Gadolinium- based contrast material

c) Non-surgical management of blunt splenic and pancreatic injuries is often facilitated by follow–up imaging with CT.

d) Image-guided biopsy, fluid aspiration and drainage are minimally invasive interventional radiologic techniques in the context of acute pancreatitis

Chapter Outline

Test Your Knowledge

correct
false

Q1 Which of the following statements are correct?

a) Multiphasic contrast – enhanced imaging of the pancreas can be done with both CT and MRI

b) The diagnosis of pancreatic ductal abnormalities with MRCP is based on the injection of Gadolinium- based contrast material

c) Non-surgical management of blunt splenic and pancreatic injuries is often facilitated by follow–up imaging with CT.

d) Image-guided biopsy, fluid aspiration and drainage are minimally invasive interventional radiologic techniques in the context of acute pancreatitis

Chapter Outline

Test Your Knowledge

Q2: Which of the following statements are correct regarding pancreas divisum?

a) The pancreatic body is separated from the pancreatic tail

b) The duct of Wirsung does not communicate with the duct of Santorini

c) Predisposes to cystic neoplasms

d) Predisposes to pancreatitis

Chapter Outline

Test Your Knowledge

correct
false

Q2: Which of the following statements are correct regarding pancreas divisum?

a) The pancreatic body is separated from the pancreatic tail

b) The duct of Wirsung does not communicate with the duct of Santorini

c) Predisposes to cystic neoplasms

d) Predisposes to pancreatitis

Test Your Knowledge

Q3: Which of the following statements are correct regarding pancreatic neoplasms?

a) The so- called "double duct sign" occurs in carcinoma of the pancreatic head.

b) Adenocarcinoma of the ampulla of Vater usually has a better prognosis after resection than ductal adenocarcinoma of the pancreas

c) Pancreatic neuro-endocrine tumours (panNETs) usually have a characteristic hypovascular appearance on CT and MRI

d) On multiphasic contrast-enhanced CT and MRI, ductal adenocarcinoma of the pancreas usually appears strongly hypervascular in the pancreatic phase followed by a rapid "washout" in the portal phase.

Chapter Outline

Test Your Knowledge

correct
false

Q3: Which of the following statements are correct regarding pancreatic neoplasms?

a) The so- called "double duct sign" occurs in carcinoma of the pancreatic head.

b) Adenocarcinoma of the ampulla of Vater usually has a better prognosis after resection than ducal adenocarcinoma of the pancreas

c) Pancreatic neuro-endocrine tumours (panNETs) usually have a characteristic hypovascular appearance on CT and MRI

d) On multiphasic contrast-enhanced CT and MRI, ductal adenocarcinoma of the pancreas usually appears strongly hypervascular in the pancreatic phase followed by a rapid "washout" in the portal phase.

Chapter Outline

Test Your Knowledge

Q4: Which of the following statements are correct?

a) In pancreatic disease, endoscopic- retrograde cholangiopancreatography (ERCP) and endoscopic ultrasound (EUS) are usually performed as complementary methods after noninvasive imaging with CT or MRI.

b) Cystic abnormalities of the pancreas may occur due to chronic pancreatitis or to neoplastic disease

c) On MRCP, intraductal pancreatic mucinous neoplasms (IPMNs) may appear as segmental ductectasia

d) On CT, parenchymal pancreatic calcifications are typical signs of acute pancreatitis

Test Your Knowledge

correct
false

Q4: Which of the following statements are correct?

a) In pancreatic disease, endoscopic- retrograde cholangiopancreatography (ERCP) and endoscopic ultrasound (EUS) are usually performed as complementary methods after noninvasive imaging with CT or MRI.

b) Cystic abnormalities of the pancreas may occur due to chronic pancreatitis or to neoplastic disease

c) On MRCP, intraductal pancreatic mucinous neoplasms (IPMNs) may appear as segmental ductectasia

d) On CT, parenchymal pancreatic calcifications are typical signs of acute pancreatitis

Chapter Outline

Test Your Knowledge

Q5: Which of the following statements are correct in the context of CT in chronic pancreatitis?

a) Multiple parenchymal calcifications are common findings

b) Intraductal pancreatic calculi are often calcified

c) The pancreatic duct often appears irregular with stenosis, dilatation and outpouchings

d) Chronic pancreatitis of the pancreatic head may lead to stenosis of the distal common bile duct

Chapter Outline

Test Your Knowledge

correct
false

Q5: Which of the following statements are correct in the context of CT in chronic pancreatitis?

a) Multiple parenchymal calcifications are common findings

b) Intraductal pancreatic calculi are often calcified

c) The pancreatic duct often appears irregular with stenosis, dilatation and outpouchings

d) Chronic pancreatitis of the pancreatic head may lead to stenosis of the distal common bile duct

Test Your Knowledge

Q6: Which of the following statements are correct?

a) Endocrine neoplasms of the pancreas (panNENs) can be benign or malignant

b) Insulinoma can be multiple

c) Ductal adenocarcinoma of the pancreas has an endocrine activity

d) Endocrine tumours of the pancreas may be functionally active or inactive

Chapter Outline

Test Your Knowledge

correct
false

Q6: Which of the following statements are correct?

a) Endocrine neoplasms of the pancreas (panNENs) can be benign or malignant

b) Insulinoma can be multiple

c) Ductal adenocarcinoma of the pancreas has an endocrine activity

d) Endocrine tumours of the pancreas may be functionally active or inactive

Chapter Outline

Test Your Knowledge

Q7: Which of the following statements are correct?

a) Serous multicystic adenomas of the pancreas must be resected because they undergo malignant transformation

b) Intraductal pancreatic mucinous neoplasms (IPMN) have no malignant potential

c) IPMN can appear as segmental ductectasia or as cystic lesions with ductal contact

d) Pancreatic cystic lesions can be further characterised by means of image- guided fine-needle aspiration

Chapter Outline

Test Your Knowledge

correct
false

Q7: Which of the following statements are correct?

a) Serous multicystic adenomas of the pancreas must be resected because they undergo malignant transformation

b) Intraductal pancreatic mucinous neoplasms (IPMN) have no malignant potential

c) IPMN can appear as segmental ductectasia or as cystic lesions with ductal contact

d) Pancreatic cystic lesions can be further characterised by means of image- guided fine-needle aspiration

Chapter Outline

Test Your Knowledge

Q8: Which of the following statements are correct regarding pancreatic pseudocysts in acute necrotising pancreatitis?

a) They may grow and compress the adjacent gastrointestinal structures or bile ducts

b) They may become superinfected

c) They may undergo malignant transformation

d) They may be treated by image- guided percutaneous drainage

Chapter Outline

Test Your Knowledge

correct
false

Q8: Which of the following statements are correct regarding pancreatic pseudocysts in acute necrotising pancreatitis?

a) They may grow and compress the adjacent gastrointestinal structures or bile ducts

b) They may become superinfected

c) They may undergo malignant transformation

d) They may be treated by image- guided percutaneous drainage

Chapter Outline

Test Your Knowledge

Q9: Which of the following statements are correct regarding blunt abdominal trauma ?

a) Splenic injuries after blunt trauma are managed conservatively whenever possible

b) CT is often used for follow- up of blunt splenic injuries in order to detect complications during conservative treatment

c) Blunt splenic injuries may include subcapsular haematoma, intraparenchymal haematoma , laceration, and active bleeding.

d) CT is the initial imaging technique of choice in haemodynamically unstable patients with blunt abdominal trauma

Chapter Outline

Test Your Knowledge

correct
false

Q9: Which of the following statements are correct regarding blunt abdominal trauma ?

a) Splenic injuries after blunt trauma are managed conservatively whenever possible

b) CT is often used for follow- up of blunt splenic injuries in order to detect complications during conservative treatment

c) Blunt splenic injuries may include subcapsular haematoma, intraparenchymal haematoma , laceration, and active bleeding.

d) CT is the initial imaging technique of choice in haemodynamically unstable patients with blunt abdominal trauma

Chapter Outline

Test Your Knowledge

Q10: Which of the following statements are correct?

a) Pseudoaneurysms of the pancreatic or splenic arteries may occur after blunt trauma or in the context of severe acute pancreatitis.

b) Pseudoaneurysms are best detected with scintigraphy or ERCP

c) Intraarterial catheter embolisation is a minimally invasive interventional radiologic treatment of pseudoaneurysms of the splenic and pancreatic arteries

d) Intraarterial catheter embolisation may be done to avoid splenectomy for acute arterial haemorrhage after blunt splenic trauma.

Chapter Outline

Test Your Knowledge

correct
false

Q10: Which of the following statements are correct?

a) Pseudoaneurysms of the pancreatic or splenic arteries may occur after blunt trauma or in the context of severe acute pancreatitis.

b) Pseudoaneurysms are best detected with scintigraphy or ERCP

c) Intraarterial catheter embolisation is a minimally invasive interventional radiologic treatment of pseudoaneurysms of the splenic and pancreatic arteries

d) Intraarterial catheter embolisation may be done to avoid splenectomy for acute arterial haemorrhage after blunt splenic trauma.

Chapter Outline

Chapter Outline