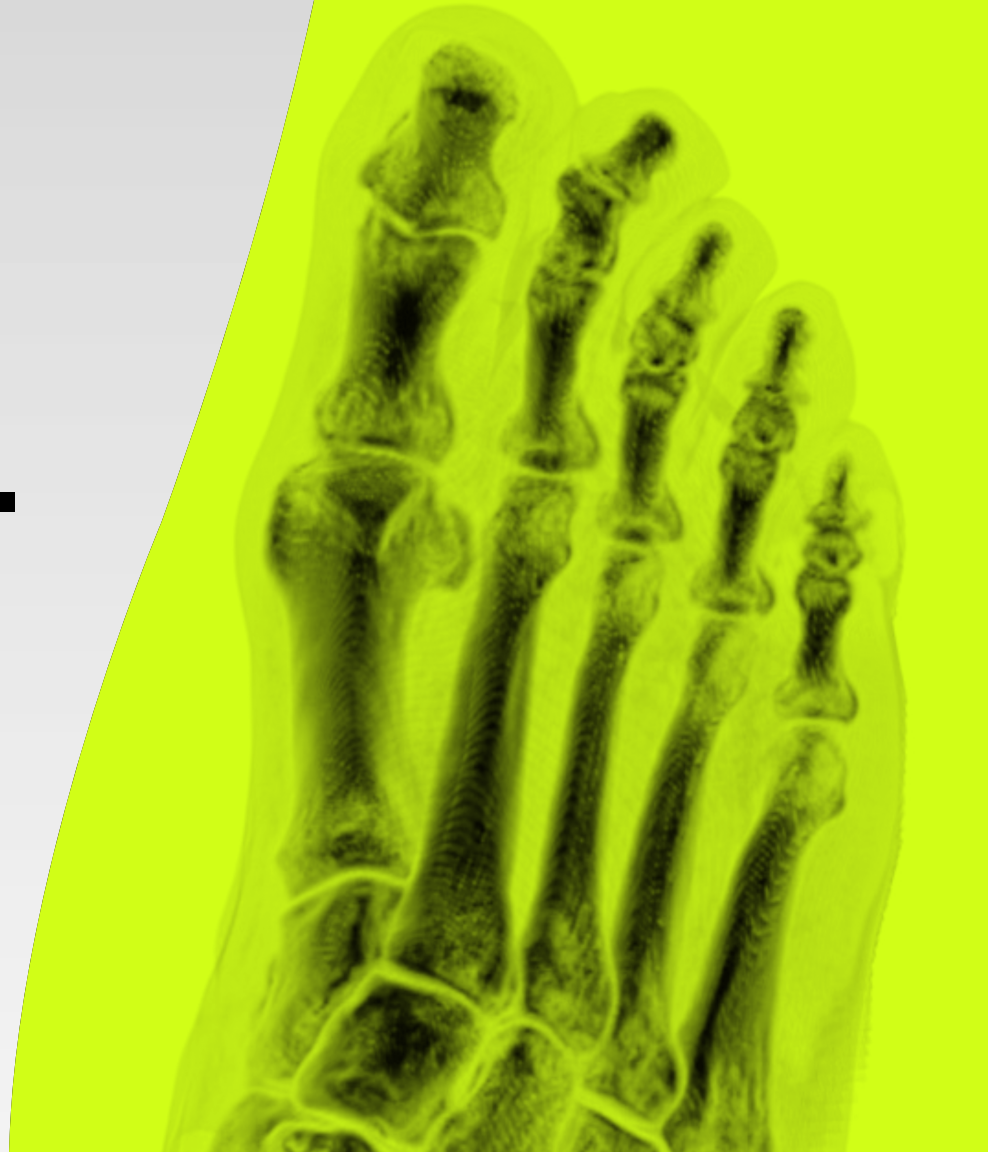


**MODERN**  
**RADIOLOGY**  
eBook

# Musculo- skeletal Imaging

**ESR** **RF** EUROPEAN SOCIETY  
OF RADIOLOGY



# / Preface

*Modern Radiology* is a free educational resource for radiology published online by the European Society of Radiology (ESR). The title of this second, rebranded version reflects the novel didactic concept of the **ESR eBook** with its unique blend of text, images and schematics in the form of succinct pages, supplemented by clinical imaging cases, Q&A sections and hyperlinks allowing to switch quickly between the different sections of organ-based and more technical chapters, summaries and references.

Its chapters are based on the contributions of over 100 recognised European experts, referring to both general technical and organ-based clinical imaging topics. The new graphical look showing Asklepios with fashionable glasses, symbolises the combination of classical medical teaching with contemporary style education.

Although the initial version of the **ESR eBook** was created to provide basic knowledge for medical students and teachers of undergraduate courses, it has gradually expanded its scope to include more advanced knowledge

for readers who wish to 'dig deeper'. As a result, *Modern Radiology* covers also topics of the postgraduate levels of the *European Training Curriculum for Radiology*, thus addressing postgraduate educational needs of residents. In addition, it reflects feedback from medical professionals worldwide who wish to update their knowledge in specific areas of medical imaging and who have already appreciated the depth and clarity of the **ESR eBook** across the basic and more advanced educational levels.

I would like to express my heartfelt thanks to all authors who contributed their time and expertise to this voluntary, non-profit endeavour as well as Carlo Catalano, Andrea Laghi and András Palkó, who had the initial idea to create an **ESR eBook** and - finally - to the ESR Office for their technical and administrative support.

*Modern Radiology* embodies a collaborative spirit and unwavering commitment to this fascinating medical discipline which is indispensable for modern patient care. I hope that this **educational** tool may encourage curiosity and critical thinking, contributing to the appreciation of the art and science of radiology across Europe and beyond.

**Minerva Becker**, Editor

## CHAPTER OUTLINE:

Imaging Anatomy

Strengths, Weaknesses  
and Roles of Imaging  
Modalities

Arthropathies

Fractures and  
Dislocations

Infection

Tumours and Tumour-  
like Conditions

Metabolic Diseases

Developmental  
Abnormalities

Take-Home Messages

Suggested Reading  
and Sources

Test Your Knowledge

# / Copyright and Terms of Use

This work is licensed under a [Creative Commons Attribution-NonCommercial-NoDerivatives 4.0 International License](https://creativecommons.org/licenses/by-nc-nd/4.0/).

## You are free to:

Share, copy and redistribute the material in any medium or format

## Under the following terms:

/ **ATTRIBUTION** – You must give appropriate credit, provide a link to the license and **indicate if changes were made**. You may do so in any reasonable manner, but not in any way that suggests the licensor endorses you or your use.

/ **NONCOMMERCIAL** – You may not use the material for commercial purposes.

/ **NO DERIVATIVES** – If you remix, transform or build upon the material, you may not distribute the modified material.

## How to cite this work:

European Society of Radiology,  
Üstün Aydingöz (2025)  
ESR Modern Radiology eBook:

/ Musculoskeletal Imaging. DOI 10.26044/  
esr-undergraduate-ebook-04

## CHAPTER OUTLINE:

Imaging Anatomy

Strengths, Weaknesses  
and Roles of Imaging  
Modalities

Arthropathies

Fractures and  
Dislocations

Infection

Tumours and Tumour-  
like Conditions

Metabolic Diseases

Developmental  
Abnormalities

Take-Home Messages

Suggested Reading  
and Sources

Test Your Knowledge

# / Signage

<=> **CORE KNOWLEDGE**

<!=> **ATTENTION**

<↑> **HYPERLINKS**

>=< **FURTHER KNOWLEDGE**

>|< **COMPARE**

<∞> **REFERENCES**

<?> **QUESTIONS**

**Musculo-  
skeletal  
Imaging**

## CHAPTER OUTLINE:

Imaging Anatomy

Strengths, Weaknesses  
and Roles of Imaging  
Modalities

Arthropathies

Fractures and  
Dislocations

Infection

Tumours and Tumour-  
like Conditions

Metabolic Diseases

Developmental  
Abnormalities

Take-Home Messages

Suggested Reading  
and Sources

Test Your Knowledge



# Musculo- skeletal Imaging

**AUTHOR**

Üstün Aydingöz

**AFFILIATION**

Department of Radiology, Hacettepe University School of Medicine, Ankara, Turkey

<↑> **HYPERLINK**

[uaydingo@hacettepe.edu.tr](mailto:uaydingo@hacettepe.edu.tr)

**CHAPTER OUTLINE:**

Imaging Anatomy

Strengths, Weaknesses  
and Roles of Imaging  
Modalities

Arthropathies

Fractures and  
Dislocations

Infection

Tumours and Tumour-  
like Conditions

Metabolic Diseases

Developmental  
Abnormalities

Take-Home Messages

Suggested Reading  
and Sources

Test Your Knowledge

# / Chapter Outline

## / Imaging Anatomy

- / Bones
- / Muscles
- / Joints
- / Subcutaneous Tissue
- / Compartmental Anatomy

## / Strengths, Weaknesses and Roles of Imaging Modalities

- / Conventional Radiographs (CRX)
- / Computed Tomography (CT)
- / Ultrasonography (US)
- / Magnetic Resonance Imaging (MRI)

## / Arthropathies

- / Osteoarthritis
- / Rheumatoid Arthritis
- / Seronegative Arthritis
- / Axial Spondyloarthritis
- / Metabolic Arthritis

## / Fractures and Dislocations

- / Basic Principles
- / Describing Fractures and Dislocations and Terminology
- / Features in Children
- / Stress Fractures
- / Pathological Fractures
- / Pearls and Pitfalls

## / Infection

- / Osteomyelitis
- / Periprosthetic Infection
- / Septic Arthritis
- / Pyomyositis, Septic/Necrotising Fasciitis, Septic Tenosynovitis
- / Lymphoedema Versus Cellulitis

## / Tumours and Tumour-like Conditions

- / Don't Touch Lesions
- / Radiology of Bone Tumours
- / Lesion Borders
- / Lesion Matrix
- / Periosteal Reaction
- / Characteristic Findings
- / Soft Tissue Tumours

## / Metabolic Diseases

- / Osteoporosis
- / Osteomalacia
- / Rickets
- / Renal Dystrophy and Hyperparathyroidism

## / Developmental Abnormalities

- / Scoliosis
- / Developmental Dysplasia of the Hip

## / Take-Home Messages

## / Suggested Reading and Sources

## / Test Your Knowledge

### CHAPTER OUTLINE:

Imaging Anatomy

Strengths, Weaknesses and Roles of Imaging Modalities

Arthropathies

Fractures and Dislocations

Infection

Tumours and Tumour-like Conditions

Metabolic Diseases

Developmental Abnormalities

Take-Home Messages

Suggested Reading and Sources

Test Your Knowledge

**CHAPTER OUTLINE:**

**Imaging Anatomy**

Strengths, Weaknesses  
and Roles of Imaging  
Modalities

Arthropathies

Fractures and  
Dislocations

Infection

Tumours and Tumour-  
like Conditions

Metabolic Diseases

Developmental  
Abnormalities

Take-Home Messages

Suggested Reading  
and Sources

Test Your Knowledge

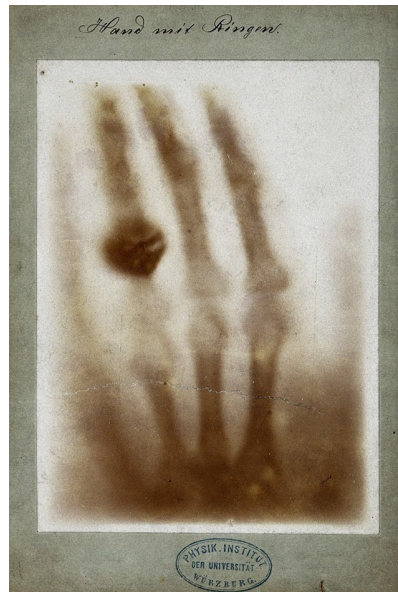# / Imaging Anatomy

# / Musculoskeletal (MSK) Imaging Anatomy

Radiology is a fascinating specialty in medicine, dealing—by way of its diagnostic and interventional procedures—with not only recognition, but also treatment or palliation of abnormalities and diseases. The first known radiological image of human body from 22 December 1895 (**Figure 1**) is reportedly the hand radiograph of Anna Bertha Ludwig, the wife of the discoverer of X rays, Dr. Wilhelm Conrad Röntgen, who is considered to be the founder of radiology. This makes musculoskeletal imaging literally the first subspecialty in radiology!

Currently, musculoskeletal (MSK) radiologists use a wide array of ingenious techniques to diagnose—and sometimes treat—abnormalities and diseases in humans. Knowledge of musculoskeletal anatomy is essential in this context.

The **musculoskeletal (MSK) system** comprises bones, muscles, joints, subcutaneous tissue and distinct anatomic compartments, which play an important functional role.



**FIGURE 1**

Image from Wikipedia, Public Domain.

## / Musculoskeletal Imaging

### CHAPTER OUTLINE:

#### Imaging Anatomy

Strengths, Weaknesses and Roles of Imaging Modalities

Arthropathies

Fractures and Dislocations

Infection

Tumours and Tumour-like Conditions

Metabolic Diseases

Developmental Abnormalities

Take-Home Messages

Suggested Reading and Sources

Test Your Knowledge

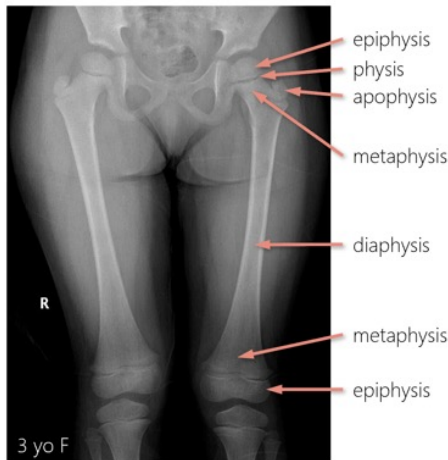
# / Imaging Anatomy of Bones

All **long bones** comprise epiphysis, metaphysis, diaphysis—and sometimes apophysis (**Figures 2 and 3**). Apophyses do not contribute to longitudinal growth and do not form a joint part as do the epiphyses.

The physes normally close during adolescence and no longer remain visible as radiolucent bands by the end of the second decade or the early years of the third decade of life.

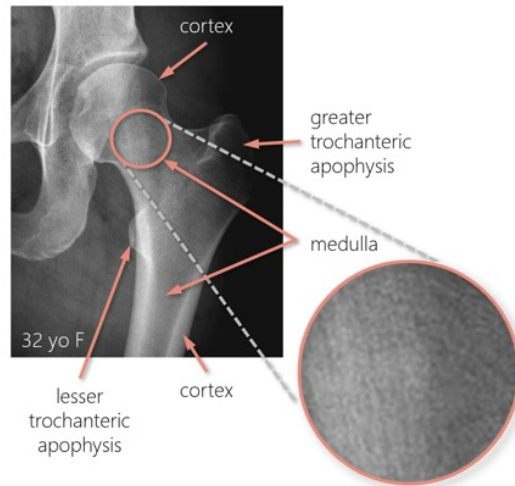
**FIGURE 2**

Conventional radiographs illustrating parts of a long bone (here the femur) in a child and an adult.



The thickness of the bone cortex (or **cortical bone**) can vary among different bones and even within the same bone. It is usually thicker in the diaphysis.

The **bone medulla** (containing medullary bone or trabecular bone) comprises trabeculae, red and yellow marrow. The trabecular bone is also called “cancellous” bone.



## / Musculo-skeletal Imaging

### CHAPTER OUTLINE:

#### Imaging Anatomy

Strengths, Weaknesses and Roles of Imaging Modalities

Arthropathies

Fractures and Dislocations

Infection

Tumours and Tumour-like Conditions

Metabolic Diseases

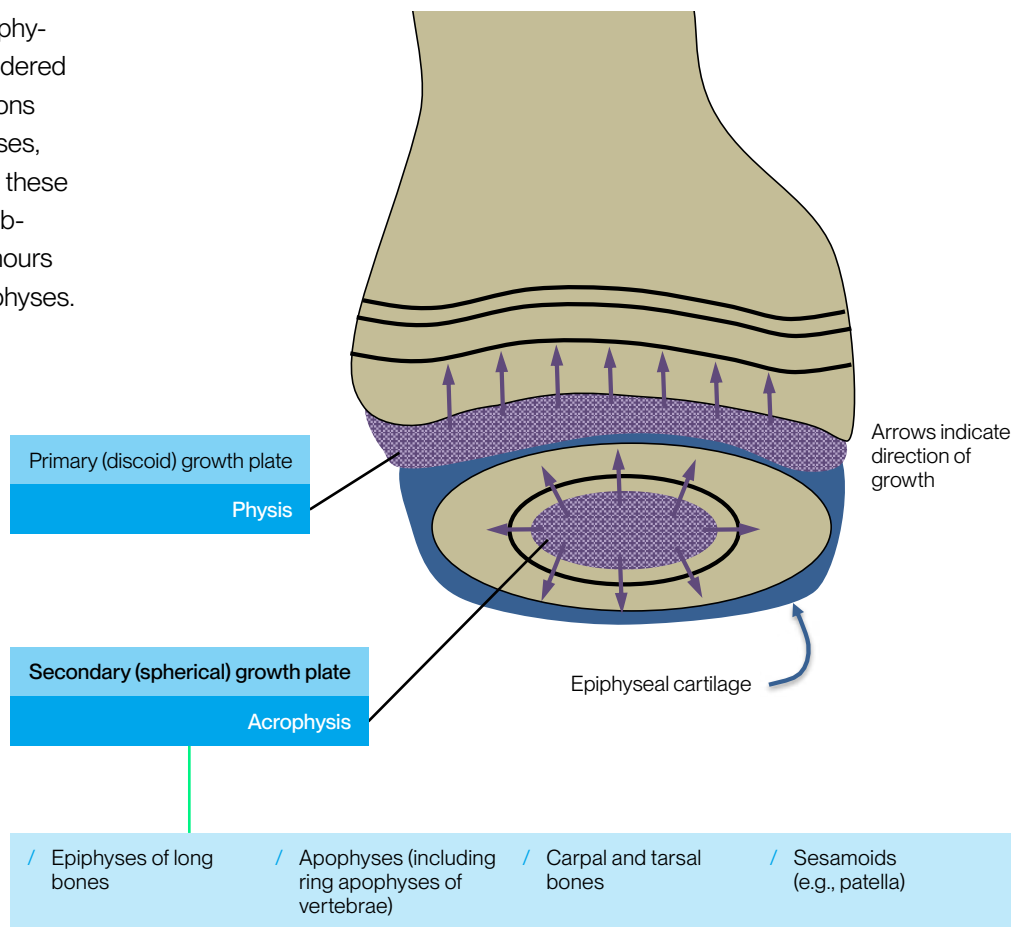
Developmental Abnormalities

Take-Home Messages

Suggested Reading and Sources

Test Your Knowledge

Carpal and tarsal bones, apophyses and sesamoids are considered as epiphysis analogues. Lesions with a predilection for epiphyses, therefore, also tend to involve these analogues, which are an established location for certain tumours that preferentially involve epiphyses.



**FIGURE 3**

Drawing based on Oestreich AE. Skeletal Radiol 2003.

**Musculo-skeletal Imaging**

**CHAPTER OUTLINE:**

**Imaging Anatomy**

Strengths, Weaknesses and Roles of Imaging Modalities

Arthropathies

Fractures and Dislocations

Infection

Tumours and Tumour-like Conditions

Metabolic Diseases

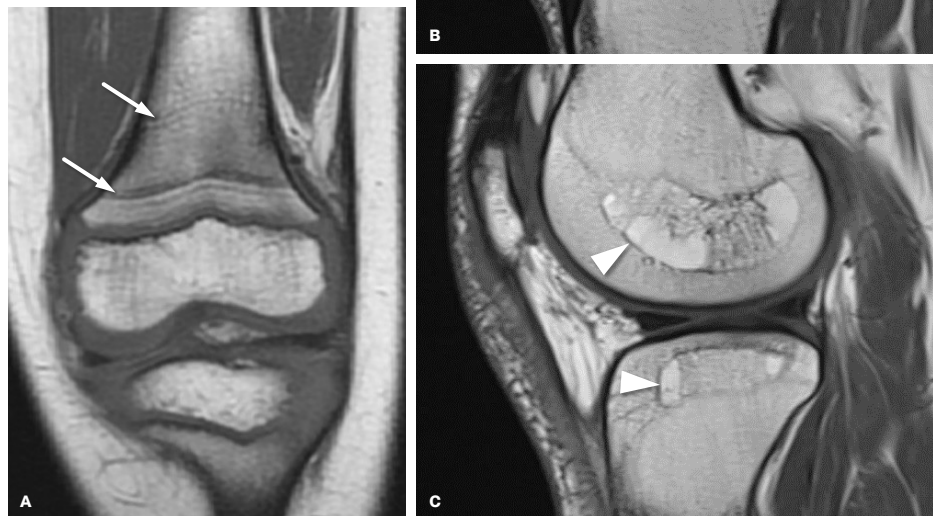
Developmental Abnormalities

Take-Home Messages

Suggested Reading and Sources

Test Your Knowledge

Formerly referred to as growth “arrest” lines, growth “recovery” lines indicate periods of renewed or increased growth, presumably after a period of inhibited growth of the bone (**Figure 4**). They may, however, occur during normal growth and growth spurts.



**FIGURE 4**

Growth recovery lines (**arrows** on **A**) on MRI in a 4-year-old boy with resolved osteomyelitis elsewhere in this extremity. Growth recovery lines may occasionally present as curvilinear intra-epiphyseal silhouettes (**arrowheads** on **B** and **C**), giving the bone-within-bone appearance as in this 31-year-old woman, who sustained an ipsilateral femoral diaphyseal fracture at 10 years of age, whereupon she had had limited mobility for 6 months. Her other leg was unremarkable.

## Musculoskeletal Imaging

### CHAPTER OUTLINE:

#### Imaging Anatomy

Strengths, Weaknesses and Roles of Imaging Modalities

Arthropathies

Fractures and Dislocations

Infection

Tumours and Tumour-like Conditions

Metabolic Diseases

Developmental Abnormalities

Take-Home Messages

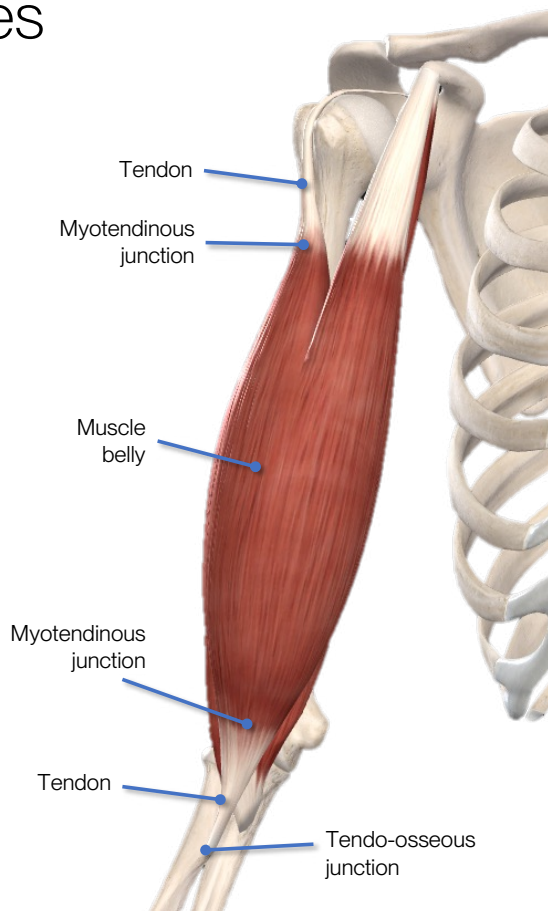
Suggested Reading and Sources

Test Your Knowledge

# / Imaging Anatomy of Muscles

Muscles have bellies, myotendinous junctions, tendons and tendo-osseous junctions (**Figure 5**).

The **myotendinous junction** is the site of most muscle strains (**Figure 6**), while the **tendo-osseous junction** is an expected site of overuse injury (**Figure 7**).



**FIGURE 5**

Various muscle components.

## / Musculo-skeletal Imaging

### CHAPTER OUTLINE:

#### Imaging Anatomy

Strengths, Weaknesses and Roles of Imaging Modalities

Arthropathies

Fractures and Dislocations

Infection

Tumours and Tumour-like Conditions

Metabolic Diseases

Developmental Abnormalities

Take-Home Messages

Suggested Reading and Sources

Test Your Knowledge



**CHAPTER OUTLINE:**

**Imaging Anatomy**

Strengths, Weaknesses  
and Roles of Imaging  
Modalities

Arthropathies

Fractures and  
Dislocations

Infection

Tumours and Tumour-  
like Conditions

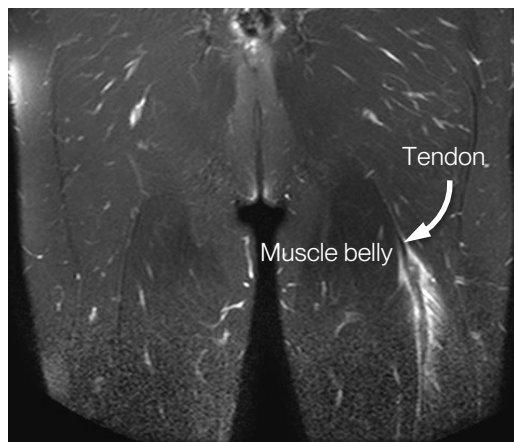
Metabolic Diseases

Developmental  
Abnormalities

Take-Home Messages

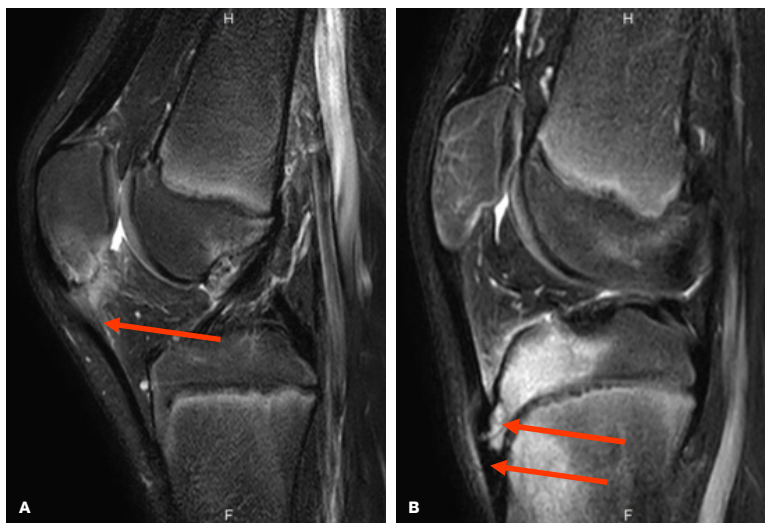
Suggested Reading  
and Sources

Test Your Knowledge



**FIGURE 6**

Left hamstring strain involving the myotendinous junction in an amateur football player. Fluid-sensitive MRI sequences such as the ones here show oedema as conspicuously white areas and are extensively used in MSK imaging.



**FIGURE 7**

Chronic overuse injury at the tendo-osseous junctions of the proximal (A) and distal (B) aspects of the patellar tendon in two different 13-year-old boys (arrows).

# / Imaging Anatomy of Joints

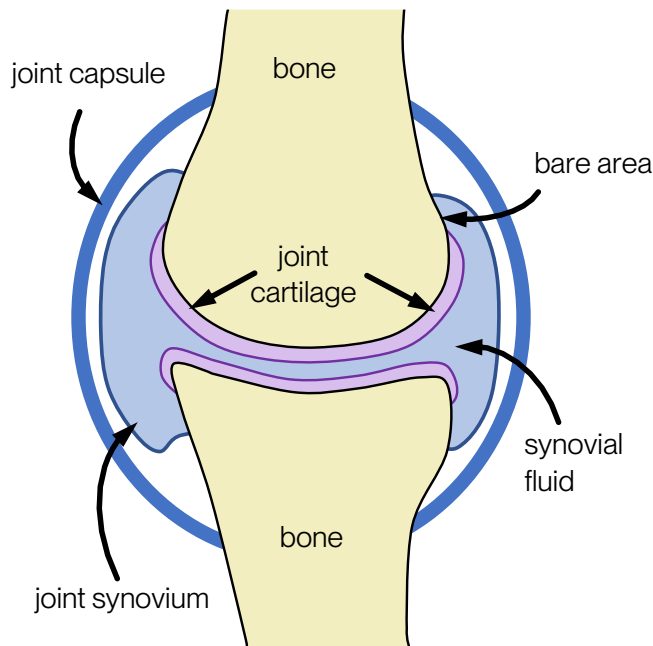
**Synovial joints (Figure 8)** are surrounded by a capsule which is continuous with the periosteum of the articulating bones and sometimes formed by a continuum of collagen-rich structures such as ligaments, bands and tendons.

Some ligaments (e.g., anterior and posterior cruciate ligaments of the knee) and tendons (e.g., biceps long head tendon in the shoulder and popliteus tendon in the knee) are intraarticular.

Ligaments inside a joint are usually covered by synovium—joint-traversing tendons are usually not.

Some joints have specialised structures such as meniscus (knee), labrum (shoulder and hip) and triangular fibrocartilage complex (TFCC; wrist), which serve primarily as either buffer (menisci, TFCC) or deepen the socket-type joint (labra).

The most important component of a synovial joint is the **joint cartilage**, the loss of which is usually associated with a cascade of events leading to the dysfunction and destruction of a joint.



**FIGURE 8**

A synovial joint.

## CHAPTER OUTLINE:

### Imaging Anatomy

Strengths, Weaknesses  
and Roles of Imaging  
Modalities

Arthropathies

Fractures and  
Dislocations

Infection

Tumours and Tumour-  
like Conditions

Metabolic Diseases

Developmental  
Abnormalities

Take-Home Messages

Suggested Reading  
and Sources

Test Your Knowledge

Although they do not provide cross-sectional information, radiographs are the **first-line imaging modality to study joints**. Cross-sectional examination of joints is best accomplished by magnetic resonance imaging

(MRI, see **Figure 9**), which gives the most comprehensive non-invasive information about not only the soft tissue components of a joint, but also the bones that form it.

## Musculoskeletal Imaging

### CHAPTER OUTLINE:

#### Imaging Anatomy

Strengths, Weaknesses and Roles of Imaging Modalities

Arthropathies

Fractures and Dislocations

Infection

Tumours and Tumour-like Conditions

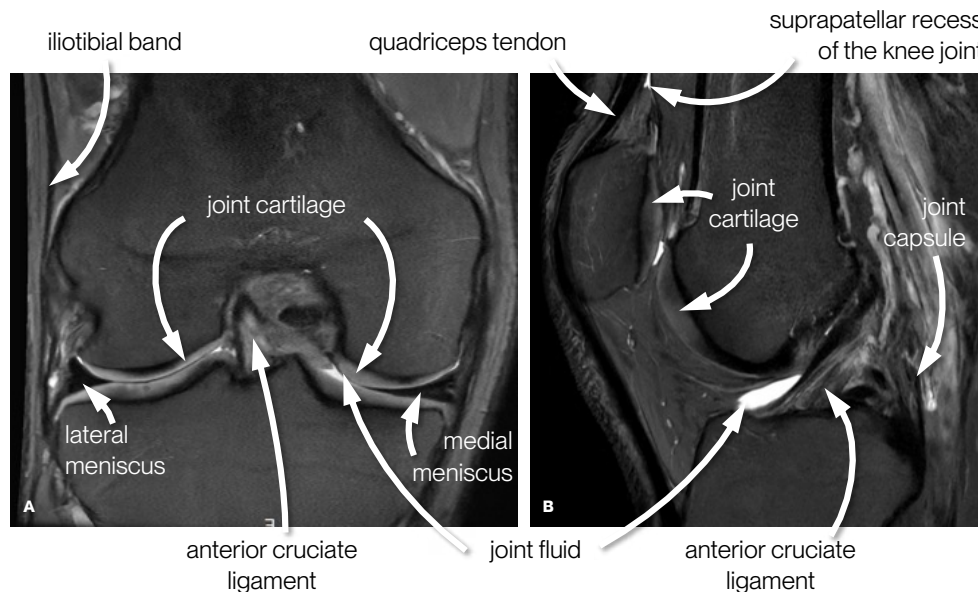
Metabolic Diseases

Developmental Abnormalities

Take-Home Messages

Suggested Reading and Sources

Test Your Knowledge



**FIGURE 9**

Normal anatomy of the knee joint as seen on MRI. Coronal plane (A) and sagittal plane (B).

Radiographs give important clues about bones and soft tissue components of joints. Uses of such clues include—but are not limited to—**joint effusion estimation** and **joint cartilage loss assessment** (see Arthropathies>Osteoarthritis).

&lt;=&gt; ATTENTION

**Musculoskeletal Imaging**

## CHAPTER OUTLINE:

**Imaging Anatomy**

Strengths, Weaknesses  
and Roles of Imaging  
Modalities

Arthropathies

Fractures and  
Dislocations

Infection

Tumours and Tumour-  
like Conditions

Metabolic Diseases

Developmental  
Abnormalities

Take-Home Messages

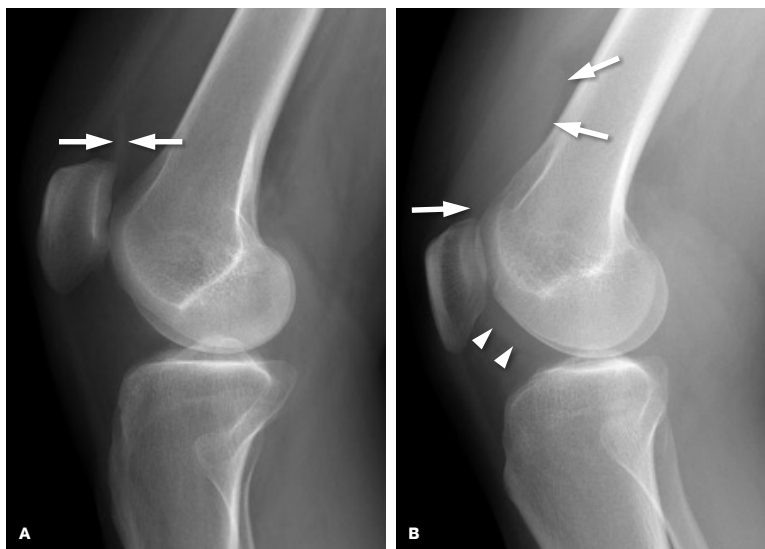
Suggested Reading  
and Sources

Test Your Knowledge

**Joint fluid estimation on radiographs**

The knee is the largest joint in the human body. The suprapatellar recess (**Figure 9**) can be used for joint effusion assessment on radiographs. **Figure 10A** shows a normal suprapatellar recess (arrows) with a thickness  $\leq 5$  mm in a properly obtained lateral radiograph. **Figure 10B** shows a knee joint effusion with a distended suprapatellar recess (**arrows**). Also note the increased joint fluid tracks along the femoral trochlea (**arrowheads**), a feature not visible on **A**, where there is no joint effusion.

Suprapatellar recess distention with effusion can also be used to search for intra-articular fractures by taking advantage of the gravity-dependent layering of bone marrow fat and blood that flow into the joint space with such fractures (see Fractures and Dislocations>Pearls and Pitfalls in Identifying Fractures). Such use entails cross-table horizontal projection of X-rays to the image detector.

**FIGURE 10**

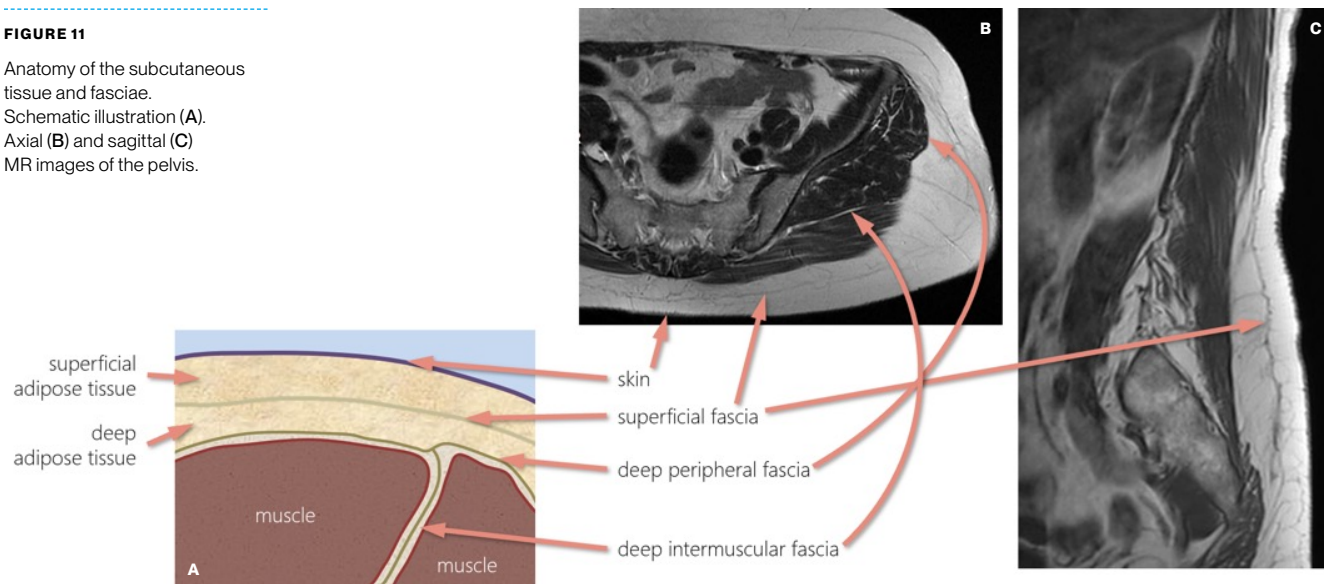
Lateral radiographs of a normal knee joint (**A**) and a joint with knee effusion (**B**).

# / Imaging Anatomy of Subcutaneous Tissue

Anatomists, surgeons and radiologists tend to use different terms to describe the components of the fascial system. The **radiological approach** is illustrated in **Figure 11**. Where muscles abut bones, the deep intermuscular fascia is in continuity with the periosteum. These structures are best depicted on MRI.

**FIGURE 11**

Anatomy of the subcutaneous tissue and fasciae. Schematic illustration (A). Axial (B) and sagittal (C) MR images of the pelvis.



## CHAPTER OUTLINE:

### Imaging Anatomy

Strengths, Weaknesses  
and Roles of Imaging  
Modalities

Arthropathies

Fractures and  
Dislocations

Infection

Tumours and Tumour-  
like Conditions

Metabolic Diseases

Developmental  
Abnormalities

Take-Home Messages

Suggested Reading  
and Sources

Test Your Knowledge

# / Compartmental Anatomy and How It Relates to Imaging

**Compartments** are anatomic spaces with natural boundaries to tumour spread. Each bone and each joint is a distinct compartment. Muscles or muscle groups are compartments. Compartmental involvement of primary malignant musculoskeletal

## >=< FURTHER KNOWLEDGE

STAGE	TUMOUR	METASTASES	GRADE
IA	T1	M0	G1
IB	T2	M0	G1
IIA	T1	M0	G2
IIB	T2	M0	G2
III	T1 or T2	M1	G1 or G2

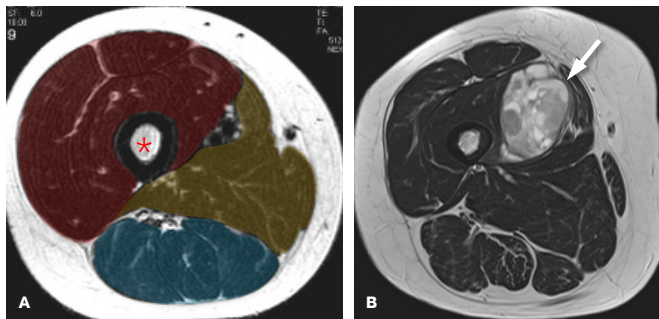
- / T1, tumour is intra-compartmental; T2, tumour is extra-compartmental.
- / M0, no regional or distant metastasis; M1, regional or distant metastases.
- / G1, low histological grade; G2, high histological grade.

**FIGURE 12**

The Enneking staging system.

tumours is an important parameter in the **Enneking staging system (Figure 12)**, which is used in patient management and outcome prediction.

As an example, the thigh muscles are divided into three compartments: anterior, medial and posterior (Figure 13). The femur itself is a distinct compartment.



**FIGURE 13**

A. Thigh muscle compartments as seen on axial MRI: anterior (red), medial (yellow), posterior (blue). Femur (asterisk). B. Intra-compartmental synovial sarcoma (arrow) in a 44-year-old woman. The mass lesion is limited to the anterior compartment of the thigh.

## CHAPTER OUTLINE:

### Imaging Anatomy

Strengths, Weaknesses and Roles of Imaging Modalities

Arthropathies

Fractures and Dislocations

Infection

Tumours and Tumour-like Conditions

Metabolic Diseases

Developmental Abnormalities

Take-Home Messages

Suggested Reading and Sources

Test Your Knowledge

Interventional radiologists or oncologic orthopaedists perform tumour biopsies. It is best to make the biopsy at the medical centre where definitive surgery will be performed.

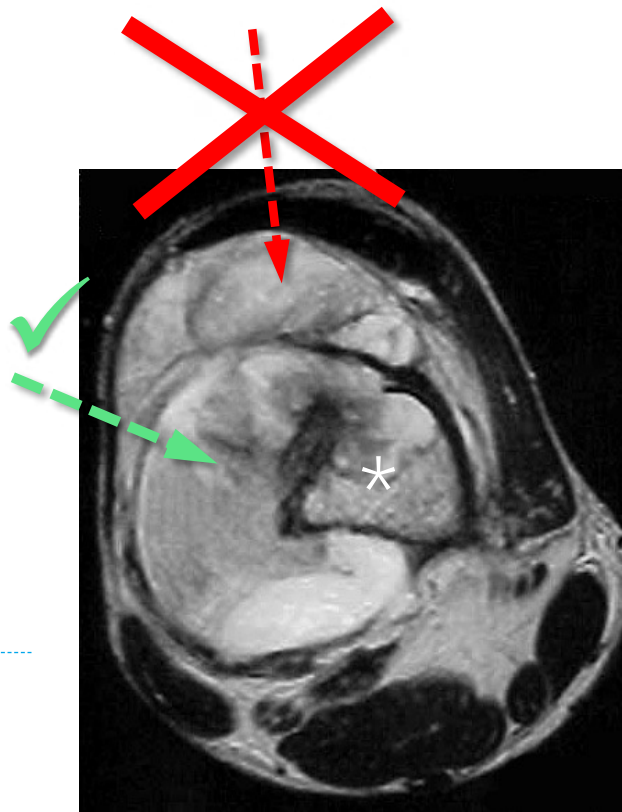
The **general principles for safe musculo-skeletal tumour biopsy** are (Figure 14):

- / Use the shortest path between skin and lesion
- / Avoid neurovascular and joint structures, lung, bowel, other organs
- / Needle path needs to be in the approximately same location where the incision for the definitive surgery will be made, so that the biopsy tract can be resected
- / Needle should not traverse an uninvolved or critical compartment, joint or neurovascular bundle

**FIGURE 14**

Axial MRI image. Femur (\*). The **biopsy tract** for this expansile destructive distal femoral lesion not only should use the shortest path from the skin but also needs to avoid the undue contamination of the knee extensor mechanism (*the red route*), which, if the red route is used, would have to be considered contaminated (by tumour seeding) and resected during definitive surgery. The green route is to be preferred.

<=> ATTENTION



## Musculo-skeletal Imaging

### CHAPTER OUTLINE:

#### Imaging Anatomy

Strengths, Weaknesses and Roles of Imaging Modalities

Arthropathies

Fractures and Dislocations

Infection

Tumours and Tumour-like Conditions

Metabolic Diseases

Developmental Abnormalities

Take-Home Messages

Suggested Reading and Sources

Test Your Knowledge



**CHAPTER OUTLINE:**

Imaging Anatomy

**Strengths, Weak-  
nesses and Roles of  
Imaging Modalities**

Arthropathies

Fractures and  
Dislocations

Infection

Tumours and Tumour-  
like Conditions

Metabolic Diseases

Developmental  
Abnormalities

Take-Home Messages

Suggested Reading  
and Sources

Test Your Knowledge

# / Strengths, Weaknesses and Roles of Imaging Modalities



# / The Concept of Resolution in Radiology

## CHAPTER OUTLINE:

Imaging Anatomy

## Strengths, Weaknesses and Roles of Imaging Modalities

/ Types of Resolution

Arthropathies

Fractures and Dislocations

Infection

Tumours and Tumour-like Conditions

Metabolic Diseases

Developmental Abnormalities


Take-Home Messages

Suggested Reading and Sources

Test Your Knowledge

There are three distinct types of resolution in radiology (Figure 15). Imaging modalities vary in their advantages on any given type of resolution.

### Spatial resolution




Ability to discern **closeness** in space of two adjacent pixels

Better:  
As small a pixel size as possible

Conventional radiographs and CT have excellent spatial resolution, which, however, is not equally matched with contrast resolution.

### Contrast resolution

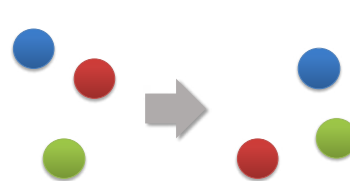


Ability to discern structural variations of different pixels

Better:  
As subtle a pixel variation as possible

MRI has excellent contrast resolution, which, however, is not usually equally matched with spatial resolution. US has very good contrast and spatial resolution.

### Temporal resolution



Ability to discern pixel differences over time

Better:  
As short a time period as possible

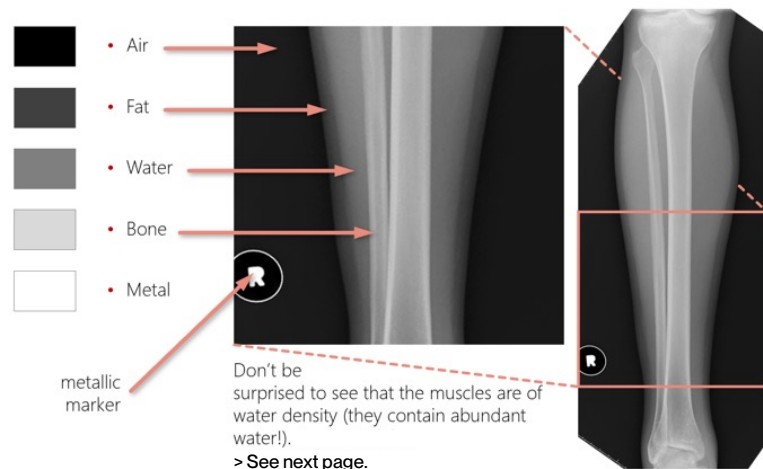
Especially important in dynamic contrast-enhanced studies. Digital angiography and real-time fluoroscopy have excellent temporal resolution.

FIGURE 15

Differences between spatial, contrast and temporal resolution.

# / Conventional Radiographs (CRX): Five Shades of Grey

Although not capable of giving cross-sectional information, radiographs are the **first-line imaging tool** in the MSK system. Radiographs feature five basic shades of grey, depending on the density (or X-ray attenuation) of the content imaged (**Figure 16**).



**FIGURE 16**

Basic grey shades on conventional radiographs (CRX).

## >|< COMPARE

### PROS

- + Easy
- + Inexpensive

### CONS

- Not cross-sectional
- Ionising radiation

### COSTS

Radiographs << US < CT < MRI

## <!> ATTENTION

Don't be surprised to see that muscles are of water density (they contain abundant water)!

Note that subcutaneous fat is of intermediate density between ambient air and muscles (mostly water), which makes sense, because fat is less dense than water, but denser than air.

## / Musculo-skeletal Imaging

### CHAPTER OUTLINE:

Imaging Anatomy

### Strengths, Weaknesses and Roles of Imaging Modalities

/ CRX

Arthropathies

Fractures and Dislocations

Infection

Tumours and Tumour-like Conditions

Metabolic Diseases

Developmental Abnormalities

Take-Home Messages


Suggested Reading and Sources

Test Your Knowledge

# / Conventional Radiography (CRX): A Chicken Soup of Five Shades of Grey

I poured into a paper cup first drinking water, then sunflower oil. I also put in a chicken bone. I covered the

partly filled cup with a metal lid. I then X-rayed the cup (Figure 17, centre). The resulting radiograph (Figure 17, right) displays densities of air, fat, water, bone and metal.



**FIGURE 17**

Basic grey shades on conventional radiography (CRX).

## / Musculo-skeletal Imaging

### CHAPTER OUTLINE:

Imaging Anatomy

**Strengths, Weaknesses and Roles of Imaging Modalities**

/ Gray Shades on CRX

Arthropathies

Fractures and Dislocations

Infection

Tumours and Tumour-like Conditions

Metabolic Diseases

Developmental Abnormalities

Take-Home Messages

Suggested Reading and Sources

Test Your Knowledge

I then made a CT scan of the same cup (**Figure 18**). CT, like CRX, utilises X-rays (i.e., features ionising radiation). Note that on CT image bone marrow is largely composed of fat. This information will be useful when we overview “lipohaemarthrosis”.

## &lt;=&gt; ATTENTION

**Musculo-skeletal Imaging****CHAPTER OUTLINE:**

Imaging Anatomy

**Strengths, Weaknesses and Roles of Imaging Modalities**

/ Gray Shades on CRX

Arthropathies

Fractures and Dislocations

Infection

Tumours and Tumour-like Conditions

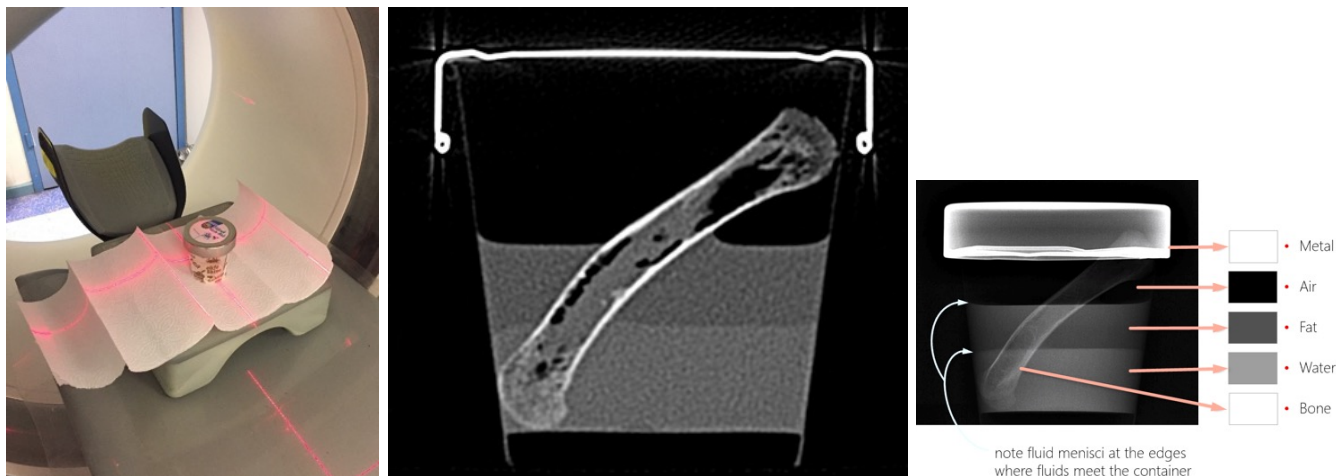
Metabolic Diseases

Developmental Abnormalities

Take-Home Messages

Suggested Reading and Sources

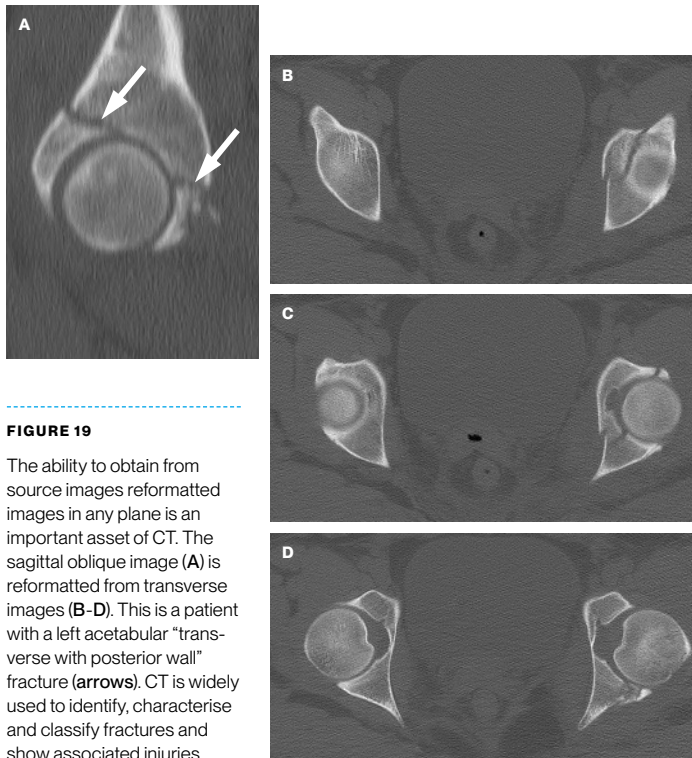
Test Your Knowledge

**FIGURE 18**

Basic grey shades on computed tomography (CT) and conventional radiography (CRX).

# / Computed Tomography (CT): Best to Characterise and Classify Fractures and Show Mineralisation

- / CT is widely used to identify, characterise and classify fractures (**Figure 19**).
- / Orthopaedic surgeons like to see three-dimensional CT representations of bone lesions that they might operate on (**Figure 20**).
- / CT is also used for guidance during bone biopsies and other interventional radiological procedures.
- / CT superbly demonstrates subtle calcifications in soft tissues or within the matrix of a bone lesion (**Figure 20**).



## >< COMPARE

### PROS

- + Great spatial resolution
- + Examination times are very short

### CONS

- Ionising radiation
- Contrast resolution is not as good as with MRI

## / Musculoskeletal Imaging

### CHAPTER OUTLINE:

Imaging Anatomy

### Strengths, Weaknesses and Roles of Imaging Modalities

/ CT

Arthropathies

Fractures and Dislocations

Infection

Tumours and Tumour-like Conditions

Metabolic Diseases

Developmental Abnormalities

Take-Home Messages

Suggested Reading and Sources

Test Your Knowledge

**Musculo-skeletal**  
Imaging**CHAPTER OUTLINE:**

Imaging Anatomy

**Strengths, Weaknesses and Roles of Imaging Modalities**

/ CT

Arthropathies

Fractures and Dislocations

Infection

Tumours and Tumour-like Conditions

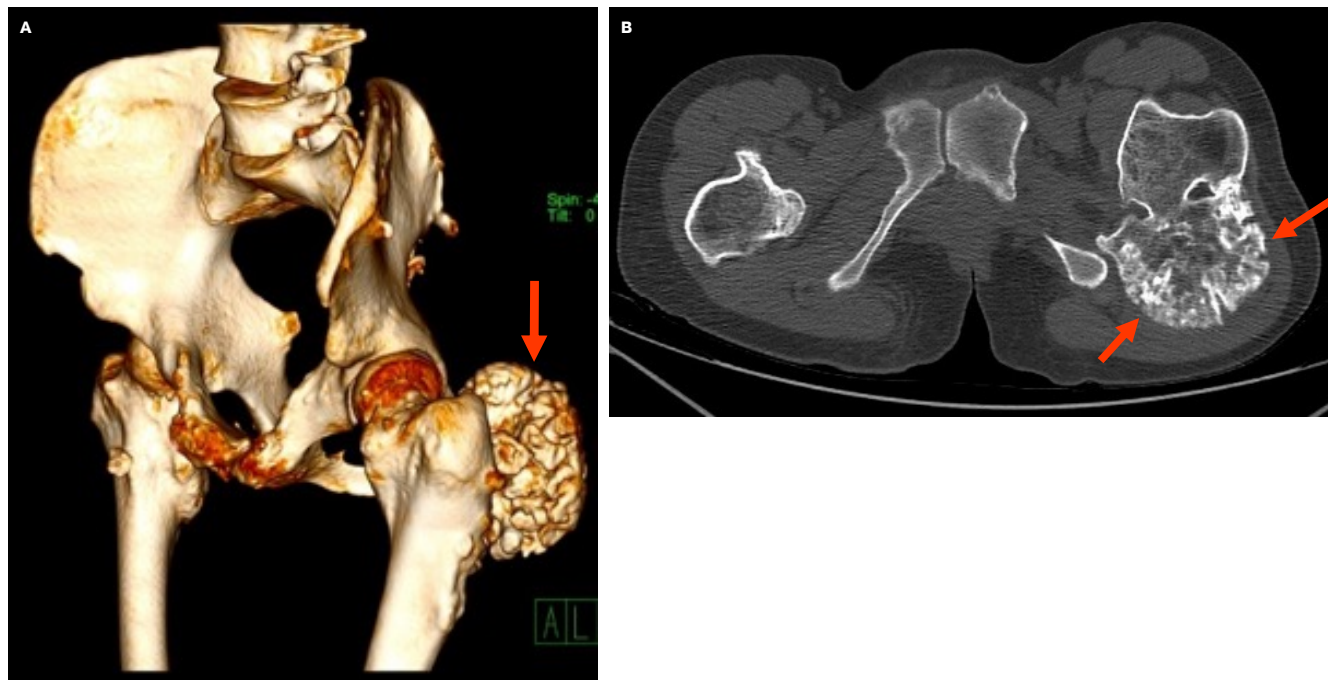
Metabolic Diseases

Developmental Abnormalities

Take-Home Messages

Suggested Reading and Sources

Test Your Knowledge

**FIGURE 20**

Three-dimensional rendering of bone lesions is another advantage of CT (A), enabling orthopaedic surgeons to better visualise what they will encounter during surgery as in this 23-year-old woman with osteo-chondromatosis (arrows). B is one of the source images.



# / Ultrasonography (US): Great Soft Tissue Detail, No Ionising Radiation

US is capable of giving real-time cross-sectional information without any ionising radiation and can be used for interventional procedures (Figures 21 and 22).

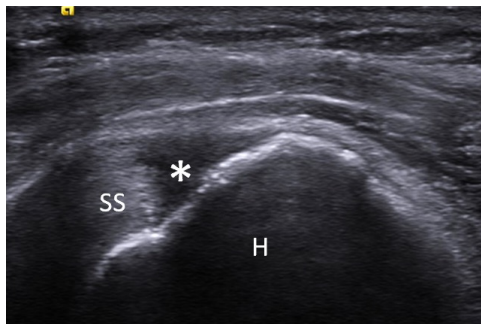
## >|< COMPARE

### PROS

- + Easy for the patient
- + Relatively inexpensive
- + No ionising radiation
- + Dynamic exam feasible
- + Doppler mode shows vascularity
- + Can be used for guidance in some procedures (e.g., soft tissue lesion biopsy, barbotage for calcific tendonitis)

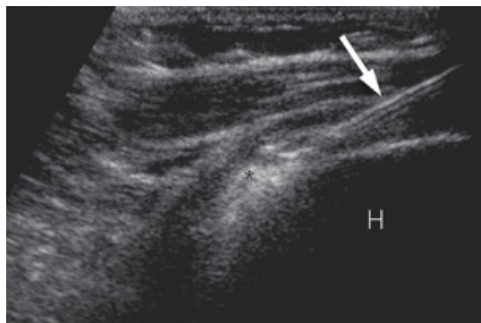
### CONS

- Does not show bones
- Deep soft tissues are usually beyond the scope of ultrasound probe for subtle lesions
- Operator-dependent
  - ^ This means that significant expertise is needed to be able to identify and characterise MSK soft tissues



**FIGURE 21**

Shoulder US shows a focal full-thickness tear (asterisk) of the supraspinatus (SS) tendon at its insertion near the humeral head (H).



**FIGURE 22**

US-guided barbotage for calcific tendonitis (asterisk) entails introduction and aspiration of physiologic saline through a needle (arrow) to disperse the calcific deposit. (H, humeral head).

## CHAPTER OUTLINE:

Imaging Anatomy

**Strengths, Weaknesses and Roles of Imaging Modalities**

/ Ultrasonography

Arthropathies

Fractures and Dislocations

Infection

Tumours and Tumour-like Conditions

Metabolic Diseases

Developmental Abnormalities

Take-Home Messages

Suggested Reading and Sources

Test Your Knowledge

Orthopaedic implant impingement on superficial soft tissues is exquisitely displayed on US (Figure 23).

CHAPTER OUTLINE:

Imaging Anatomy

**Strengths, Weaknesses and Roles of Imaging Modalities**

/ Ultrasonography

Arthropathies

Fractures and Dislocations

Infection

Tumours and Tumour-like Conditions

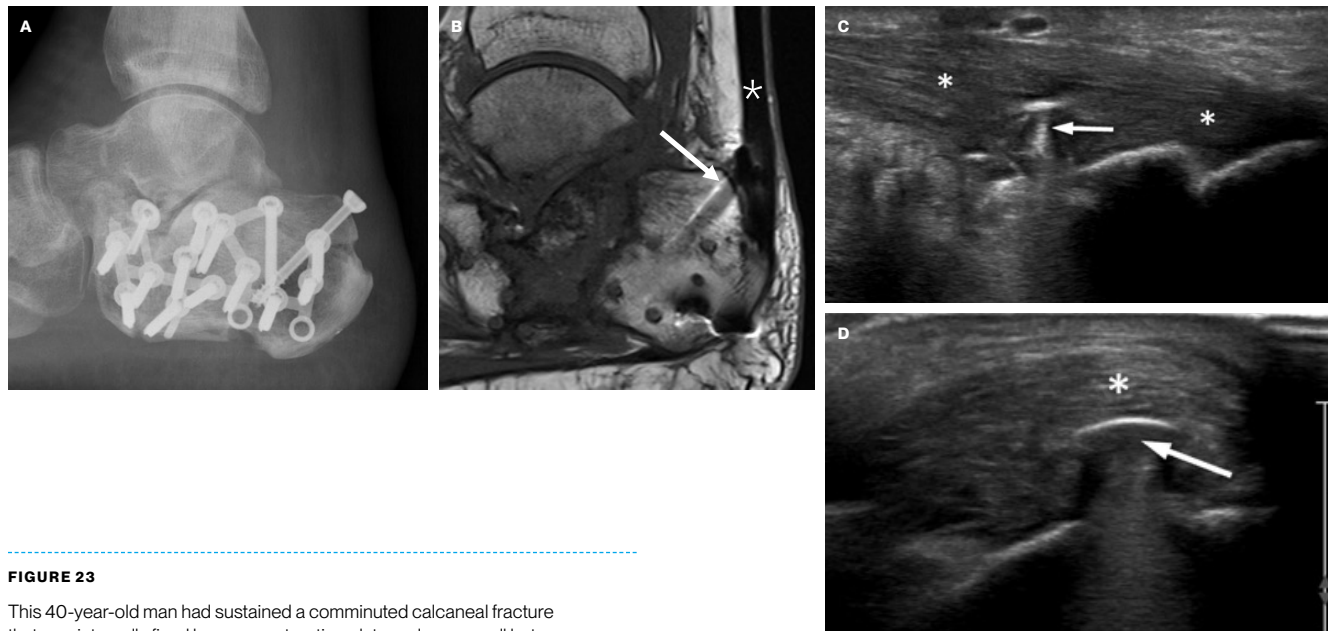
Metabolic Diseases

Developmental Abnormalities

Take-Home Messages

Suggested Reading and Sources

Test Your Knowledge



**FIGURE 23**

This 40-year-old man had sustained a comminuted calcaneal fracture that was internally fixed by a reconstruction plate and screws, all but one of which was later removed. Lateral CRX (A) before screw removal, sagittal MRI (B) and US images (C and D) after removal of all but one screw. The impingement of the remaining screw (arrows) upon the Achilles tendon (asterisks) was best demonstrated not on MRI (B) but on US images, which enabled precise measurement of the depth of intrusion.



# / Magnetic Resonance Imaging (MRI): An Excellent Tool for One-Stop Imaging of a Great Variety of Structures

MRI is widely used in most MSK problems. Its excellent contrast resolution covers soft tissues and bone marrow, making it an excellent tool for one-stop imaging of all MSK structures (Figure 24).

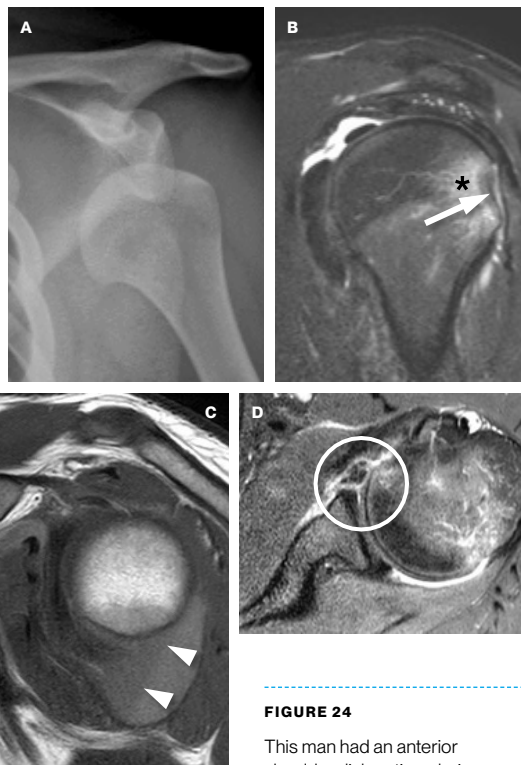
## >|< COMPARE

### PROS

- + Superb contrast resolution
- + No ionising radiation

### CONS

- Expensive
- Longer examinations than CT
- Not readily tolerated by some patients
- Not possible in some patients
- Subtle calcifications or small bone fragments might be missed



**FIGURE 24**

This man had an anterior shoulder dislocation, during which the posterolateral aspect of the humeral head smashes the anteroinferior part of the glenoid (CRX, A). MRI shows the resulting humeral head impaction fracture (B, arrow) with underlying bone marrow contusion (B, asterisk), shoulder haemarthrosis with layering of blood haematocrit (C, arrowheads) and the torn anterior glenoid labrum (D, circle).

## / Musculoskeletal Imaging

### CHAPTER OUTLINE:

Imaging Anatomy

**Strengths, Weaknesses and Roles of Imaging Modalities**

/ MRI

Arthropathies

Fractures and Dislocations

Infection

Tumours and Tumour-like Conditions

Metabolic Diseases

Developmental Abnormalities

Take-Home Messages

Suggested Reading and Sources

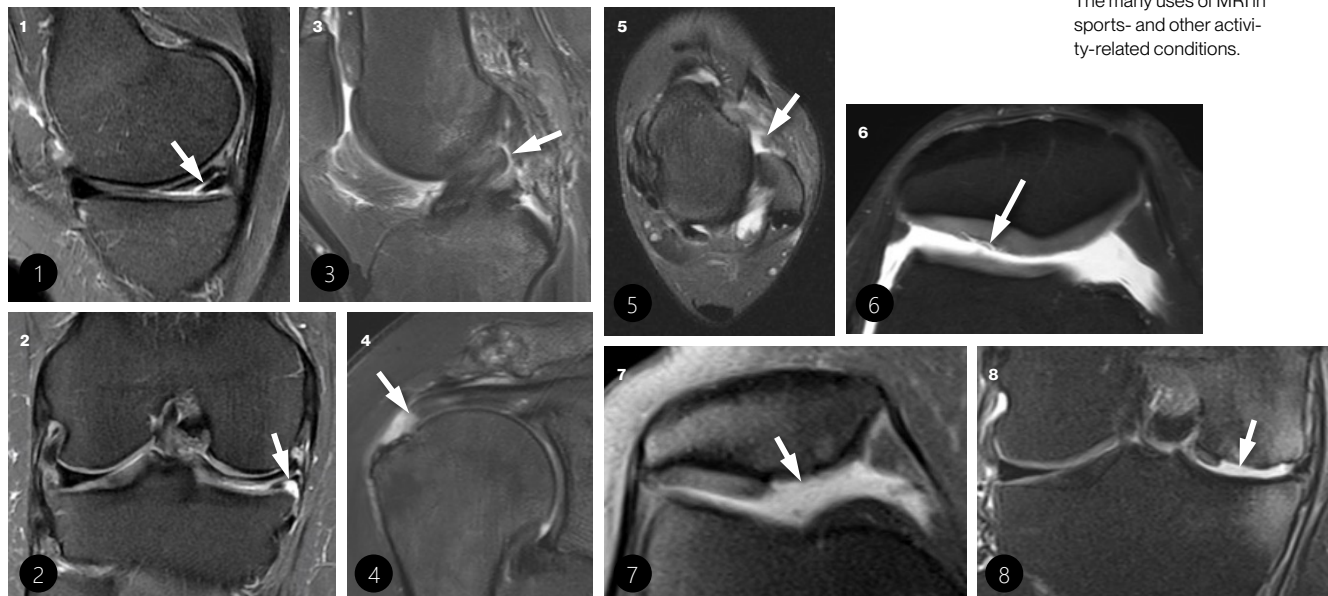
Test Your Knowledge

MRI is the most extensively used imaging modality to show such sports- and other activity-related injuries (**Figure 25, arrows**) as tears of the menisci (1, 2), anterior cruciate ligament (3), rotator cuff tendons (4), anterior talofibular ligament (5) and cartilage lesions ranging from superficial delamination (6) to

full-thickness loss (7, 8). Although US can also show some of these lesions at superficial locations (e.g., shoulder, ankle; see **Figure 21**), it can neither display as nicely many deeper-seated structures nor any co-existing bone marrow lesions—as does MRI.

**FIGURE 25**

The many uses of MRI in sports- and other activity-related conditions.



## Musculoskeletal Imaging

### CHAPTER OUTLINE:

Imaging Anatomy

### Strengths, Weaknesses and Roles of Imaging Modalities

/ MRI

Arthropathies

Fractures and Dislocations

Infection

Tumours and Tumour-like Conditions

Metabolic Diseases

Developmental Abnormalities

Take-Home Messages

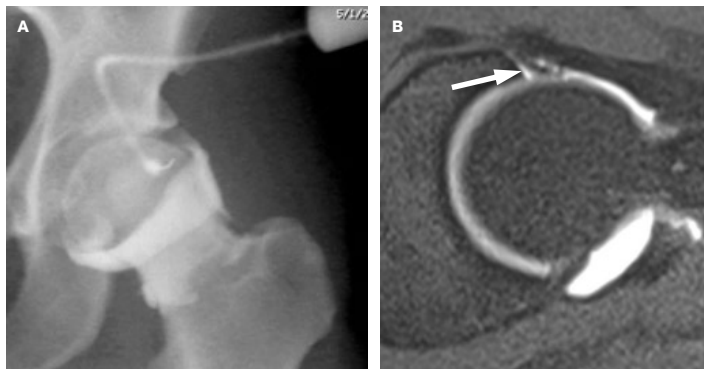
Suggested Reading and Sources

Test Your Knowledge

## / MR-/CT-Arthrography: A Special Method in MSK Imaging

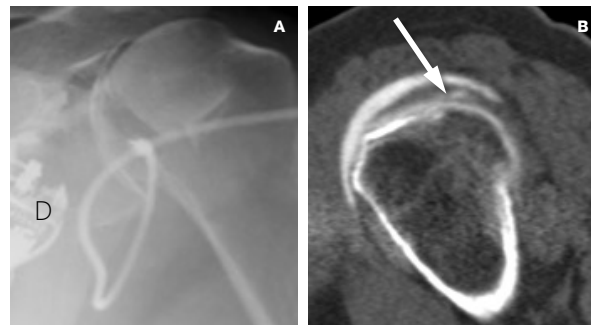
Cross-sectional imaging mostly with MRI (sometimes with CT) following intraarticular injection of contrast material is occasionally used to better delineate small structures within joints (**Figures 26 and 27**).

The injected contrast not only distends the joint space but also dilutes the joint fluid, making it possible for the otherwise somewhat viscous joint fluid to enter the nooks and crannies and disclose tears.



**FIGURE 26**

MR-arthrography (**B**) after intraarticular injection of contrast material into the left hip joint under fluoroscopy guidance (**A**) showed a tear at the base of the anterior acetabular labrum (**arrow**).



**FIGURE 27**

This patient had a cardiac defibrillator (**D**) and could not undergo MRI. Injection of contrast material under fluoroscopic guidance (**A**) and CT-arthrography (**B**) showed a tear (**arrow**) of the infrapatellar tendon filling with the intraarticularly injected contrast material.

### / Musculo- skeletal Imaging

#### CHAPTER OUTLINE:

Imaging Anatomy

**Strengths, Weak-  
nesses and Roles of  
Imaging Modalities**

/ MR-/CT-  
Arthrography

Arthropathies

Fractures and  
Dislocations

Infection

Tumours and Tumour-  
like Conditions

Metabolic Diseases

Developmental  
Abnormalities

Take-Home Messages

Suggested Reading  
and Sources

Test Your Knowledge

**CHAPTER OUTLINE:**

Imaging Anatomy

Strengths, Weaknesses  
and Roles of Imaging  
Modalities

**Arthropathies**

Fractures and  
Dislocations

Infection

Tumours and Tumour-  
like Conditions

Metabolic Diseases

Developmental  
Abnormalities

Take-Home Messages

Suggested Reading  
and Sources

Test Your Knowledge

# / Arthropathies

## CHAPTER OUTLINE:

Imaging Anatomy

Strengths, Weaknesses  
and Roles of Imaging  
Modalities

## Arthropathies

Fractures and  
Dislocations

Infection

Tumours and Tumour-  
like Conditions

Metabolic Diseases

Developmental  
Abnormalities

Take-Home Messages

Suggested Reading  
and Sources

Test Your Knowledge

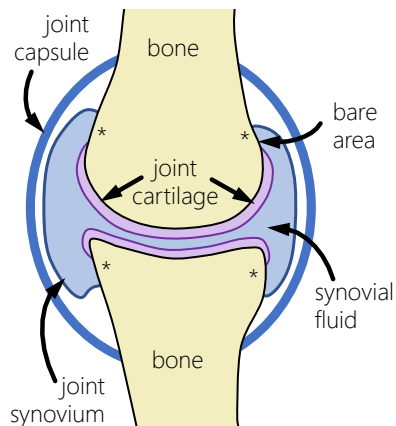
## General Principles

One of the main tasks while dealing with arthropathy in a patient is to decide whether it is degenerative (e.g., osteoarthritis) or inflammatory (e.g.,

rheumatoid arthritis). Pathophysiologic mechanisms and therefore imaging findings in these two main conditions are quite different (**Figure 28**).

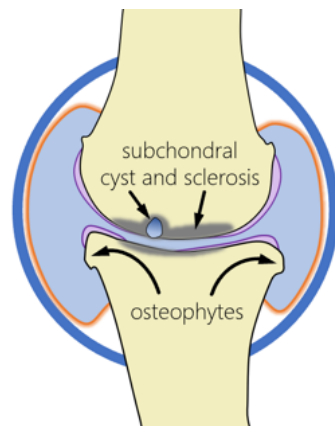
## Normal joint

Bare areas of the bone (\*) are within the joint space but not covered with joint cartilage.



## Osteoarthritis

Bones rub against each other with non-uniform loss of joint cartilage. Osteophytes attempt to stabilise the joint. Subchondral sclerosis is a stress response to cartilage loss and mechanical imbalance. Cysts may occur.



## Rheumatoid arthritis

Synovial inflammation first erodes bare areas and later expands inside and outside the joint. As the disease progresses, the loss of joint cartilage is usually uniform, resulting in an evenly narrowed joint space on radiographs.

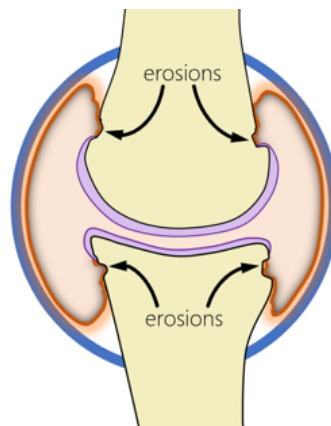


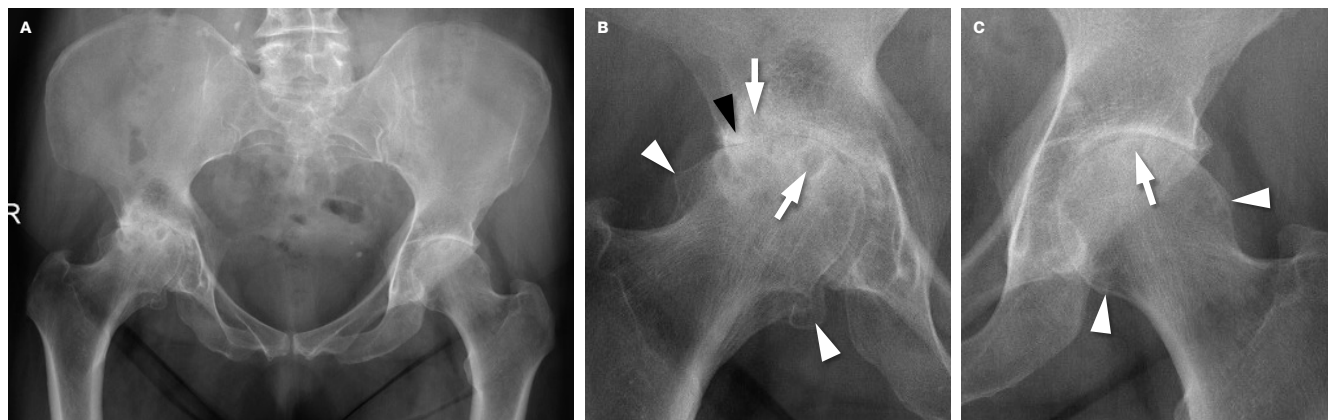
FIGURE 28

Schematic illustration of the differences between osteoarthritis and rheumatoid arthritis.

# / Osteoarthritis: The Hallmark of Degenerative Joint Disease

**Osteoarthritis** is the most common joint disease. Characteristic radiographic features (**Figure 29**) are asymmetric (non-uniform) joint space narrowing (due to joint cartilage loss) with osteophytes, bone

sclerosis and subchondral cysts in the absence of such inflammatory features as erosions. Synovitis and osteitis, however, can be seen in osteoarthritis..



**FIGURE 29**

Anteroposterior radiograph showing right > left hip osteoarthritis in a 64-year-old woman (hips enlarged in **B** and **C**). Characteristic features include non-uniform narrowing of the joint space, subchondral sclerosis (**black arrowhead**) and cysts (**arrows**) and marginal osteophytes (**white arrowheads**).

## CHAPTER OUTLINE:

Imaging Anatomy

Strengths, Weaknesses  
and Roles of Imaging  
Modalities

## Arthropathies

/ Osteoarthritis

Fractures and  
Dislocations

Infection

Tumours and Tumour-  
like Conditions

Metabolic Diseases

Developmental  
Abnormalities

Take-Home Messages

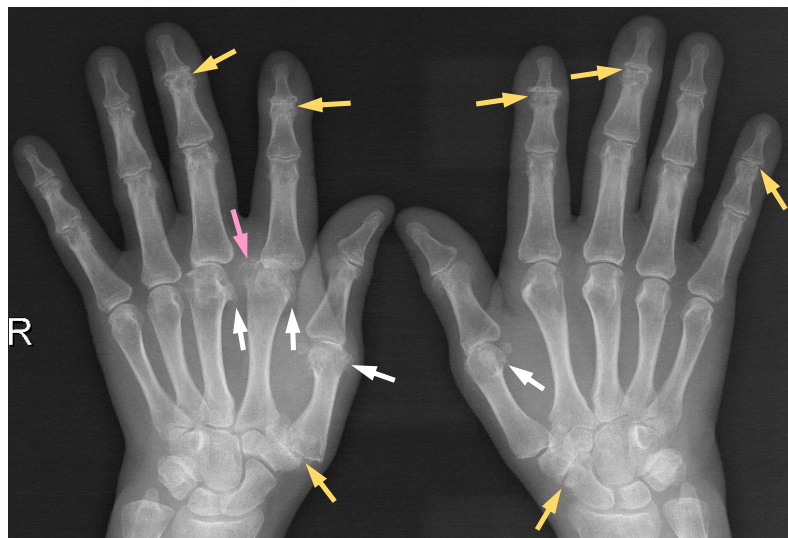
Suggested Reading  
and Sources

Test Your Knowledge

# / Osteoarthritis: Primary and Secondary

**Primary (idiopathic) osteoarthritis** is the more common form of the disease and occurs without a prior insult (**Figure 30**), which is the characteristic of secondary osteoarthritis. Crystal deposition, inflammatory arthritis and other synovial disease,

trauma, infection, developmental dysplasia and impingement syndromes can all lead to **secondary osteoarthritis** (**Figures 31 and 32**), whereby imaging can help establish the background.



## <=> ATTENTION

Bones in the hands, wrists, feet and ankles make up slightly more than half of all bones in the human body and the respective joints account for one third of all our articulations. It should therefore come as no surprise that distal aspects of our extremities are extensively examined in the work-up of arthritis.

**FIGURE 30**

Primary osteoarthritis manifestations in a 59-year old woman include non-uniform narrowing, subchondral cysts and marginal osteophytes at the distal interphalangeal, first carpometacarpal and scaphoid-trapezium joints (**yellow arrows**). Secondary osteoarthritis in the form of calcium pyrophosphate dihydrate deposition (CPPD) arthropathy is also evident at the right second and third and left first metacarpophalangeal (MCP) joints with hook osteophytes in the distal metacarpals (**white arrows**) and right second MCP joint cartilage calcification (**pink arrow**).

## / Musculoskeletal Imaging

### CHAPTER OUTLINE:

Imaging Anatomy

Strengths, Weaknesses and Roles of Imaging Modalities

### Arthropathies

/ Osteoarthritis

Fractures and Dislocations

Infection

Tumours and Tumour-like Conditions

Metabolic Diseases

Developmental Abnormalities

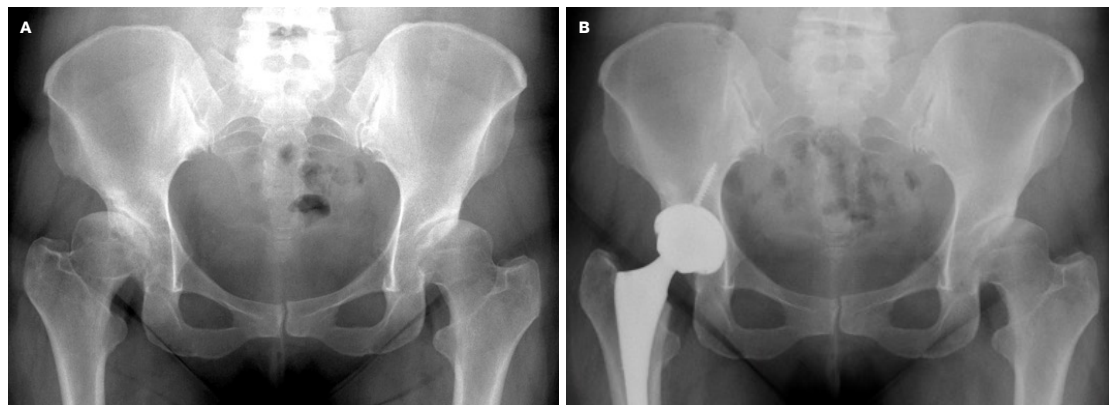
Take-Home Messages

Suggested Reading and Sources

Test Your Knowledge

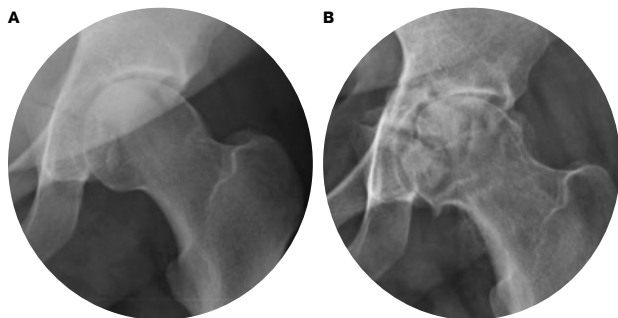


## Osteoarthritis: Secondary



**FIGURE 31**

Right hip osteoarthritis (A) in this 41-year-old woman resulted from untreated developmental dysplasia of the hip (DDH). She ended up undergoing a total right hip replacement surgery (B). She has DDH also on the left side, which, too, is on track for secondary osteoarthritis.



**FIGURE 32**

An acetabular fracture (A) after a motor vehicle accident in this 25-year-old woman resulted in left hip osteoarthritis (B) within 7 months. She was pregnant at the time of her injury and declined surgery.

## Musculo-skeletal Imaging

### CHAPTER OUTLINE:

#### Imaging Anatomy

#### Strengths, Weaknesses and Roles of Imaging Modalities

#### Arthropathies

##### / Osteoarthritis

#### Fractures and Dislocations

#### Infection

#### Tumours and Tumour-like Conditions

#### Metabolic Diseases

#### Developmental Abnormalities

#### Take-Home Messages

#### Suggested Reading and Sources

#### Test Your Knowledge



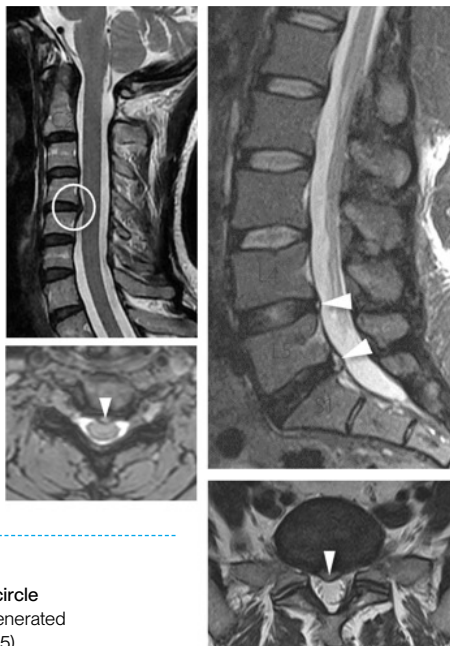
# / Degenerative Disease of the Spine: Bones and Discs

Degenerative diseases of the intervertebral discs are usually in the form of **intervertebral osteochondrosis (Figures 33 and 34)**, which originates from

the nucleus pulposus and **spondylosis deformans (Figure 34)**, which starts in the outer fibres of annulus fibrosus. **Facet joints** can also have osteoarthritis.

MRI is extensively used in the diagnosis of disc herniation, which is usually associated with **low back or neck pain** (both of which are among the most common complaints in adults).

The terms disc bulge, protrusion (Figure 33), extrusion, migration and sequestration on MRI reports all have specific meanings.



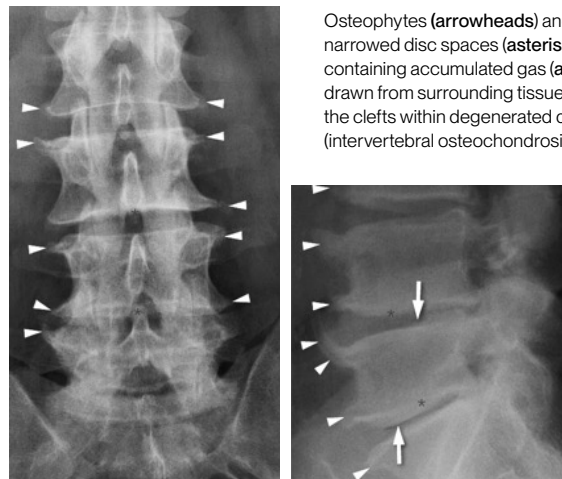
**FIGURE 33**

MRI shows protrusions (circle and arrowheads) of degenerated discs (C4–5, L5–S1>L4–5).

“Traction” osteophytes in spondylosis deformans (Figure 34) are characteristically transverse or oblique in orientation. They occur secondary to chronic traction of Sharpey fibres (at the periphery of the annulus fibrosus), which are stretched by the bulging disc.

**FIGURE 34**

Osteophytes (arrowheads) and narrowed disc spaces (asterisks) containing accumulated gas (arrows) drawn from surrounding tissues into the clefts within degenerated disks (intervertebral osteochondrosis).



## CHAPTER OUTLINE:

Imaging Anatomy

Strengths, Weaknesses and Roles of Imaging Modalities

## Arthropathies

/ Degenerative Spine Disease

Fractures and Dislocations

Infection

Tumours and Tumour-like Conditions

Metabolic Diseases

Developmental Abnormalities

Take-Home Messages

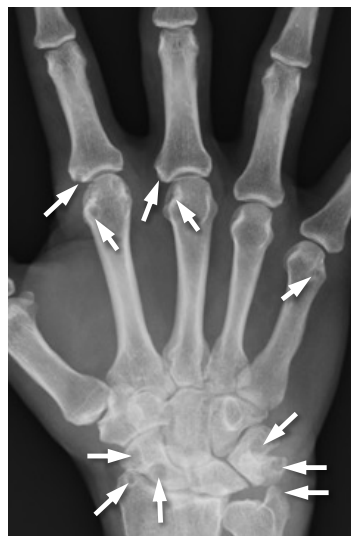Suggested Reading and Sources

Test Your Knowledge

# / Rheumatoid Arthritis (RA): The Hallmark of Inflammatory Arthritis

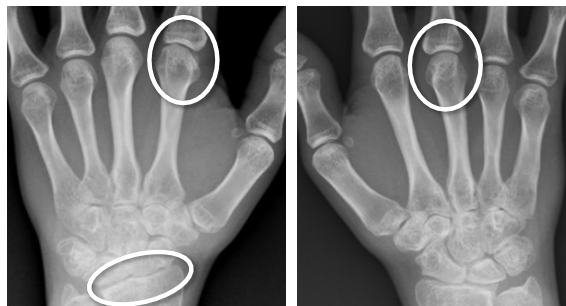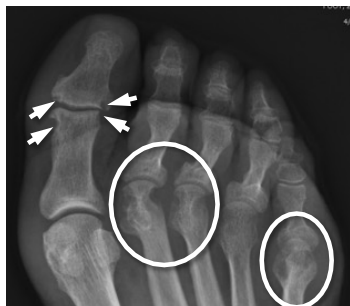**Characteristic radiographic findings** of rheumatoid arthritis (RA) include uniform narrowing of the joint space, erosions starting from the bare areas and periarticular osteopenia. Common places to

look for erosions are hands, wrists and feet – especially the radial aspects of the second and third metacarpophalangeal (MCP) joints and the ulnar aspect of the fifth MCP joint (**Figures 35 and 36**).



**FIGURE 35**

Hand-wrist and foot radiographs showing characteristic erosions (arrows and ellipses) and mild uniform narrowing of joints in two patients with rheumatoid arthritis.



## >< FURTHER KNOWLEDGE

**FIGURE 36**

Radiographic findings of rheumatoid arthritis can be subtle as in this 22-year-old woman with narrowing of the second MCP joint and radiocarpal joint on one side (ellipses, left) and the third MCP joint on the other side (ellipse, right). No erosions are visible.

### CHAPTER OUTLINE:

Imaging Anatomy

Strengths, Weaknesses  
and Roles of Imaging  
Modalities

### Arthropathies

/ Rheumatoid Arthritis

Fractures and  
Dislocations

Infection

Tumours and Tumour-  
like Conditions

Metabolic Diseases

Developmental  
Abnormalities

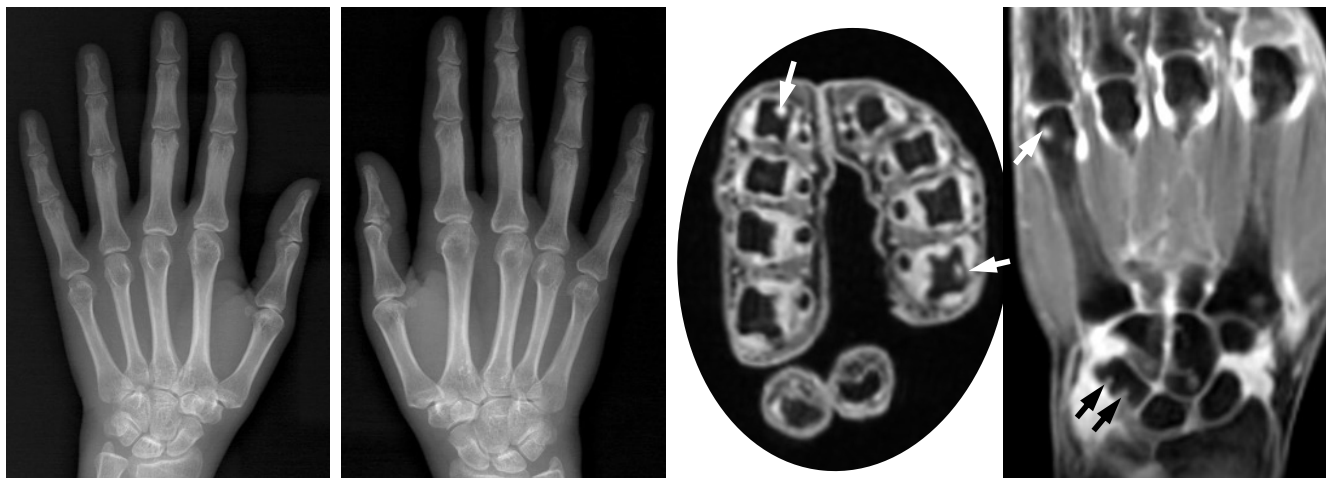Take-Home Messages

Suggested Reading  
and Sources

Test Your Knowledge

## &lt;=&gt; ATTENTION

Contrast-enhanced MRI is capable of detecting joint involvement in RA in the absence of radiographic signs on CRX (Figure 37).



**FIGURE 37**

Wrist pansynovitis, extensive MCP joint synovitis and flexor tenosynovitis manifesting as extensive enhancement on contrast enhanced MRI (centre and right) in a 48-year-old woman with RA. Note also erosions (**arrows**). Her CRX (left) is unremarkable.

## Musculo-skeletal Imaging

### CHAPTER OUTLINE:

Imaging Anatomy

Strengths, Weaknesses  
and Roles of Imaging  
Modalities

### Arthropathies

/ Rheumatoid Arthritis

Fractures and  
Dislocations

Infection

Tumours and Tumour-  
like Conditions

Metabolic Diseases

Developmental  
Abnormalities

Take-Home Messages

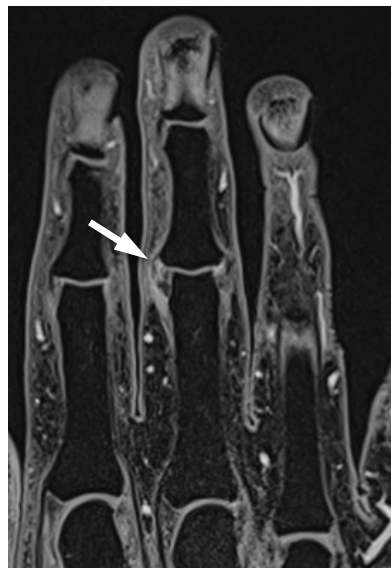
Suggested Reading  
and Sources

Test Your Knowledge

# / Common and Distinctive Imaging Features of Seropositive and Seronegative Arthritis

Some features are common to both seropositive (e.g., RA) and seronegative (e.g., psoriatic arthritis [PsA]) arthritis: soft tissue swelling, synovitis or tenosynovitis, erosions and osteitis. **Enthesitis and bone**

**proliferation**, however, are almost exclusively seen in seronegative spondyloarthritis. A small portion of cases with RA are seronegative. **Figures 38 and 39** illustrate MRI features of seronegative arthritis.



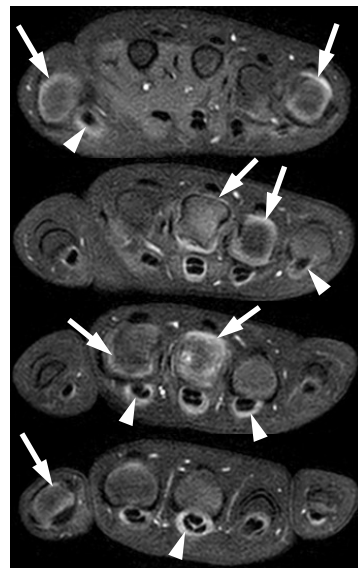
	Seronegative	Seropositive
Soft tissue swelling	+	+
Synovitis/tenosynovitis	+	+
Erosions	+	+
Osteitis	+	+
Enthesitis	+	
Bone proliferation	+	
	PsA	RA

**FIGURE 38**

Enthesitis at the capsular attachments of the third proximal interphalangeal joint (arrow) is exquisitely depicted as the earliest imaging finding of seronegative arthritis on this MR image of a 29-year-old woman with psoriasis

**FIGURE 39**

First through fifth metacarpophalangeal and right first interphalangeal joint synovitis (arrows) and first through fifth flexor tenosynovitis (arrowheads) are seen on MRI of this 8-year-old girl with seronegative juvenile idiopathic arthritis.



## / Musculoskeletal Imaging

### CHAPTER OUTLINE:

Imaging Anatomy

Strengths, Weaknesses and Roles of Imaging Modalities

### Arthropathies

/ Seropositive vs. Seronegative Arthritis

Fractures and Dislocations

Infection

Tumours and Tumour-like Conditions

Metabolic Diseases

Developmental Abnormalities

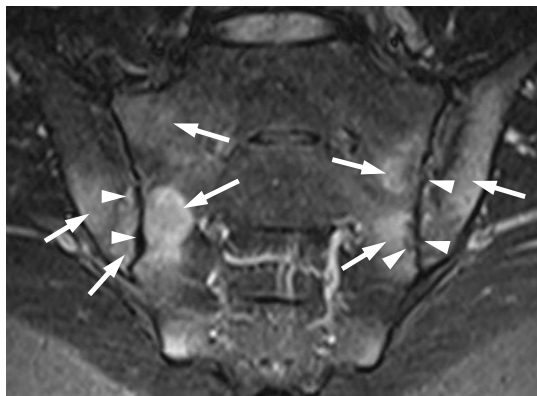
Take-Home Messages

Suggested Reading and Sources

Test Your Knowledge

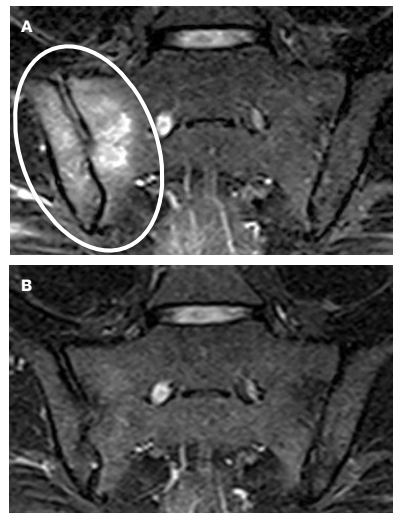
# / Periarticular Osteitis on Sacroiliac Joint MRI: A Major Finding for Diagnosing Axial Spondyloarthritis

Periarticular bone marrow edema/osteitis on MRI (Figures 40 and 41) is one of the cardinal features for diagnosing axial spondyloarthritis in patients with inflammatory type back pain  $\geq 3$  months and age at onset  $< 45$  years. Axial spondyloarthritis is a complex immune-mediated health condition with characteristic clinical features such as enthesitis, sacroiliitis and spondylitis, and extraarticular manifestations such as anterior uveitis, psoriasis and inflammatory bowel disease.



**FIGURE 40**

Bilateral periarticular bone marrow oedema (arrows) and iliac>sacral-sided periarticular erosions (arrowheads) are characteristic of acute on chronic sacroiliitis in this 28-year-old man with ankylosing spondylitis.



**FIGURE 41**

Periarticular bone marrow oedema denoting active sacroiliitis on the right (ellipse, A) has resolved following treatment (B) in this 33-year-old man with ankylosing spondylitis.

## CHAPTER OUTLINE:

Imaging Anatomy

Strengths, Weaknesses  
and Roles of Imaging  
Modalities

## Arthropathies

/ Axial  
Spondyloarthritis

Fractures and  
Dislocations

Infection

Tumours and Tumour-  
like Conditions

Metabolic Diseases

Developmental  
Abnormalities

Take-Home Messages

Suggested Reading  
and Sources

Test Your Knowledge



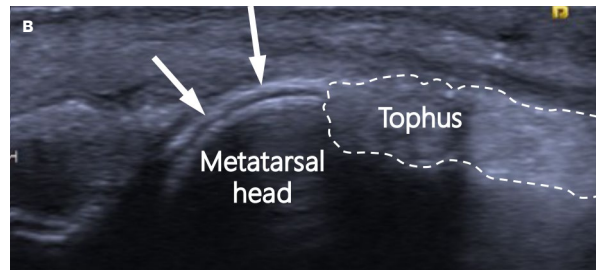
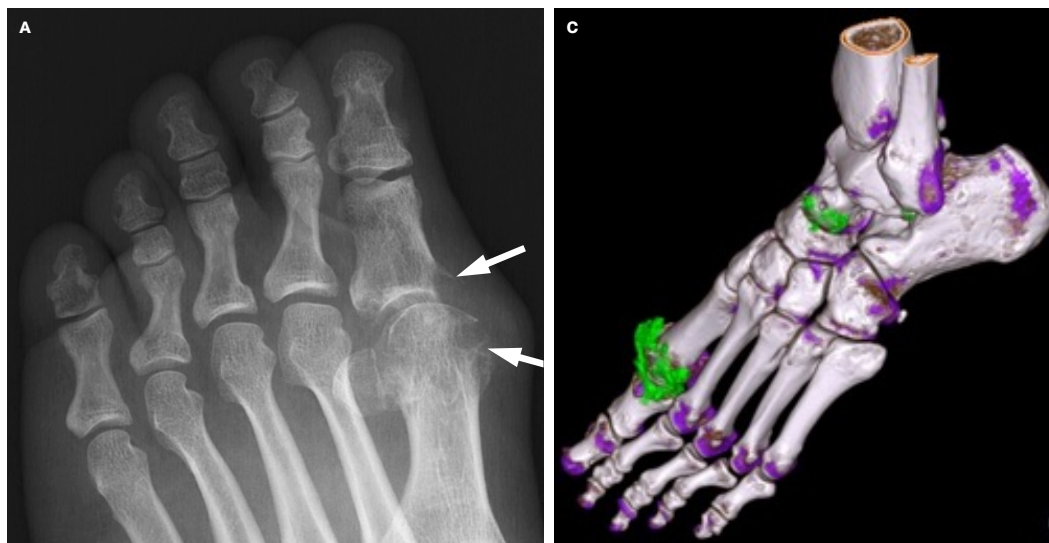
# / Gout: The Hallmark of Metabolic Arthritis

Monosodium urate crystal deposition within joints and surrounding soft tissues (including tendons and bursae) in gout results in some characteristic imaging findings as shown in **Figures 42 and 43**.

## <=> ATTENTION

**FIGURE 42**

Punched out erosions with overhanging edges (arrows, **A**) surrounding the first metatarsophalangeal joint along with preservation of joint space width are characteristic of gout in this 58-year-old man. "Double contour" sign in a sagittal US image (**B**) denotes crystal deposition across the joint cartilage surface (arrows). Dual-energy CT (**C**) accurately depicts monosodium urate crystals (green) and is useful for disease quantification in the follow-up.



## / Musculoskeletal Imaging

### CHAPTER OUTLINE:

Imaging Anatomy

Strengths, Weaknesses and Roles of Imaging Modalities

### Arthropathies

/ Metabolic Arthritis

Fractures and Dislocations

Infection

Tumours and Tumour-like Conditions

Metabolic Diseases

Developmental Abnormalities

Take-Home Messages

Suggested Reading and Sources

Test Your Knowledge

## CHAPTER OUTLINE:

Imaging Anatomy

Strengths, Weaknesses  
and Roles of Imaging  
Modalities

## Arthropathies

/ Metabolic Arthritis

Fractures and  
Dislocations

Infection

Tumours and Tumour-  
like Conditions

Metabolic Diseases

Developmental  
Abnormalities

Take-Home Messages

Suggested Reading  
and Sources

Test Your Knowledge

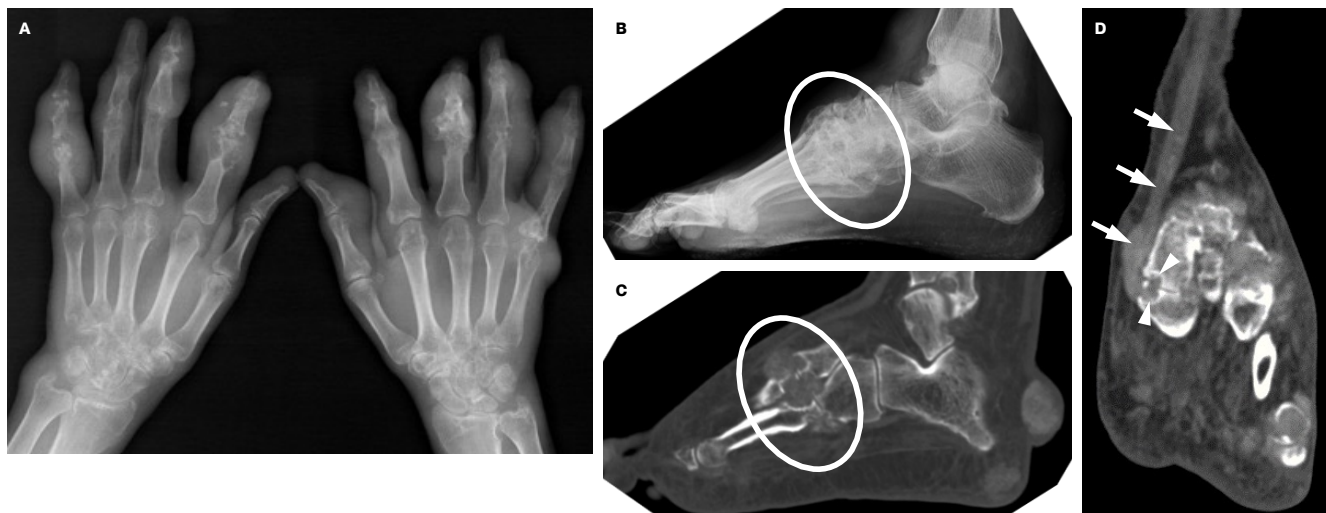

FIGURE 43

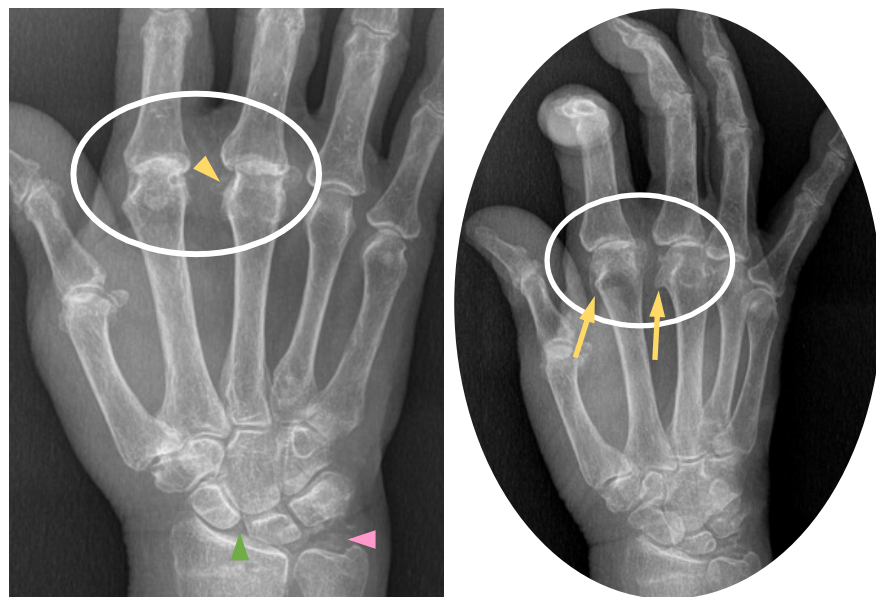
Lumpy-bumpy appearance due to tophi around joints and periarticular erosions with overhanging edges (A), tarsometatarsal joint erosions (ellipses and arrowheads) on foot radiograph (B) and CT (C and D) are typical imaging findings of gout. Note the distal tophus along the anterior tibial tendon (arrows).



## Calcium Pyrophosphate Dihydrate (CPPD) Arthropathy

Although gout is considered as the hallmark of metabolic arthritis, CPPD is more common than gout, given the fact that it is usually seen in an older age group and that humans have increased longevity. In fact, CPPD arthropathy is more common than rheumatoid

arthritis – and second, in frequency, only to osteoarthritis. Characteristic findings are shown in **Figure 44**.



**FIGURE 44**

CPPD arthropathy in a 94-year old woman. Second and third metacarpophalangeal (MCP) joint arthritis (ellipses), hook osteophytes along radial aspects of second and third distal metacarpals (arrows), calcification at the triangular fibrocartilage (pink arrowhead), scapholunate ligament (green arrowhead) and third MCP joint cartilage (yellow arrowhead).

### >=< FURTHER KNOWLEDGE

Interestingly, CPPD arthropathy can present without visible calcifications within joints. Involvement of the characteristic locations (MCP joints and radiocarpal compartment, both of which are unusual locations for primary osteoarthritis) along with second and third distal metacarpal hook osteophytes in a patient >50 years would be clues to CPPD arthropathy, even in the absence of intraarticular calcifications on imaging.

## Musculoskeletal Imaging

### CHAPTER OUTLINE:

Imaging Anatomy

Strengths, Weaknesses and Roles of Imaging Modalities

### Arthropathies

/ Metabolic Arthritis

Fractures and Dislocations

Infection

Tumours and Tumour-like Conditions

Metabolic Diseases

Developmental Abnormalities

Take-Home Messages

Suggested Reading and Sources

Test Your Knowledge

# / An Algorithm for Imaging Diagnosis of Arthropathies

The algorithm shown in **Figure 45** can be used for imaging diagnosis of arthritis. It is not without shortcomings, however, and some of the exceptions are given in **Figure 46**.

## CHAPTER OUTLINE:

Imaging Anatomy

Strengths, Weaknesses  
and Roles of Imaging  
Modalities

## Arthropathies

/ An Imaging Algorithm

Fractures and  
Dislocations

Infection

Tumours and Tumour-  
like Conditions

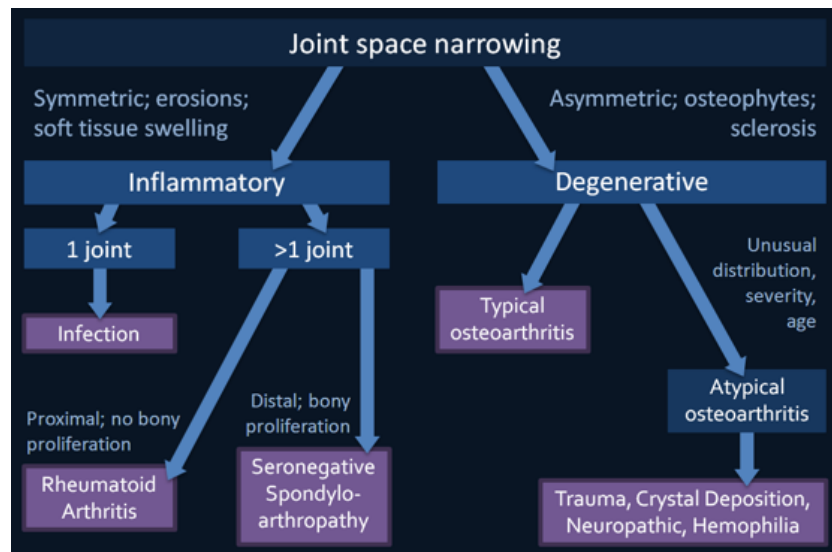
Metabolic Diseases

Developmental  
Abnormalities

Take-Home Messages

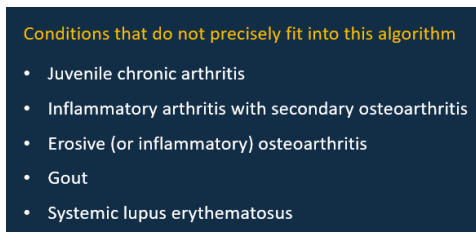
Suggested Reading  
and Sources

Test Your Knowledge



**FIGURE 45**

Adapted from Jacobson JA et al. Radiology 2008.



**FIGURE 46**

Exceptions to the algorithm shown in **Figure 41**.

**CHAPTER OUTLINE:**

Imaging Anatomy

Strengths, Weaknesses  
and Roles of Imaging  
Modalities

Arthropathies

**Fractures and  
Dislocations**

Infection

Tumours and Tumour-  
like Conditions

Metabolic Diseases

Developmental  
Abnormalities

Take-Home Messages

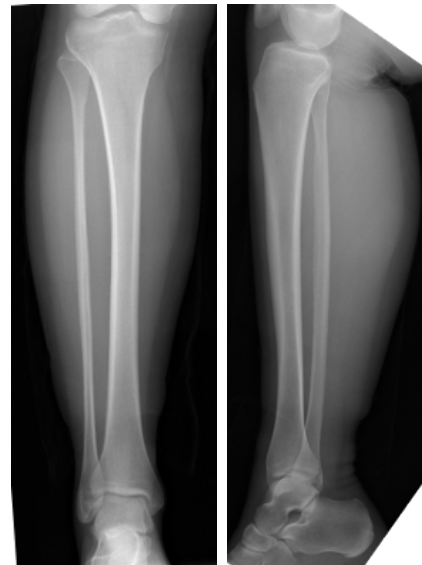Suggested Reading  
and Sources

Test Your Knowledge

# / Fractures and Dislocations

# / Basic Principles in Imaging Fractures and Dislocations

- / **More than one radiographic projection** is needed for any part of the body.
- / Although radiographs are the first-line imaging tool to look for fractures and/or dislocations, CT is more appropriate in body parts with complex anatomy (e.g., face, thoracic cage, pelvis).
- / **Two radiographic projections** perpendicular to each other need to be used for extremity segments (i.e., arm, forearm, thigh and calf; **Figure 47**).
- / **Three radiographic projections** (anteroposterior/postero-anterior, lateral, oblique) are recommended for most joints (e.g., wrist, hand, ankle, foot).
- / Stress radiographs (e.g., scaphoid view for suspected fracture of this wrist bone) or additional projections (e.g., axillary view and/or Y-view in the shoulder) can be used in some joints and certain conditions.
- / Radiographs need to cover the joints adjacent to a long bone (**Figure 47**); if a single X-ray detector plate does not suffice to include joints at both ends, two acquisitions are needed for each projection.
- / Due to the ongoing ossification in children, comparative radiographs



**FIGURE 47**

Normal anteroposterior and lateral CRX of the calf.

### CHAPTER OUTLINE:

Imaging Anatomy

Strengths, Weaknesses and Roles of Imaging Modalities

Arthropathies

**Fractures and Dislocations**

/ Basic Principles

Infection

Tumours and Tumour-like Conditions

Metabolic Diseases

Developmental Abnormalities

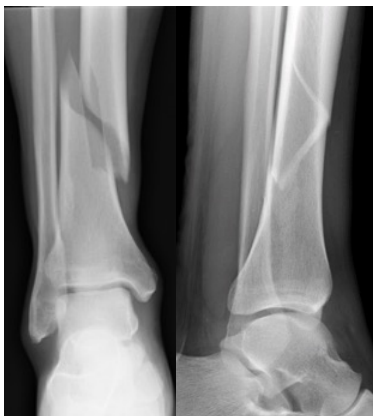Take-Home Messages

Suggested Reading and Sources

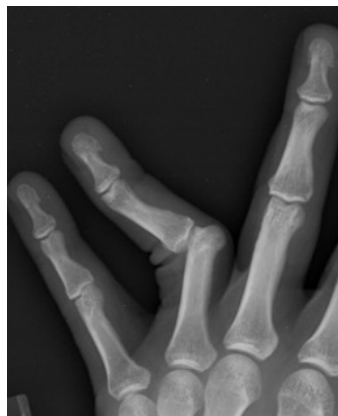Test Your Knowledge

# / Describing Fractures and Dislocations on Imaging

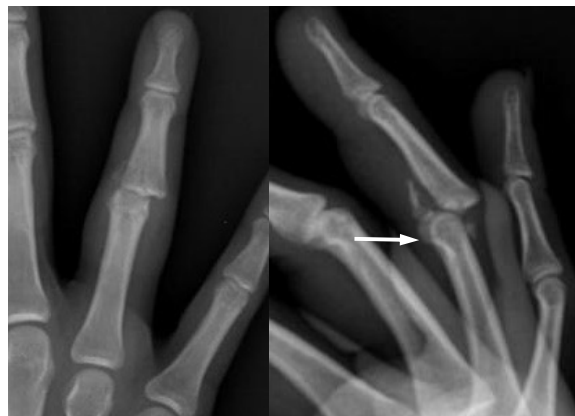- / Fractures are commonly described according to the **location/alignment** of the DISTAL aspect of the major DISTAL fracture fragment (displaced or non-displaced, angulated, rotated; **Figure 48**).
- / **Dislocation** is an injury resulting in loss of anatomical congruence of bones at a joint (**Figure 49**).
- / **Subluxation** refers to an incomplete dislocation where joint surfaces remain partially facing each other (**Figure 50**).
- / Joint dislocations (and subluxations) are usually described in terms of the **position** of the distal bone in relation to the proximal bone.

**FIGURE 48**

Spiral fracture of the distal tibial diaphysis with mild lateral and minimal posterior displacement.

**FIGURE 49**

Medial and dorsal dislocation of the fourth PIP joint (arrow).

**FIGURE 50**

Medial and dorsal subluxation of the fourth proximal interphalangeal (PIP) joint with a comminuted intraarticular fracture of the middle phalangeal base.

**CHAPTER OUTLINE:**

Imaging Anatomy

Strengths, Weaknesses and Roles of Imaging Modalities

Arthropathies

**Fractures and Dislocations**

/ Describing Fractures

Infection

Tumours and Tumour-like Conditions

Metabolic Diseases

Developmental Abnormalities

Take-Home Messages

Suggested Reading and Sources

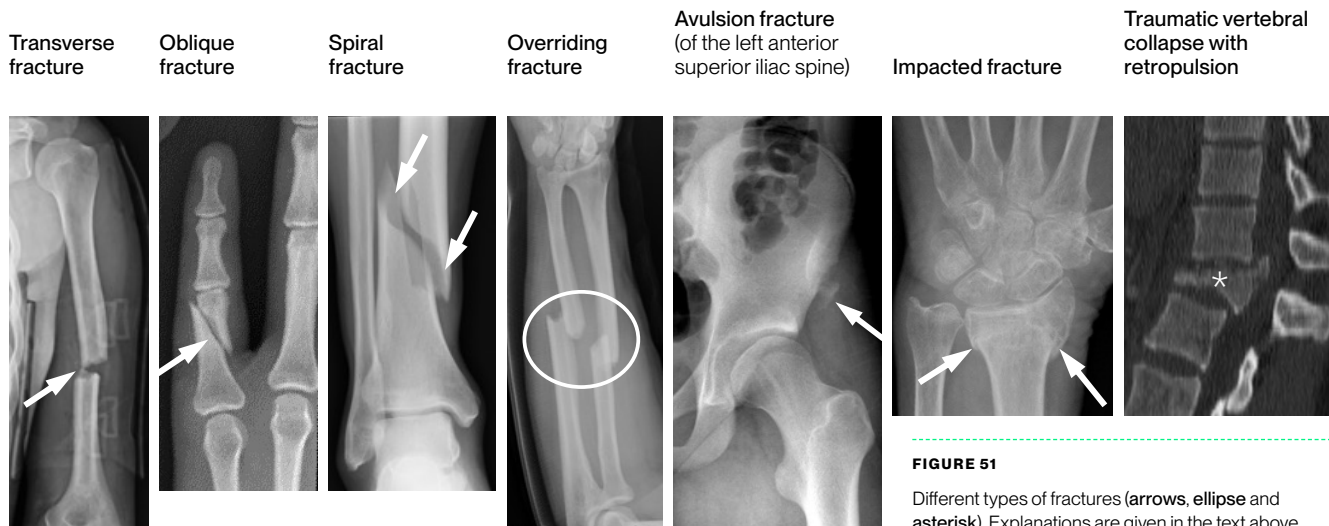
Test Your Knowledge

# / Fractures: Terminology

There are many ways to describe a fracture depending on its properties (**Figures 51 and 52**). Based on the **orientation or shape** of the fracture line, a fracture can be described as transverse, oblique or spiral. **Avulsion** fractures happen at the insertion sites of tendons or

ligaments, due to their sudden pull. Sometimes fracture fragments override each other or one fracture fragment impacts onto another. **Impaction** fractures in the spine are called vertebral collapse; there might be retropulsion of the fracture fragments narrowing the spinal canal and compromising its contents.

## >=< FURTHER KNOWLEDGE



**FIGURE 51**

Different types of fractures (arrows, ellipse and asterisk). Explanations are given in the text above.

## / Musculoskeletal Imaging

### CHAPTER OUTLINE:

Imaging Anatomy

Strengths, Weaknesses and Roles of Imaging Modalities

Arthropathies

### Fractures and Dislocations

/ Terminology

Infection

Tumours and Tumour-like Conditions

Metabolic Diseases

Developmental Abnormalities

Take-Home Messages

Suggested Reading and Sources

Test Your Knowledge

**CHAPTER OUTLINE:**

Imaging Anatomy

Strengths, Weaknesses  
and Roles of Imaging  
Modalities

Arthropathies

**Fractures and  
Dislocations**

/ Terminology

Infection

Tumours and Tumour-  
like Conditions

Metabolic Diseases

Developmental  
Abnormalities

Take-Home Messages

Suggested Reading  
and Sources

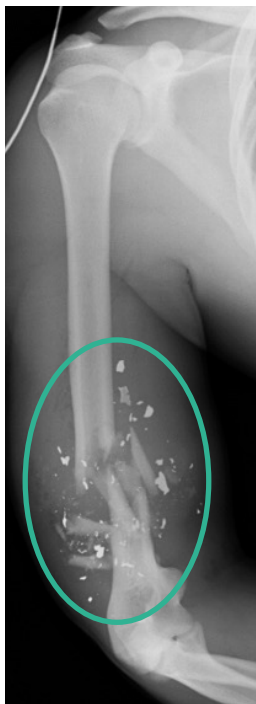Test Your Knowledge

When a fracture is comminuted, open or intraarticular (**Figure 52**), management is more difficult. Imaging makes it possible to identify such fractures.

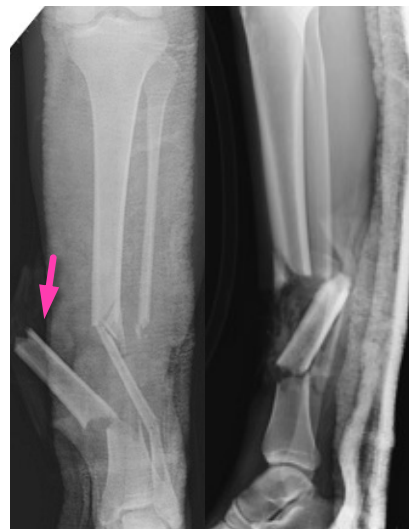**Comminuted fracture**

Radiographs show three or more fragments in a fracture. Small fracture pieces are called “butterfly fragments” due to their similarity to butterfly wings.

Metallic opacities at the fracture site in this patient are bullet fragments.

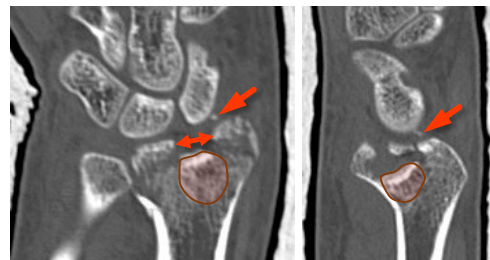


**Open fracture**



The skin is disrupted and at least one of the fracture fragments is exposed to the outside. By default, they are considered contaminated. A splint is in place on this patient.

**Intraarticular fracture**



The fracture extends into a joint. Intra-articular fractures usually require surgery. Gap (**red double arrow**) or step-off between fracture fragments at the articular surface or fragments within joint space are searched with radiographs – or better with CT. Fragments (**red arrow**) within the joint space need to be removed, otherwise they would damage the intact joint cartilage. When an impacted fracture fragment (**area outlined in red**) is present, bone grafting may be necessary.

**FIGURE 52**

Different types of complex fractures.

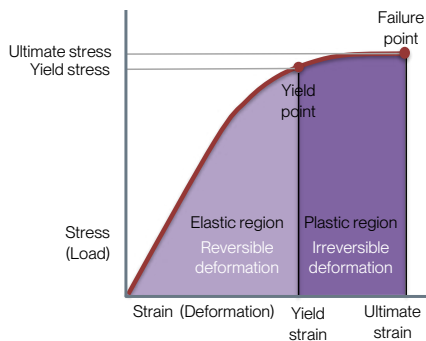


# / Fractures: Stress (Load) Versus Strain (Deformation)

The stress-strain curve for any material (**Figure 53**) displays the relationship between the amount of load it can absorb and the deformation it can tolerate before reaching its yield point and ultimately its failure point.

**Figure 54** illustrates the effects of

non-reversible deformation on the fibula and tibia, passing the yield and failure points, respectively.



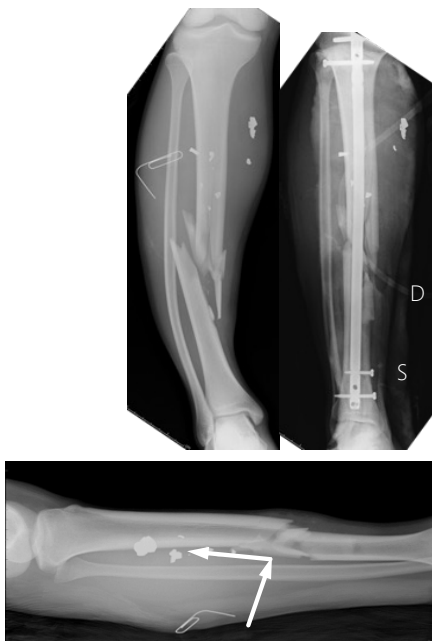**FIGURE 53**

Drawing adapted from Pathria M et al. Radiology 2016.

## >< FURTHER KNOWLEDGE

**FIGURE 54**

Comminuted fracture of the tibial diaphysis in this 17-year-old boy, who was shot at, shows butterfly fragments. The paperclip is used to mark the bullet entry site. No exit site is marked because the bullet hit the tibia, fractured it and was then dispersed into the calf muscles (*presumed path of the bullet is shown with dashed arrows on the lateral radiograph below*). The fibula is bowed ("plastic bowing deformity"). Since the ossification is not yet complete in this boy, the fibula could be bent back into its normal shape during reduction of the tibial fracture, which was then fixed with an intramedullary nail and locking screws (right). The fibula was in the "plastic region" on the graph at far left, while the tibia had already passed beyond this region. Note that a drain (D) and a splint (S) are in place post-operatively (right). Also note that the bullet fragments have not been removed during surgery, which would have violated the first principle of medicine.



## CHAPTER OUTLINE:

Imaging Anatomy

Strengths, Weaknesses  
and Roles of Imaging  
Modalities

Arthropathies

**Fractures and  
Dislocations**

/ Stress vs. Strain

Infection

Tumours and Tumour-  
like Conditions

Metabolic Diseases

Developmental  
Abnormalities

Take-Home Messages

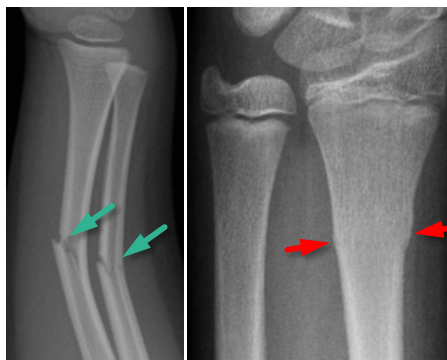
Suggested Reading  
and Sources

Test Your Knowledge

# / Fractures in Children: Special Features

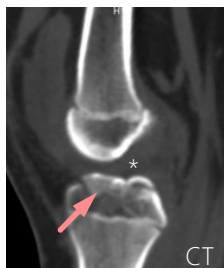The growing skeleton in children presents challenges and opportunities to detect fractures. Some fracture types, such as **greenstick** and **torus (buckle) fractures**, are almost exclusively seen in children (**Figure 55**). Tendons and ligaments are quite strong in children, whereas the

tensile strength of their attachment sites in bones are not equally up to task; therefore avulsion fractures, too, are more common in children (**Figure 56**). The orderly appearance of ossification centres around the elbow can be used to detect fractures in children before their teens (**Figure 57**).



**FIGURE 55**

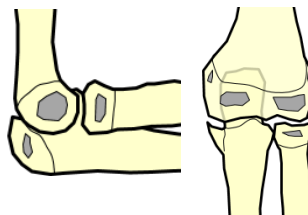
Difference between greenstick fracture and torus fracture. In greenstick fracture, the side opposite the bending force fractures completely, whereas the side under the force can remain intact (**green arrows**). The torus fracture is an impaction fracture in which the cortex around all or part of the bone circumference is buckled (**red arrows**).



**FIGURE 56**

Avulsion fracture of the tibial eminence at the attachment site (**pink arrow**) of the anterior cruciate ligament (**asterisk**) in a 12-year-old girl.

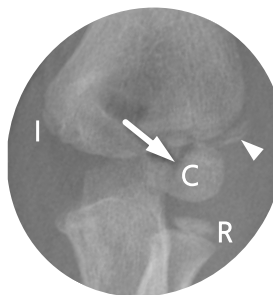
## >=< FURTHER KNOWLEDGE



**FIGURE 57**

Using the orderly appearance of ossification centres to detect elbow fractures in children. Ossification centres around the elbow (drawings) follows this order: capitulum, radial head, internal (medial) epicondyle, trochlea, olecranon, lateral epicondyle (mnemonic: CRITOL).

Therefore, what appears to be the lateral epicondyle (arrowhead on the CRX) in this 6-year-old boy with a capitellar fracture (arrow) has to be an additional avulsion fracture. Because, although the radial head (R) and internal epicondyle (I), as well as the capitulum (C) have already appeared, the trochlea is not yet visible.



## CHAPTER OUTLINE:

Imaging Anatomy

Strengths, Weaknesses  
and Roles of Imaging  
Modalities

Arthropathies

**Fractures and  
Dislocations**

/ Fracture Features  
in Children

Infection

Tumours and Tumour-  
like Conditions

Metabolic Diseases

Developmental  
Abnormalities

Take-Home Messages

Suggested Reading  
and Sources

Test Your Knowledge

## &lt;=&gt; ATTENTION

Special emphasis is given to the physis and its vicinity in children, as fractures or disturbances in this area may negatively affect skeletal growth

## &gt;=&lt; FURTHER KNOWLEDGE

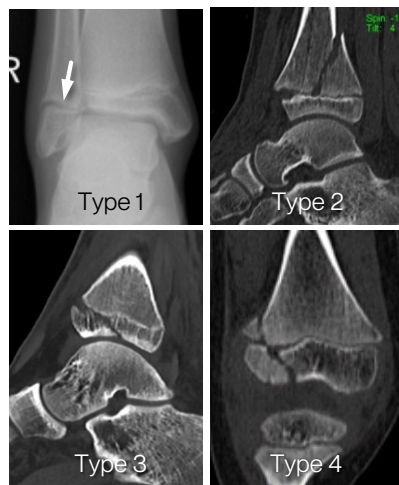

FIGURE 58

Salter-Harris classification.

- / The **Salter-Harris classification** divides physeal and periphyseal fractures into nine types. The more common Types 1–4 are shown in **Figure 58**. Type 1 involves exclusively the physis. Type 2 is the most common (75%).
- / When an insult results in premature closure of the primary growth plate, a **physeal bridge (or bar)** may occur (**Figure 59**).
- / A **physeal tongue** occurs when metaphyseal vascular compromise disrupts endochondral ossification and allows chondrocytes (that later ossify) to extend into the metaphysis (**Figure 60**).

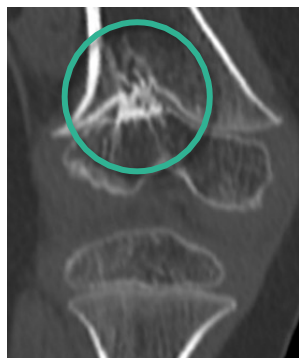

FIGURE 59

Physeal bar in the right distal femoral physis (circle) in this 4-year-old boy resulted in limb length discrepancy (right). Note that the right leg is shorter than the left. He had been hospitalised for infection as a newborn.

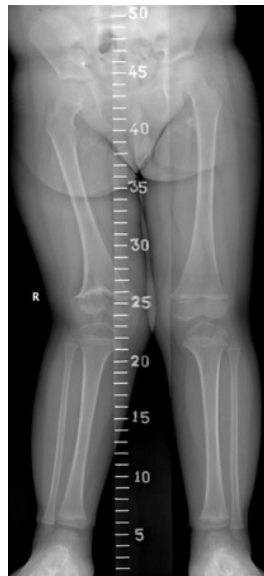

FIGURE 60

Physeal tongue (arrow) in a 9-year-old boy. The only significant history of trauma was a fall from a bicycle at 5 years of age.

## Musculoskeletal Imaging

## CHAPTER OUTLINE:

Imaging Anatomy

Strengths, Weaknesses and Roles of Imaging Modalities

Arthropathies

## Fractures and Dislocations

/ Fracture Features in Children

Infection

Tumours and Tumour-like Conditions

Metabolic Diseases

Developmental Abnormalities

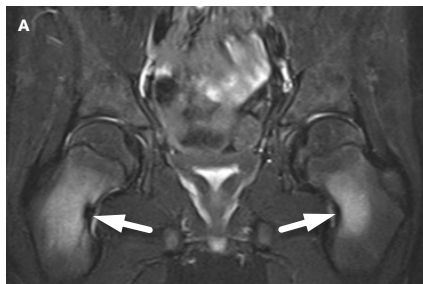
Take-Home Messages

Suggested Reading and Sources

Test Your Knowledge

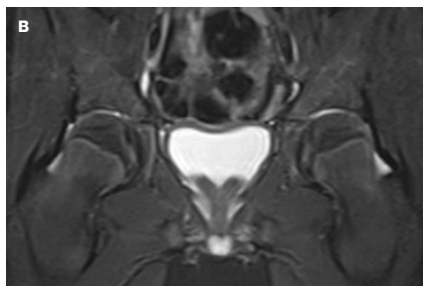
# / Stress Fractures

“Stress fractures” occur without major (i.e., high-energy) trauma during daily activities due to a mismatch between repetitive mechanical stress and bone strength. Stress fractures are usually seen in the lower extremities or the spine. There are two types of stress fractures:

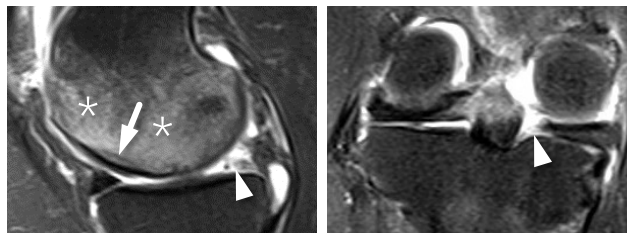


**FIGURE 61**

**A.** MRI shows right>left femoral neck incomplete fatigue fractures (arrows) surrounded by bone marrow oedema in an otherwise healthy 9-year-old basketball player. **B.** Follow-up MRI seven months later shows disappearance of fractures and complete resolution of marrow oedema.



- / Fatigue fracture (overuse fracture) is caused by abnormal stress or abnormally strenuous activity on a normal bone. The continuous application of an increased stress (e.g., running) in a normal body can cause microfractures. When they accumulate faster than the body can heal, these microfractures eventually give way to macroscopic failure (an overt stress fracture) visible on imaging (**Figure 61**).
- / Insufficiency fracture is caused by normal stress on abnormal bone, e.g., associated with vitamin D deficiency or osteoporosis (**Figure 62**).



**FIGURE 62**

MRI shows a subcortical incomplete insufficiency fracture (arrow) surrounded with bone marrow oedema (\*) at the weight-bearing portion of the medial femoral condyle in this 65-year-old woman with osteoporosis. The posterior root avulsion of the degenerated medial meniscus (arrowheads) resulted in medial meniscus extrusion, likely paving the way for this fracture. A small amount of stress during normal daily activities is sufficient to cause such a fracture in the background of osteoporosis.

## / Musculoskeletal Imaging

### CHAPTER OUTLINE:

Imaging Anatomy

Strengths, Weaknesses and Roles of Imaging Modalities

Arthropathies

**Fractures and Dislocations**

/ Stress Fractures

Infection

Tumours and Tumour-like Conditions

Metabolic Diseases

Developmental Abnormalities

Take-Home Messages

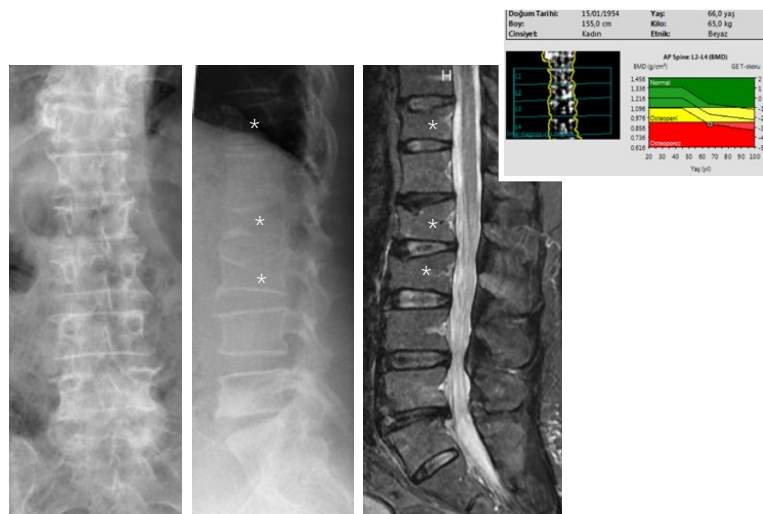
Suggested Reading and Sources

Test Your Knowledge

# / Stress Fractures in the Spine

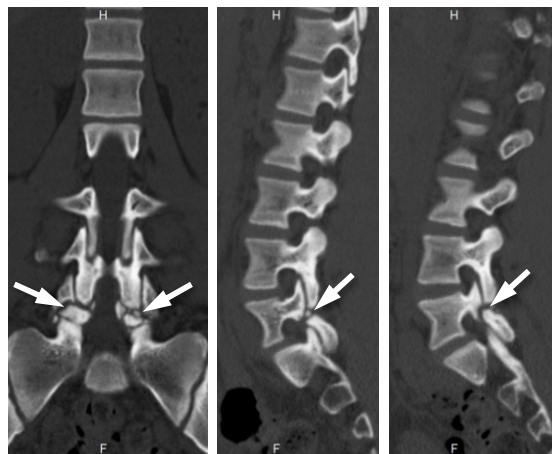
Spinal column is a common location for stress fractures, especially the insufficiency type (**Figure 63**). Fatigue fractures of the pars interarticularis (**Figure 64**),

seen in adolescents and young adults and also known as “spondylolysis”, can result in spondylolisthesis.



**FIGURE 63**

Radiographs and MRI show insufficiency type vertebral compression fractures (asterisks) in a 66-year-old woman with osteoporosis, confirmed with dual energy X-ray absorptiometry (top right).



**FIGURE 64**

CT shows bilateral L5 pars interarticularis fatigue fractures (arrows) with comminution in a 13-year-old girl.

## CHAPTER OUTLINE:

Imaging Anatomy

Strengths, Weaknesses  
and Roles of Imaging  
Modalities

Arthropathies

**Fractures and  
Dislocations**

/ Stress Fractures

Infection

Tumours and Tumour-  
like Conditions

Metabolic Diseases

Developmental  
Abnormalities

Take-Home Messages

Suggested Reading  
and Sources

Test Your Knowledge

# / Pathological Fractures

&lt;=&gt; ATTENTION

There is no “physiological” fracture. Yet, some fractures are called “pathological”. Some consider insufficiency type stress fractures also as pathological fractures, because of the underlying condition of

generalised bone fragility. Generally, however, pathological fractures are considered to occur at the location of a focal benign or malignant lesion (**Figure 65**).

**Musculo-skeletal Imaging**

## CHAPTER OUTLINE:

Imaging Anatomy

Strengths, Weaknesses and Roles of Imaging Modalities

Arthropathies

## Fractures and Dislocations

/ Pathological Fractures

Infection

Tumours and Tumour-like Conditions

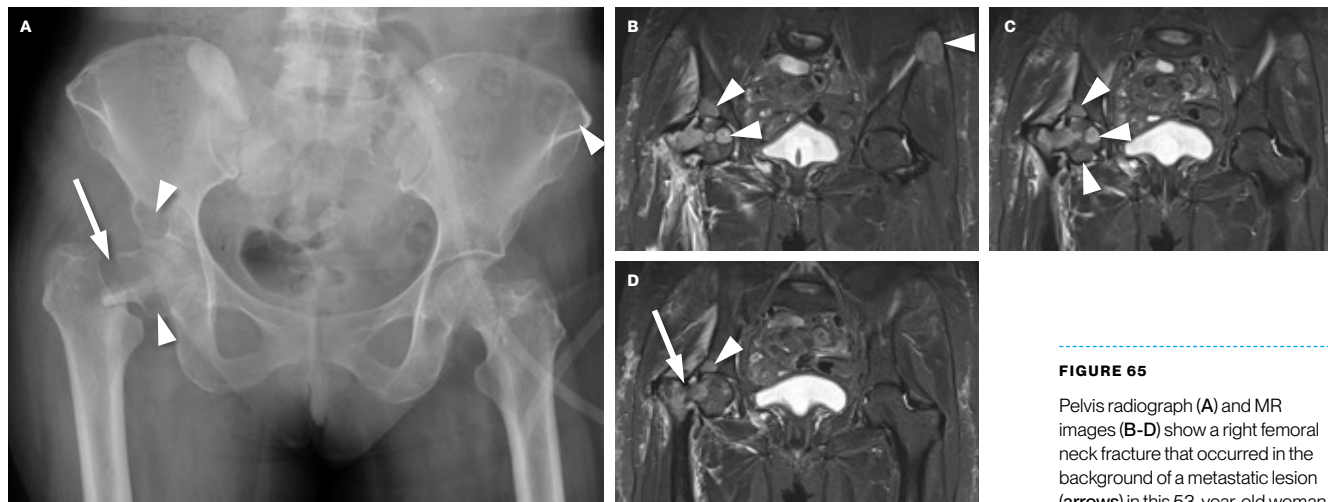
Metabolic Diseases

Developmental Abnormalities

Take-Home Messages

Suggested Reading and Sources

Test Your Knowledge



**FIGURE 65**

Pelvis radiograph (A) and MR images (B-D) show a right femoral neck fracture that occurred in the background of a metastatic lesion (arrows) in this 53-year-old woman with breast cancer. Other metastases are marked by arrowheads.



# / Pearls and Pitfalls in Identifying Fractures

We use a systematic approach to look for fractures on radiographs, making use of some pearls. All along, we need to take into account also some pitfalls so as not to misidentify a fracture.

Cortices of all bones on radiographs need to be followed. When there is a break in the cortical continuity, there might be a fracture (Figure 66).

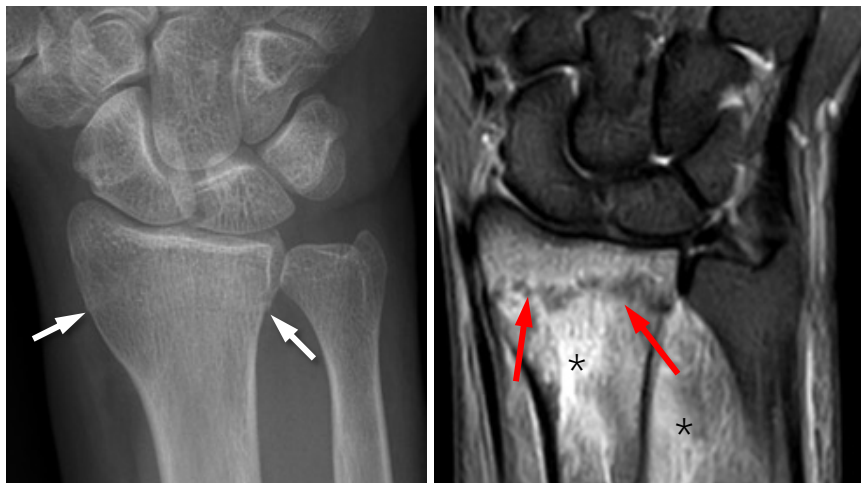


FIGURE 66

This 65-year-old woman slipped on ice and fell onto her outstretched hand. The breaks in cortical continuity of the distal radius (white arrows) represent a fracture, later confirmed by MRI (red arrows), which also showed both the bone marrow and soft tissue oedema (\*).

## <=> ATTENTION

**Following cortical continuity on radiographs is essential.**

MRI is the best modality to show an **acute fracture** (chronic fractures and tiny intraarticular fracture fragments, however, might be easily missed on MRI). There is a simple reason for this: Two things always happen in an acute fracture (even if it is an incomplete fracture): Bone marrow oedema surrounding the fracture line and soft tissue oedema at the immediate vicinity of the fracture. MRI is the only imaging modality to show both of these exquisitely. When a fracture is not visible on radiographs but identified on MRI (or sometimes on CT), it is called an **occult fracture**.

## / Musculoskeletal Imaging

### CHAPTER OUTLINE:

Imaging Anatomy

Strengths, Weaknesses and Roles of Imaging Modalities

Arthropathies

**Fractures and Dislocations**

/ Pearls and Pitfalls

Infection

Tumours and Tumour-like Conditions

Metabolic Diseases

Developmental Abnormalities

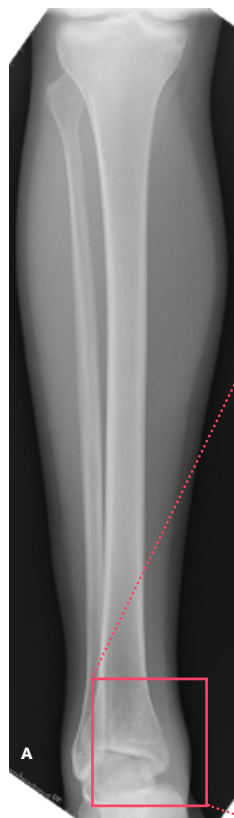
Take-Home Messages

Suggested Reading and Sources

Test Your Knowledge



## / Pearls in Identifying Fractures



## &lt;=&gt; ATTENTION

Looking for soft tissue oedema on radiographs. Zooming and changing brightness and contrast settings.

ESSENTIAL

The close vicinity of soft tissue oedema on radiographs is a prime suspect area for acute fractures. All radiographs need to be scrutinised by zooming and changing brightness and contrast settings. Acute fractures are always associated with surrounding soft tissue oedema (Figures 67 and 68). Not all soft tissue oedema, however, is necessarily associated with fractures.

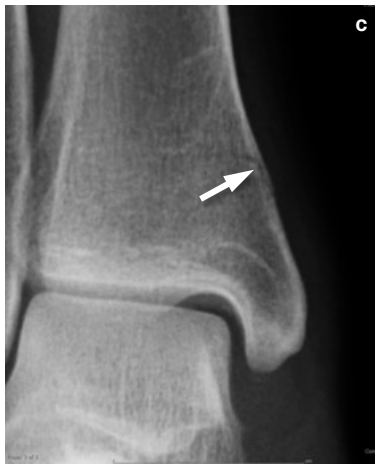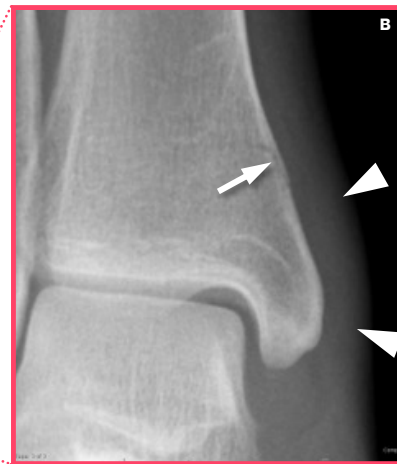


FIGURE 67

The only clinical information given to the radiologist about this patient was "pain". CRX of the calf (A) and zoomed detail (B and C). Careful examination of the subcutaneous fat density reveals oedema (water density) overlying the medial ankle (arrowheads). Note that there is an incomplete fracture (arrow) underlying the soft tissue oedema. The fracture is better appreciated on a different brightness and contrast setting (arrow, C). It was later confirmed with the patient that her pain was indeed in this location.

## / Musculoskeletal Imaging

## CHAPTER OUTLINE:

Imaging Anatomy

Strengths, Weaknesses and Roles of Imaging Modalities

Arthropathies

**Fractures and Dislocations**

/ Pearls and Pitfalls

Infection

Tumours and Tumour-like Conditions

Metabolic Diseases

Developmental Abnormalities

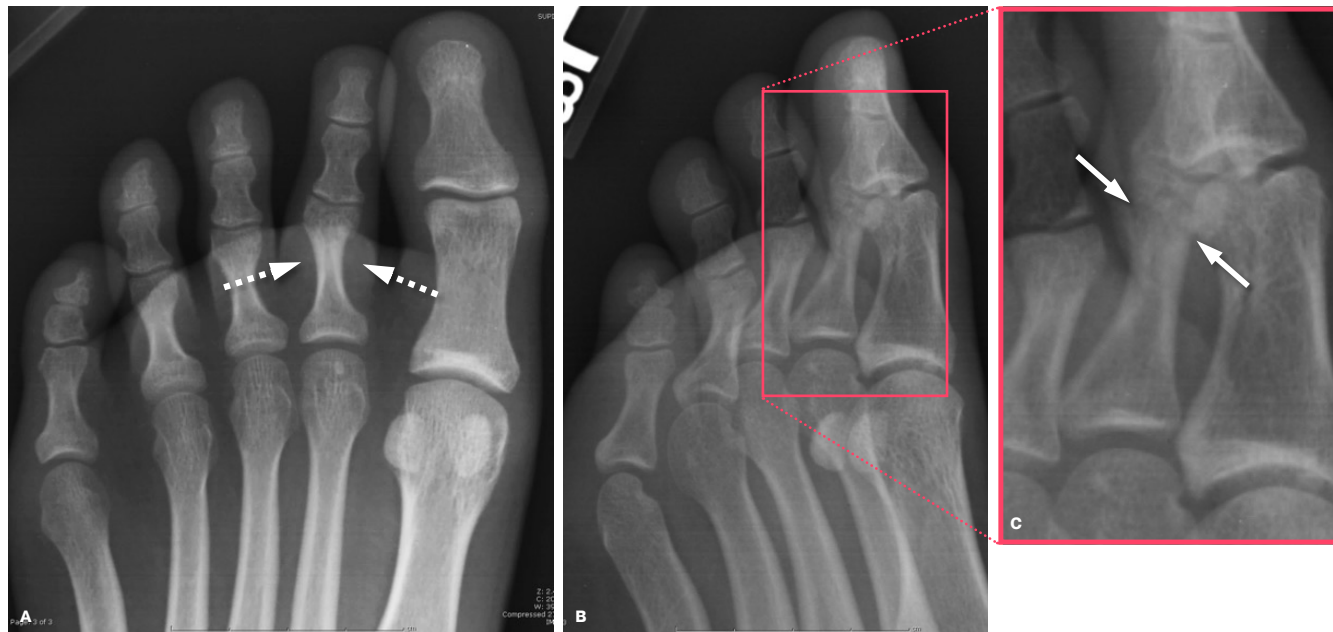
Take-Home Messages

Suggested Reading and Sources

Test Your Knowledge

## &lt;&gt; ATTENTION

Looking for soft tissue edema on radiographs is essential.



**FIGURE 68**

Note mild thickening of the base of the second toe (A), consistent with oedema in this patient (dashed arrows). Oblique radiograph (B) and zoomed detail (C) show a fracture at the neck of the proximal phalanx (white arrows).

## Musculo-skeletal Imaging

### CHAPTER OUTLINE:

Imaging Anatomy

Strengths, Weaknesses and Roles of Imaging Modalities

Arthropathies

**Fractures and Dislocations**

/ Pearls and Pitfalls

Infection

Tumours and Tumour-like Conditions

Metabolic Diseases

Developmental Abnormalities

Take-Home Messages

Suggested Reading and Sources

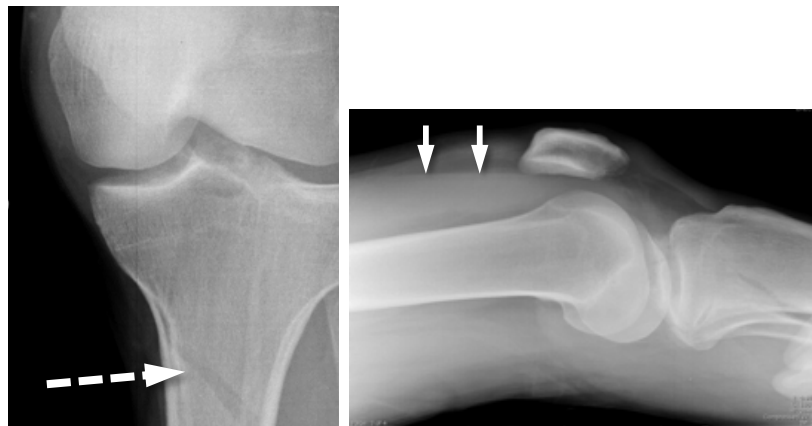
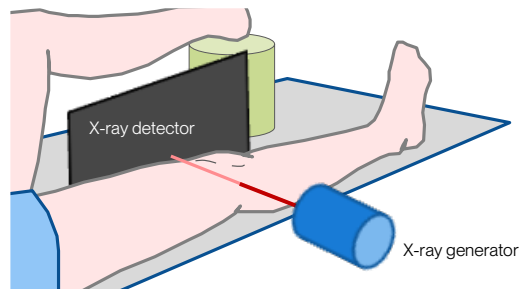
Test Your Knowledge

## &lt;=&gt; ATTENTION

**Lipohaemarthrosis**

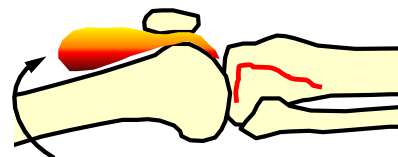
> Telltale sign of an intraarticular fracture

When a fracture extends into a joint, fat and blood from the bone marrow flow into the joint space (and its recesses), hence the name "lipohaemarthrosis". Gravity-dependent layering of fat, serum and haematocrit can be seen by sending a horizontal beam through the joint and picking up these "cross-table" X-rays on a detector plate (Figure 69).

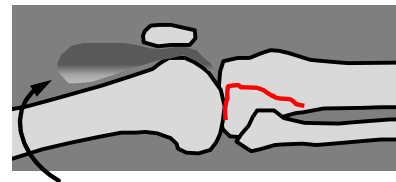


**FIGURE 69**

Intraarticular extension of the proximal tibial fracture (**dashed arrow**) in this patient was ascertained by the use of cross-table radiographic technique showing layering (**solid arrows**) of bone marrow fat and blood within the suprapatellar recess of the knee.



Blood and fat from the bone marrow of the fractured proximal tibia filling the suprapatellar recess.



Radiographic appearance of the layered bone marrow fat-serum-haematocrit filling the suprapatellar recess.

## Musculo-skeletal Imaging

### CHAPTER OUTLINE:

Imaging Anatomy

Strengths, Weaknesses and Roles of Imaging Modalities

Arthropathies

**Fractures and Dislocations**

/ Pearls and Pitfalls

Infection

Tumours and Tumour-like Conditions

Metabolic Diseases

Developmental Abnormalities

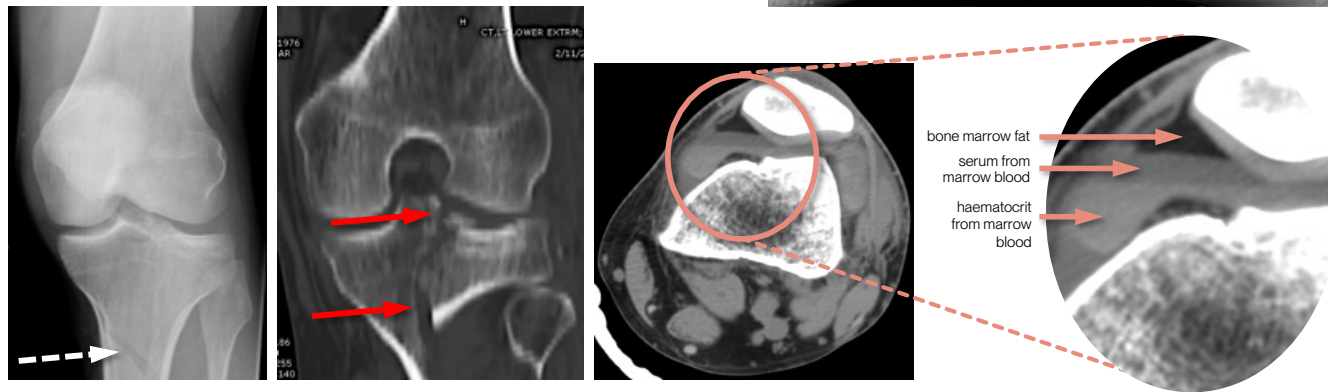
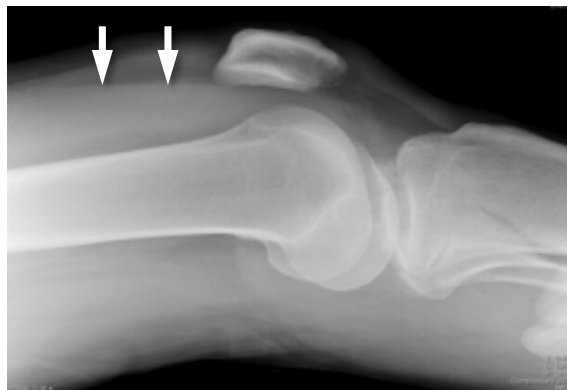Take-Home Messages

Suggested Reading and Sources

Test Your Knowledge

## Lipohaemarthrosis

Gravity-dependent layering of fat, serum and haematocrit can be seen not only on a “cross-table” radiograph (arrows, right), but also on cross-sectional imaging such as CT and MRI (Figure 70).



**FIGURE 70**

Same patient as in Fig. 69. Intraarticular extension of the proximal tibial fracture (dashed arrow) was also shown on the coronal CT reformation (red arrows). Transverse CT image and corresponding zoomed detail (in ellipse) display the layering of the bone marrow fat, serum and haematocrit within the suprapatellar recess of the knee.

## Musculoskeletal Imaging

### CHAPTER OUTLINE:

Imaging Anatomy

Strengths, Weaknesses and Roles of Imaging Modalities

Arthropathies

**Fractures and Dislocations**

/ Pearls and Pitfalls

Infection

Tumours and Tumour-like Conditions

Metabolic Diseases

Developmental Abnormalities

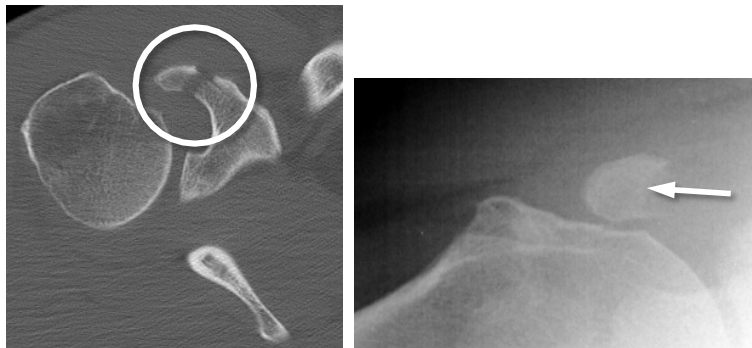Take-Home Messages

Suggested Reading and Sources

Test Your Knowledge

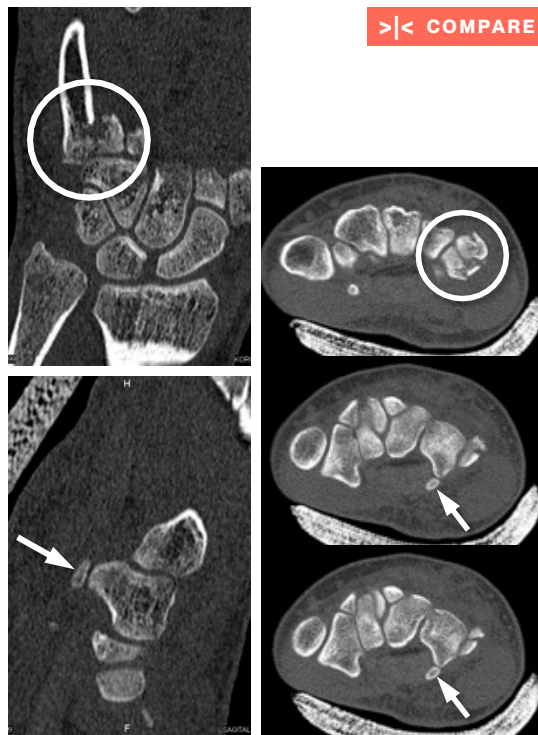
## Acute Fracture versus Old Fracture

One of the hallmarks of an acute fracture is the lack of cortical bone at the fracture edges opposing each other. Over time cortication of ununited fracture fragments occurs. This is an important distinction for estimating fracture age (acute versus old) as shown in **Figures 71** and **72**.



**FIGURE 71**

Note the non-white (i.e., uncorticated) and craggy edges at the opposing surfaces of fracture fragments in this coracoid fracture (**circle**, left; **arrow**, right).



**FIGURE 72**

Compare the uncorticated edges at the opposing surfaces of fracture fragments in this comminuted intra-articular fracture of the fifth metacarpal base (**circles**) with the corticated old fracture of the hook of the hamate (**arrows**).

>< COMPARE

## Musculoskeletal Imaging

### CHAPTER OUTLINE:

Imaging Anatomy

Strengths, Weaknesses and Roles of Imaging Modalities

Arthropathies

**Fractures and Dislocations**

/ Pearls and Pitfalls

Infection

Tumours and Tumour-like Conditions

Metabolic Diseases

Developmental Abnormalities

Take-Home Messages

Suggested Reading and Sources

Test Your Knowledge

## CHAPTER OUTLINE:

Imaging Anatomy

Strengths, Weaknesses  
and Roles of Imaging  
Modalities

Arthropathies

**Fractures and  
Dislocations**

/ Pearls and Pitfalls

Infection

Tumours and Tumour-  
like Conditions

Metabolic Diseases

Developmental  
Abnormalities

Take-Home Messages

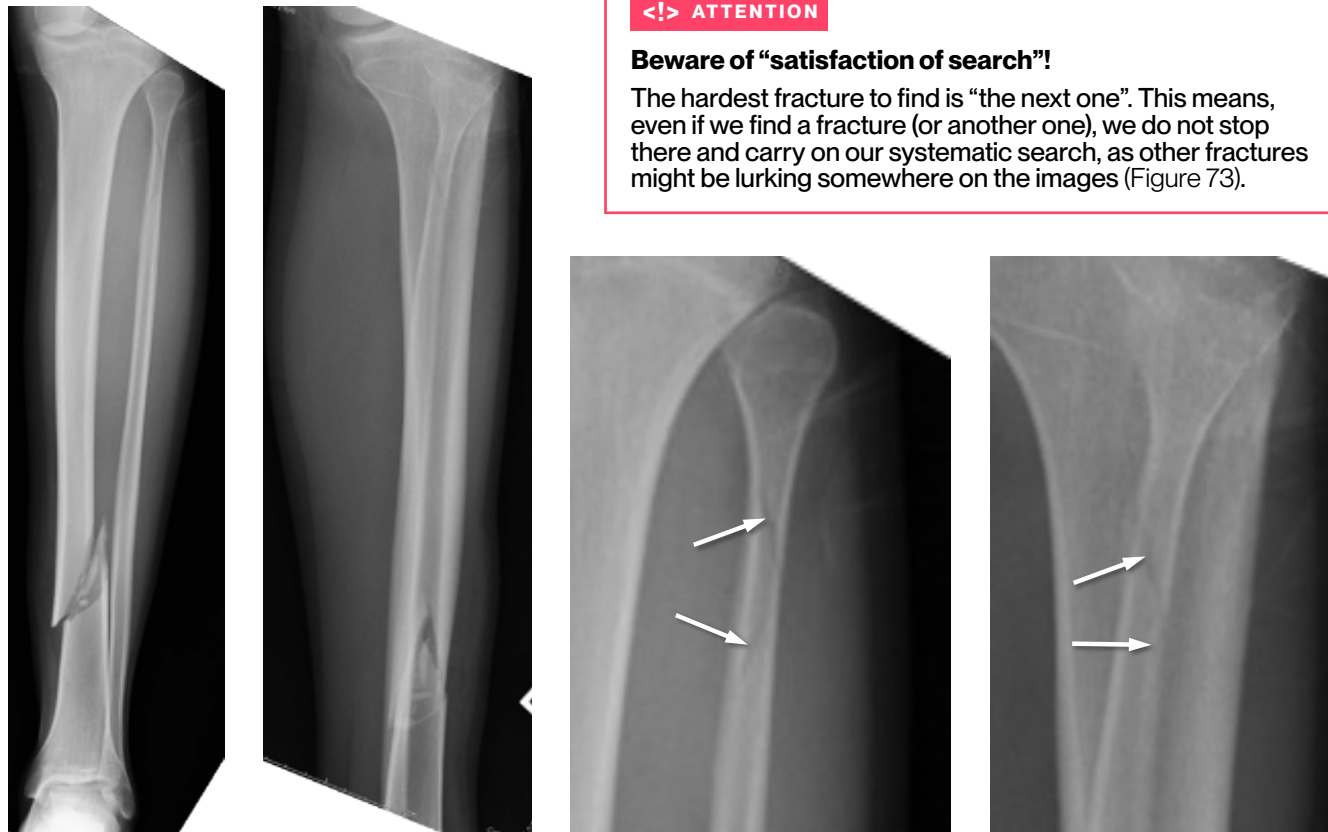Suggested Reading  
and Sources

Test Your Knowledge

## &lt;!&gt; ATTENTION

**Beware of “satisfaction of search”!**

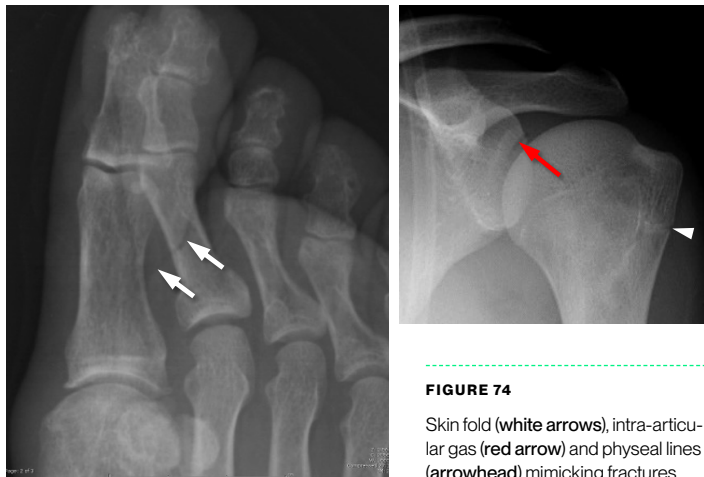
The hardest fracture to find is “the next one”. This means, even if we find a fracture (or another one), we do not stop there and carry on our systematic search, as other fractures might be lurking somewhere on the images (Figure 73).

**FIGURE 73**

Comminuted fracture of the tibia diaphysis is easily identified in this patient. The fracture of the proximal fibula, (arrows, enlarged views on the right), however, was missed.

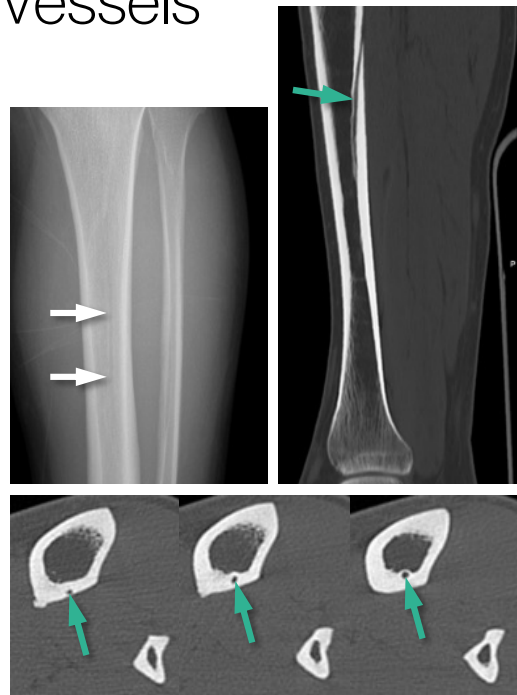
# / Pitfalls of Fractures: Skin Folds, Intra-articular Gas, Physeal Lines, Nutrient Vessels

- / A skin fold or intraarticular gas might sometimes be mistaken for a fracture (**Figure 74**).
- / A physeal line around the time of its closure can also mimic a fracture (**Figure 74**).
- / Another common mimicker of fractures is a nutrient vessel (**Figure 75**).



**FIGURE 74**

Skin fold (white arrows), intra-articular gas (red arrow) and physeal lines (arrowhead) mimicking fractures.



**FIGURE 75**

Nutrient vessel (white arrows, top left) mimicking a fracture on CRX. CT clearly shows that this appearance is caused by a nutrient vessel (green arrows).

## / Musculoskeletal Imaging

### CHAPTER OUTLINE:

Imaging Anatomy

Strengths, Weaknesses and Roles of Imaging Modalities

Arthropathies

**Fractures and Dislocations**

/ Pearls and Pitfalls

Infection

Tumours and Tumour-like Conditions

Metabolic Diseases

Developmental Abnormalities

Take-Home Messages

Suggested Reading and Sources

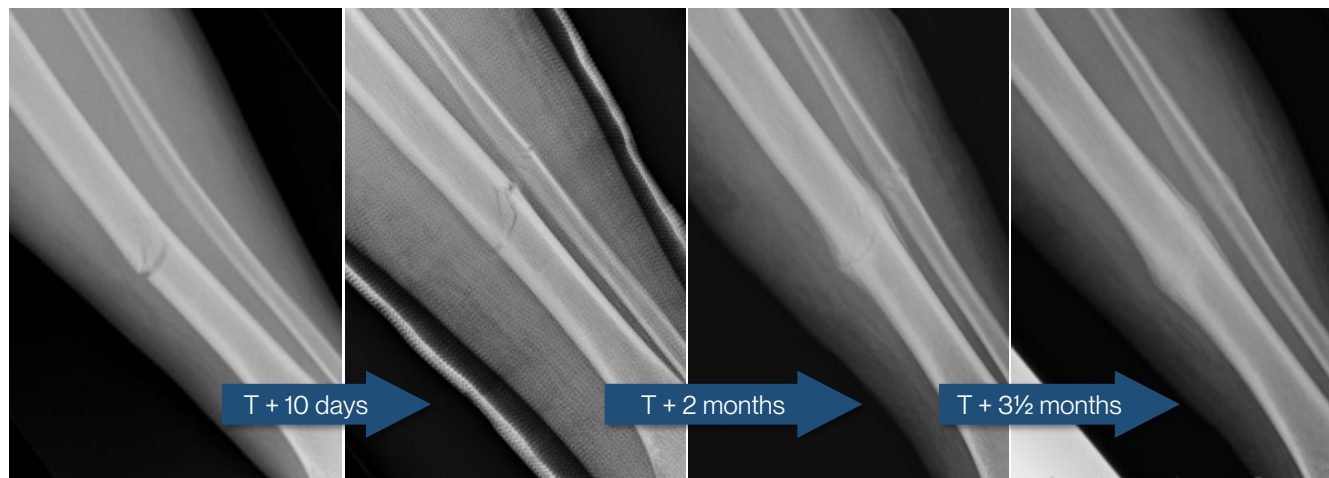
Test Your Knowledge



# / Imaging Fracture Healing

Fracture healing is a complex process that involves inflammatory (days to weeks), reparative (weeks to months) and remodelling (months to years)

phases, which can be monitored by radiographs. Calcified callus is usually first depicted on radiographs a few weeks after the injury (**Figure 76**).



**FIGURE 76**

Fracture healing after trauma (T) as seen on CRX.

**CHAPTER OUTLINE:**

Imaging Anatomy

Strengths, Weaknesses  
and Roles of Imaging  
Modalities

Arthropathies

**Fractures and  
Dislocations**

/ Fracture Healing

Infection

Tumours and Tumour-  
like Conditions

Metabolic Diseases

Developmental  
Abnormalities

Take-Home Messages

Suggested Reading  
and Sources

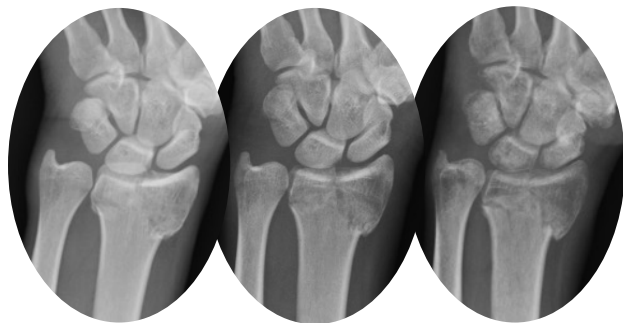Test Your Knowledge

# / Imaging Fracture Healing – or the Lack of It

/ **“Non-union”** means failure of normal fracture healing, whereby solid bone healing will not occur without further therapeutic intervention. Currently there is no consensus definition of non-union. According to one of the proposed definitions, however, non-union is considered when a fracture does not show evidence of increased

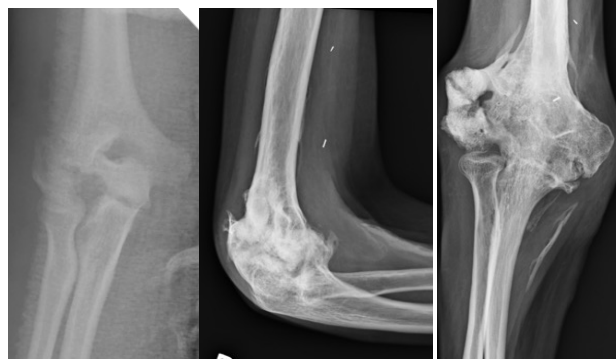healing in three consecutive radiographs each taken one month apart (**Figure 77**).

/ In **“malunion”**, fracture fragments heal in poor position or alignment so that functional or cosmetic problems arise (**Figure 78**).



**FIGURE 77**

Absence of calcified callus formation in the distal radius fracture 4 weeks (**centre**) and 12 weeks (**right**) after the initial injury (**left**) is consistent with non-union.



**FIGURE 78**

Malunion of an intra-articular lateral condylar fracture (**centre** and **right**) in a 20-year-old man two and a half years after the initial injury (**left**).

## CHAPTER OUTLINE:

Imaging Anatomy

Strengths, Weaknesses  
and Roles of Imaging  
Modalities

Arthropathies

**Fractures and  
Dislocations**

/ Absent Fracture  
Healing

Infection

Tumours and Tumour-  
like Conditions

Metabolic Diseases

Developmental  
Abnormalities

Take-Home Messages

Suggested Reading  
and Sources

Test Your Knowledge

**CHAPTER OUTLINE:**

Imaging Anatomy

Strengths, Weaknesses  
and Roles of Imaging  
Modalities

Arthropathies

Fractures and  
Dislocations

**Infection**

Tumours and Tumour-  
like Conditions

Metabolic Diseases

Developmental  
Abnormalities

Take-Home Messages

Suggested Reading  
and Sources

Test Your Knowledge

# / Infection

# / Osteomyelitis

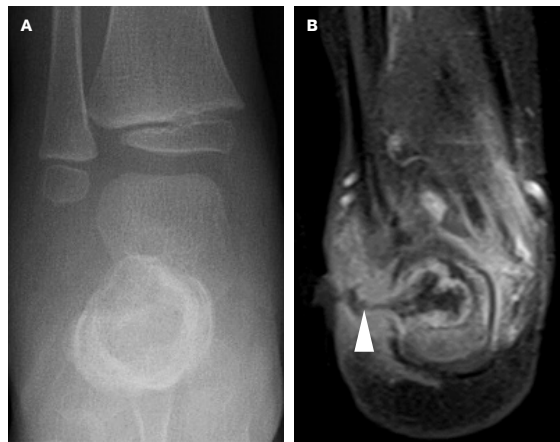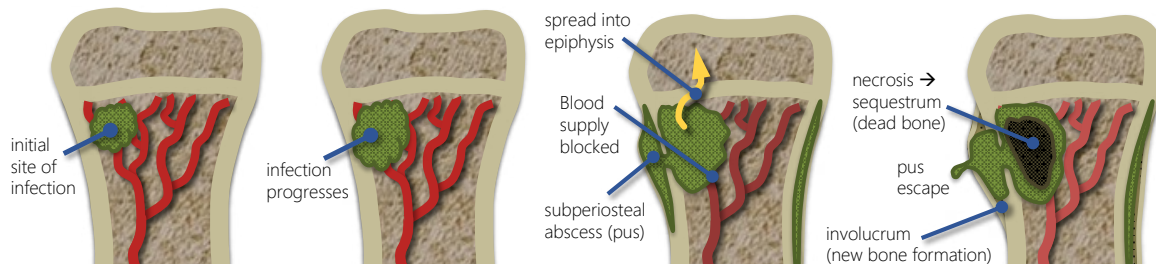
- / **Hematogenous spread of infection**—usually to the metaphysis—triggers a cascade of events resulting in subperiosteal abscess, draining sinus, sequestrum and involucrum formation—although, depending on the microorganism's virulence and the efficiency of treatment, not every feature in this cascade necessarily appears on imaging (**Figure 79**).
- / Findings on the combination of radiographs and MRI (**Figures 80–83**), which are extensively used for diagnosing osteomyelitis, closely reflect pathophysiology.

## <=> ATTENTION

In infancy and after adolescence, infection may spread into the adjacent epiphysis through the physis (growth plate).

**FIGURE 79**

The cascade of events in osteomyelitis.



**FIGURE 80**

CRX (A) and contrast-enhanced MRI (B) in a child with calcaral osteomyelitis. A sinus tract (arrowhead, B) drains pus.

## / Musculoskeletal Imaging

### CHAPTER OUTLINE:

Imaging Anatomy

Strengths, Weaknesses and Roles of Imaging Modalities

Arthropathies

Fractures and Dislocations

**Infection**

/ Osteomyelitis

Tumours and Tumour-like Conditions

Metabolic Diseases

Developmental Abnormalities

Take-Home Messages

Suggested Reading and Sources

Test Your Knowledge

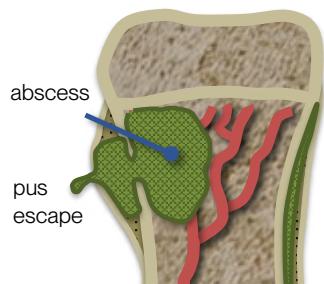
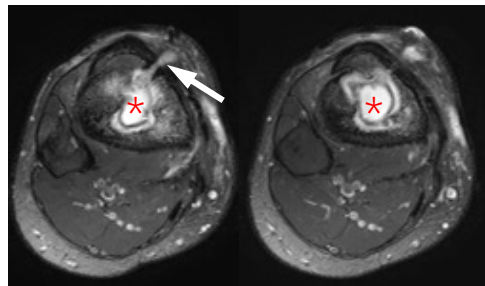


FIGURE 81

MRI shows how accumulated pus (asterisk) within the proximal tibial metaphysis (axial fluid-sensitive MR images) finds its way into the skin through a sinus tract (arrow) in a 29-year-old man with *S. aureus* osteomyelitis.

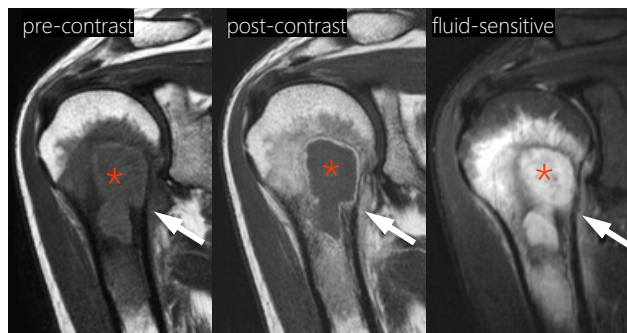
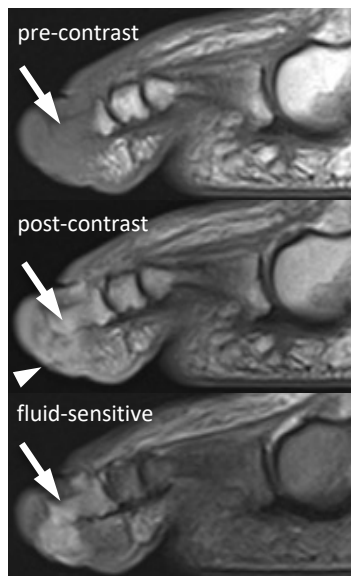


FIGURE 82

MR images display subacute osteomyelitis (Brodie abscess, asterisk) in a 20-year-old man (*S. aureus* infection). Note periosteal inflammation with contrast enhancement and high signal on the fluid-sensitive image (arrows), more on the medial than lateral aspect. The abscess shows only peripheral rim enhancement and has otherwise a high signal on the fluid sensitive image (asterisks).



<!> ATTENTION

MRI is widely used to confirm or rule out osteomyelitis in diabetic foot. Abnormal bone signal adjacent to a skin ulcer, sinus tract or abscess is highly suggestive of osteomyelitis, which is ruled out when bone signal is normal.

FIGURE 83

MR images show distal phalangeal great toe osteomyelitis (arrows) subjacent to a sinus tract (arrowhead) in a 53-year-old man with diabetes.

Musculoskeletal Imaging

CHAPTER OUTLINE:

Imaging Anatomy

Strengths, Weaknesses and Roles of Imaging Modalities

Arthropathies

Fractures and Dislocations

Infection

/ Osteomyelitis

Tumours and Tumour-like Conditions

Metabolic Diseases

Developmental Abnormalities

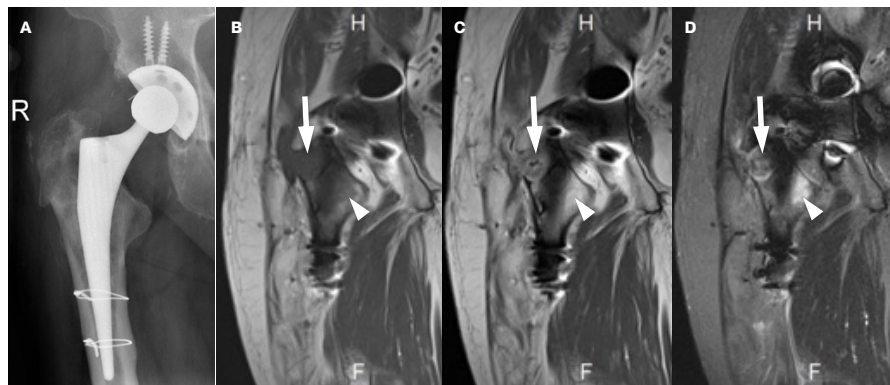
Take-Home Messages

Suggested Reading and Sources

Test Your Knowledge

# / Periprosthetic Infection

- / Hip replacement is the most common joint replacement surgery with an OECD average of 174 per 100,000 population in 2019.
- / Special MRI sequences have been developed for use in suspected infections adjacent to prosthetic implants, which, due to their metallic components, create image artifacts and present a challenge for MRI (Figures 84 and 85).
- / Ultrasonography can be used for guidance in fluid sampling for micro-biological analysis.



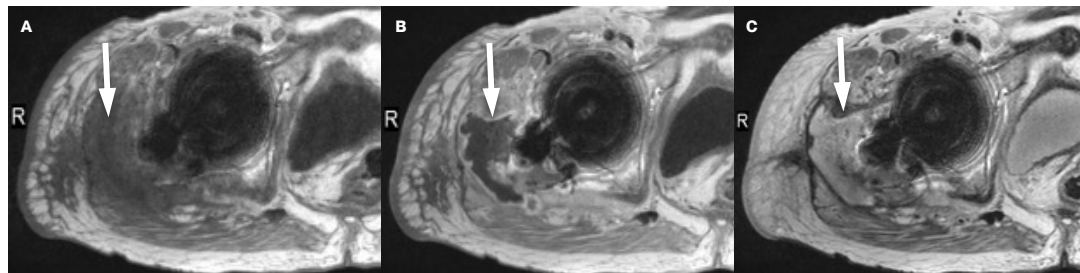
**FIGURE 84**

CRX (A) shows a total hip prosthesis. Periprosthetic infection was suspected. MRI before (B) and after i.v. contrast (C and D) show areas consistent with infection. Contrast-enhancement shows active bone (arrowheads) or soft tissue inflammation. Arrows point to an abscess.

## >=< FURTHER KNOWLEDGE

**FIGURE 85**

Axial MR images before (A) and after i.v. contrast (B) and fluid-sensitive image (C) in an 82-year-old woman with total hip replacement and suspected infection. Arrows point to a large periprosthetic abscess.



## / Musculo-skeletal Imaging

### CHAPTER OUTLINE:

Imaging Anatomy

Strengths, Weaknesses and Roles of Imaging Modalities

Arthropathies

Fractures and Dislocations

**Infection**

/ Periprosthetic Infection

Tumours and Tumour-like Conditions

Metabolic Diseases

Developmental Abnormalities

Take-Home Messages

Suggested Reading and Sources

Test Your Knowledge

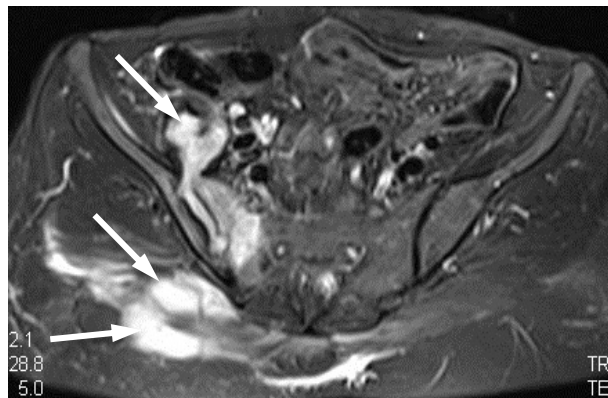
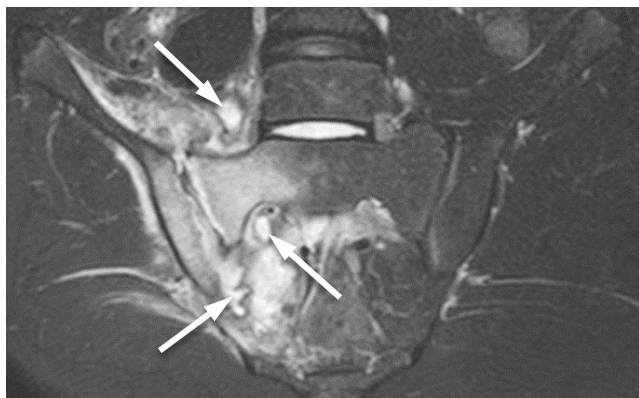


## / Septic Arthritis

## &lt;=&gt; ATTENTION

/ There is no pathognomonic imaging finding for septic arthritis. Therefore imaging should not delay joint aspiration and microbiological examination when there is clinical suspicion for septic arthritis.

/ Radiographs may show joint effusion in the early stage. MRI is especially suggestive in the presence of periarticular abscess(es), but otherwise non-specific for aetiology of monoarthritis (**Figure 86**). Ultrasonography can be used for ascertaining joint effusion and guides joint fluid aspiration.



**FIGURE 86**

Fluid-sensitive MR images obtained in two different patients. Septic right sacroiliitis is evidenced by synovitis, osteitis and periarticular abscesses (arrows).

## / Musculo-skeletal Imaging

## CHAPTER OUTLINE:

Imaging Anatomy

Strengths, Weaknesses  
and Roles of Imaging  
Modalities

Arthropathies

Fractures and  
Dislocations

## Infection

/ Septic Arthritis

Tumours and Tumour-  
like Conditions

Metabolic Diseases

Developmental  
Abnormalities

Take-Home Messages

Suggested Reading  
and Sources

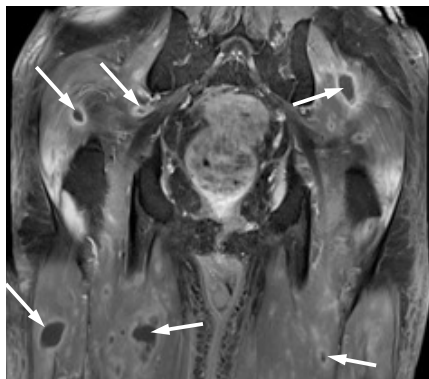
Test Your Knowledge



# / Pyomyositis, Septic Fasciitis, Necrotising Fasciitis and Septic Tenosynovitis

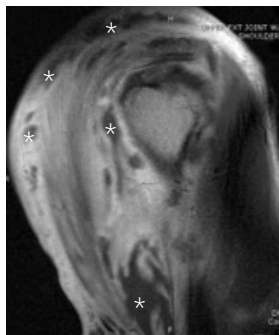
- / Infection in a muscle usually presents in the form of scattered small abscesses, termed **pyomyositis** when caused by bacteria (Figure 87).
- / **Septic fasciitis** is another form of soft tissue infection involving muscles and fascia; when necrotising, it can be life threatening (Figure 88).

- / In **septic tenosynovitis**, infection and/or pus are found within the tendon sheath (Figure 89).



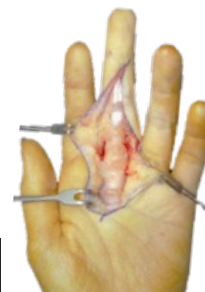**FIGURE 87**

Contrast-enhanced MRI displays scattered abscesses (**arrows**) representing pyomyositis in an immune-compromised 58-year-old man with *S. aureus* septicaemia.



**FIGURE 88**

MRI (contrast-enhanced image) shows non-enhancing (dark) geographic areas (**asterisks**) consistent with necrotising fasciitis involving the superficial, peripheral and deep fascia in this adult male i.v. drug abuser, who had to undergo left arm amputation later.



**FIGURE 89**

MRI (fluid-sensitive coronal and axial images, left) of tuberculous tenosynovitis in a 28-year-old radiology resident following a needle puncture during an interventional procedure. Note fluid accumulation in the tendon sheath and surrounding inflammation (**arrows**). Intraoperative image courtesy of Dr. Gürsel Leblebicioğlu, Ankara, Turkey.

## / Musculoskeletal Imaging

### CHAPTER OUTLINE:

Imaging Anatomy

Strengths, Weaknesses and Roles of Imaging Modalities

Arthropathies

Fractures and Dislocations

**Infection**

/ Infection of Muscles, Fascia and Tendons

Tumours and Tumour-like Conditions

Metabolic Diseases

Developmental Abnormalities

Take-Home Messages

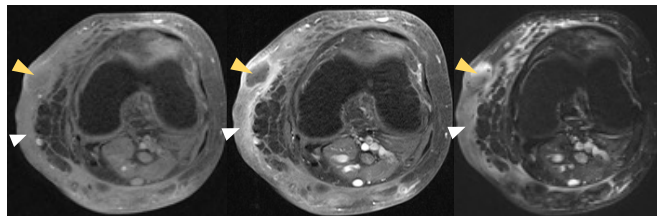
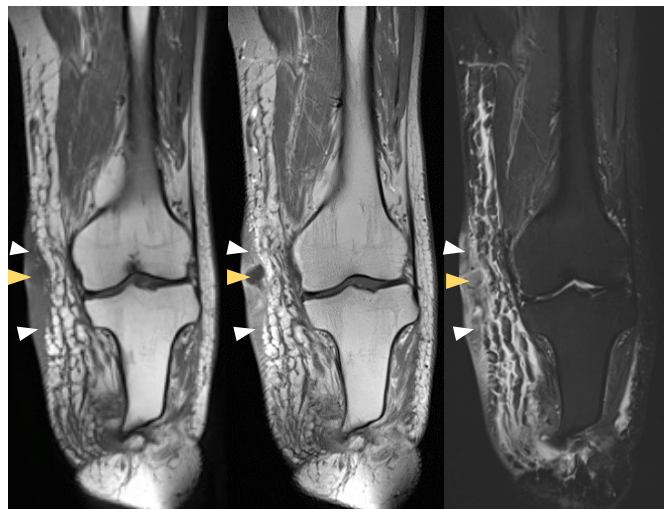
Suggested Reading and Sources

Test Your Knowledge

## / Lymphoedema versus Cellulitis

/ **Cellulitis** is an infection of the skin and subcutaneous fatty tissue, usually caused by bacteria, whereas **lymphoedema** is accumulation of lymph in the soft tissues due to impaired lymphatic flow.

/ Although usually straightforward, differentiating cellulitis from lymphedema clinically can sometimes be challenging. Cellulitis shows contrast enhancement on MRI, lymphedema does not (**Figure 90**).



**FIGURE 90**

Each of these two sets of MR images from a 32-year-old male below-the-knee amputee after trauma features pre- (left) and post-contrast (centre) and fluid-sensitive (right) sequences. Cellulitis (white arrowheads), which enhances with contrast, surrounds a medial subcutaneous abscess (yellow arrowheads). Lymphedema, deep to cellulitis, does not enhance. Abscesses characteristically show peripheral enhancement on imaging (see also **Figures 82, 84, 85, 87**).

**CHAPTER OUTLINE:**

Imaging Anatomy

Strengths, Weaknesses  
and Roles of Imaging  
Modalities

Arthropathies

Fractures and  
Dislocations

**Infection**

/ Lymphoedema vs.  
Cellulitis

Tumours and Tumour-  
like Conditions

Metabolic Diseases

Developmental  
Abnormalities

Take-Home Messages

Suggested Reading  
and Sources

Test Your Knowledge

**CHAPTER OUTLINE:**

Imaging Anatomy

Strengths, Weaknesses  
and Roles of Imaging  
Modalities

Arthropathies

Fractures and  
Dislocations

Infection

**Tumours and Tumour-  
like Conditions**

Metabolic Diseases

Developmental  
Abnormalities

Take-Home Messages

Suggested Reading  
and Sources

Test Your Knowledge

# / Tumours and Tumour-like Conditions

## / “Don’t Touch” Lesions

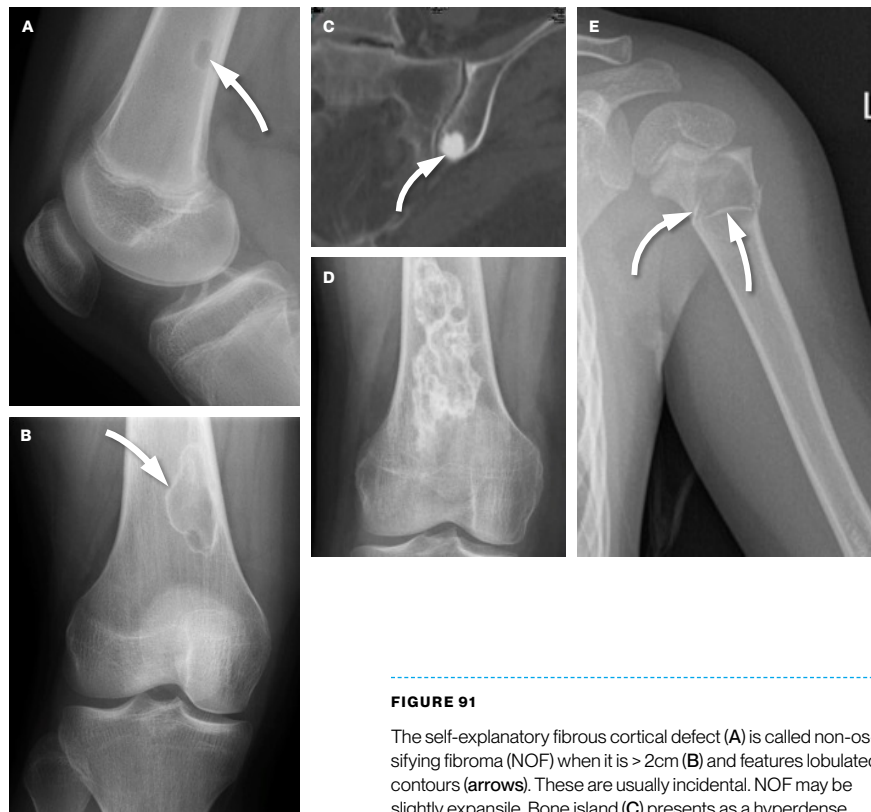
## &lt;!=&gt; ATTENTION

These are benign lesions where a radiological diagnosis is made without a differential diagnosis list and biopsy is NOT to be performed (it is unnecessary, may be misleading and may even lead to unnecessary surgery).

## &gt;=&lt; FURTHER KNOWLEDGE

“Don’t touch” lesions include:

- / Fibrous cortical defect (Figure 91)
- / Non-ossifying fibroma (Figure 91)
- / Bone island (Figure 91)
- / Bone infarct (Figure 91)
- / Solitary bone cyst (Figure 91)
- / Distal femoral cortical irregularity (Figures 92 and 93)
- / Myositis ossificans (Figure 94)



**FIGURE 91**

The self-explanatory fibrous cortical defect (A) is called non-ossifying fibroma (NOF) when it is > 2cm (B) and features lobulated contours (arrows). These are usually incidental. NOF may be slightly expansile. Bone island (C) presents as a hyperdense (sclerotic) lesion with spiculated contours (arrow). Bone infarcts (D) are heterogeneously sclerotic lesions with geographic contours. Solitary bone cyst (E) presents as a well defined radiolucency. The “fallen fragment” sign denotes pathological cortical fracture fragment(s) that are displaced into the cyst (arrows).

## / Musculoskeletal Imaging

## CHAPTER OUTLINE:

Imaging Anatomy

Strengths, Weaknesses and Roles of Imaging Modalities

Arthropathies

Fractures and Dislocations

Infection

**Tumours and Tumour-like Conditions**

/ “Don’t Touch” Lesions

Metabolic Diseases

Developmental Abnormalities

Take-Home Messages

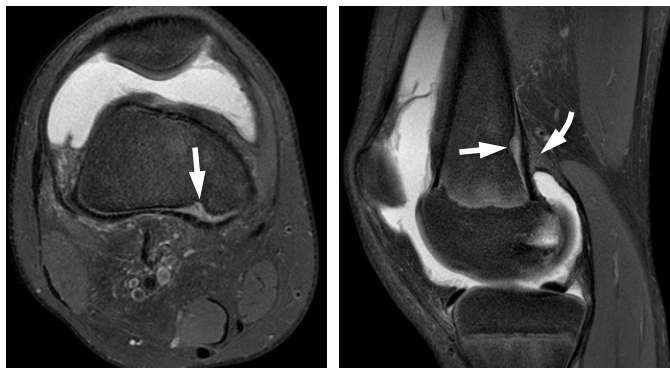
Suggested Reading and Sources

Test Your Knowledge

## / Distal Femoral Cortical Irregularity (aka “Cortical Desmoid”)

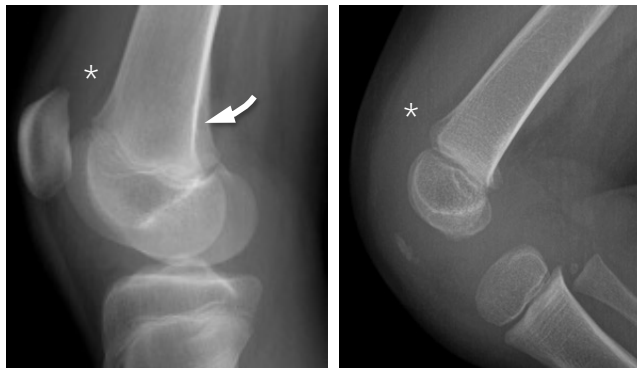A cortical irregularity at the posterior aspect of the distal femoral metaphysis corresponding to tendon attachment sites (most commonly that of medial

head of gastrocnemius) is a frequent incidental finding in children at MRI with a presumably mechanical stress-related origin (**Figures 92 and 93**).



**FIGURE 92**

MRI shows an incidental focal cortical lesion (**arrows**) at the posteromedial aspect of the distal femoral metaphysis in a child with a large knee joint effusion due to juvenile idiopathic arthritis. The lesion is at the level of the insertion of medial head of gastrocnemius (**curved arrow**).



**FIGURE 93**

A lateral radiograph shows mild radiolucency at the lesion location (**arrow**). Note that no such lesion is present at this location on the radiograph when the child was 2 years old (**right**). Joint effusion (\*), however, is visible on both radiographs of this child with longstanding juvenile idiopathic arthritis.

### CHAPTER OUTLINE:

Imaging Anatomy

Strengths, Weaknesses  
and Roles of Imaging  
Modalities

Arthropathies

Fractures and  
Dislocations

Infection

**Tumours and Tumour-  
like Conditions**

/ “Don’t Touch”  
Lesions

Metabolic Diseases

Developmental  
Abnormalities

Take-Home Messages

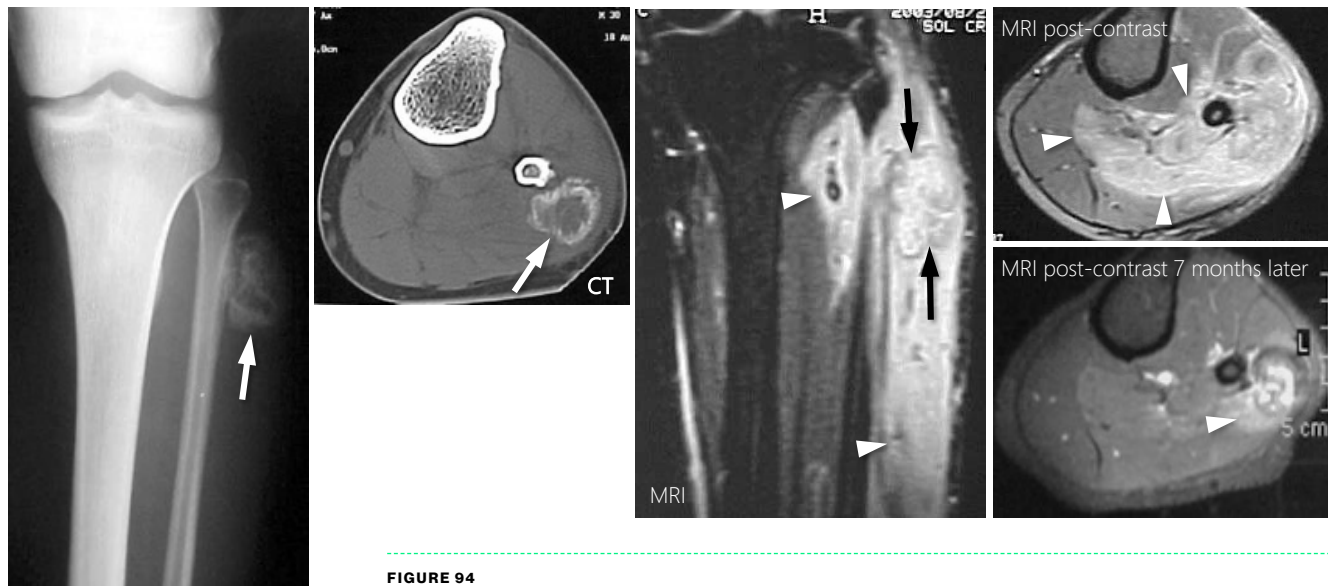
Suggested Reading  
and Sources

Test Your Knowledge

## / Myositis Ossificans

Myositis ossificans (**Figure 94**) is the most common form of heterotopic ossification occurring usually after trauma. Biopsy on such a lesion may be

misleading as aggressive histologic appearance can mimic sarcoma (and, unfortunately on occasions in the past, resulted in radical surgery).



**FIGURE 94**

Typical radiographic appearance of myositis ossificans is circumferential calcification with a lucent centre (arrows). MRI shows extensive soft tissue inflammation (arrowheads) surrounding the lesion which, over time, subsides and resolves.

## / Musculoskeletal Imaging

### CHAPTER OUTLINE:

Imaging Anatomy

Strengths, Weaknesses and Roles of Imaging Modalities

Arthropathies

Fractures and Dislocations

Infection

**Tumours and Tumour-like Conditions**

/ “Don’t Touch” Lesions

Metabolic Diseases

Developmental Abnormalities

Take-Home Messages

Suggested Reading and Sources

Test Your Knowledge



# / Radiology of Bone Tumours and the Roles of the Radiologist

## / Musculoskeletal Imaging

### CHAPTER OUTLINE:

Imaging Anatomy

Strengths, Weaknesses and Roles of Imaging Modalities

Arthropathies

Fractures and Dislocations

Infection

**Tumours and Tumour-like Conditions**

/ Role of Radiology

Metabolic Diseases

Developmental Abnormalities

Take-Home Messages

Suggested Reading and Sources

Test Your Knowledge

### <=> ATTENTION

The role of the radiologist in bone tumours is manifold: to identify and characterise tumours, to plan (and perform) biopsy, to help stage and (sometimes) treat tumours, to assess treatment response and to follow up (Figure 95).

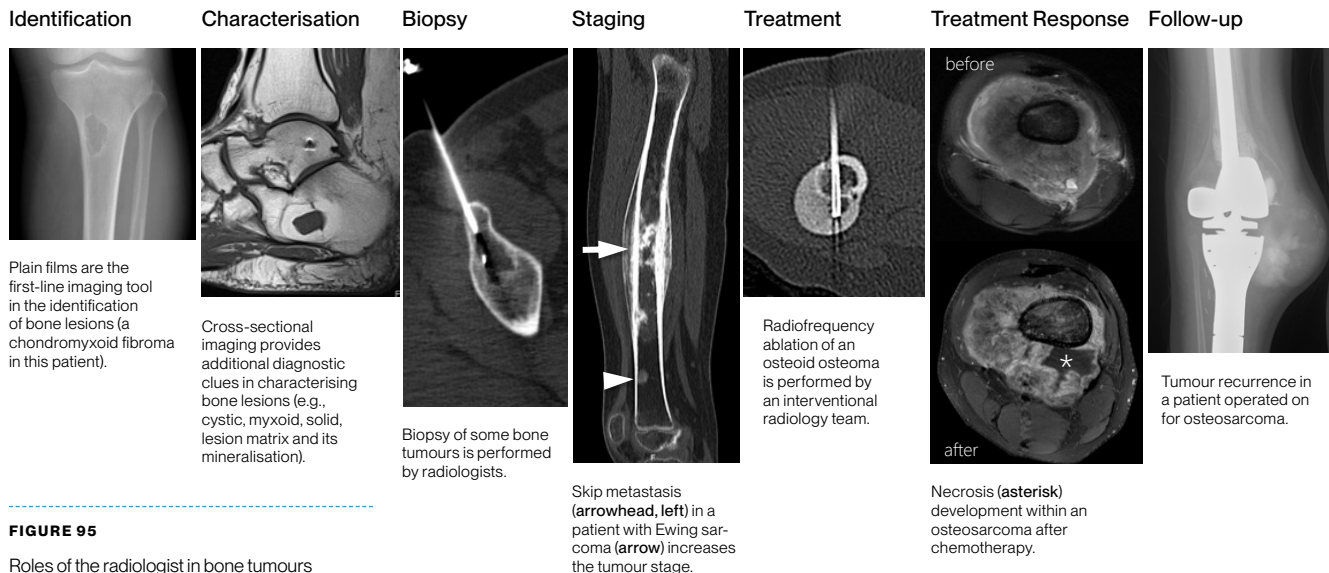


FIGURE 95

Roles of the radiologist in bone tumours



# / Patient Age and Location of Tumours

## <|> ATTENTION

Patient age is the key demographic factor in bone tumours. Along with lesion location across the body and within a bone, it greatly helps to narrow down the differential diagnostic possibilities (Figure 96). When

attempting to diagnose bone tumours, it is helpful to remember the adage from real estate business, “Location is everything”, which, although not absolute, frequently holds true.

## >< FURTHER KNOWLEDGE

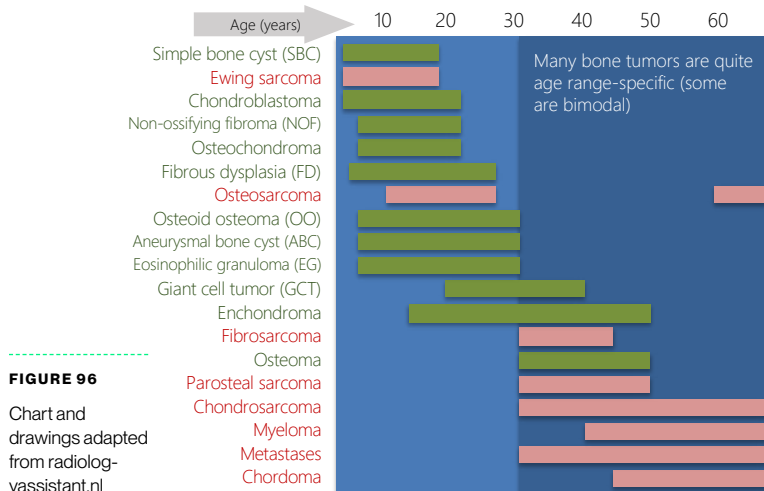
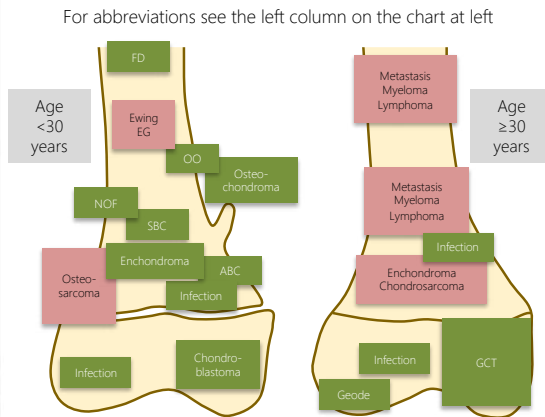


FIGURE 96

Chart and drawings adapted from radiology-assistant.nl



## / Musculoskeletal Imaging

### CHAPTER OUTLINE:

Imaging Anatomy

Strengths, Weaknesses and Roles of Imaging Modalities

Arthropathies

Fractures and Dislocations

Infection

**Tumours and Tumour-like Conditions**

/ Patient Age and Location of Tumours

Metabolic Diseases

Developmental Abnormalities

Take-Home Messages

Suggested Reading and Sources

Test Your Knowledge

## / Lesion Borders

## &lt;=&gt; ATTENTION

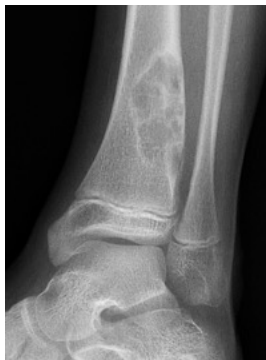Sclerotic borders generally imply the successful attempt of the body to contain a lesion. Conversely, ill-defined contours and a wide zone of transition on radiographs hint at an aggressive lesion (malignant

or due to a highly virulent microorganism). Permeative or moth-eaten pattern of bone involvement also suggests aggressiveness. See **Figure 97**.

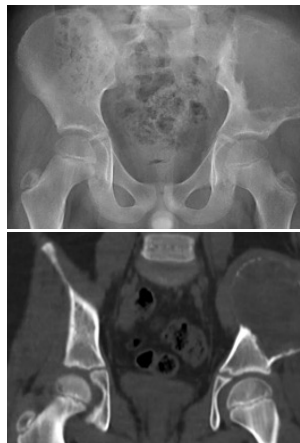## &gt;=&lt; FURTHER KNOWLEDGE

**FIGURE 97**

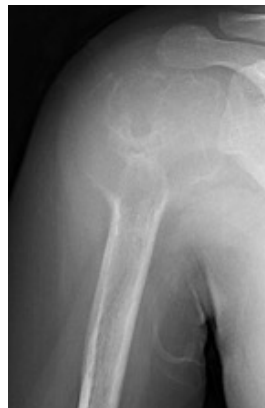Examples of various types of lesion borders

**Non-ossifying fibroma**

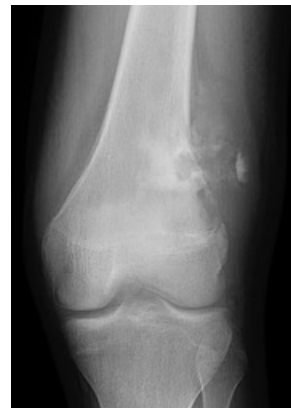Thin sclerotic borders in a mixed lytic and sclerotic lesion involving the distal tibial metadiaphysis in an 11-year-old girl

**Aneurysmal bone cyst**

Narrow zone of transition and thin sclerotic borders of an expansile lytic left iliac lesion in a 7-year-old boy

**Giant cell tumor**

Indistinct borders and wider zone of transition of a lytic expansile lesion involving the proximal humeral epiphysis and metaphysis in a 19-year-old girl

**Osteosarcoma**

Indistinct borders (a wide zone of transition) of a mixed lytic-sclerotic lesion at the distal femoral metadiaphysis in a 15-year-old boy

## CHAPTER OUTLINE:

Imaging Anatomy

Strengths, Weaknesses and Roles of Imaging Modalities

Arthropathies

Fractures and Dislocations

Infection

**Tumours and Tumour-like Conditions**

/ Lesion Borders

Metabolic Diseases

Developmental Abnormalities

Take-Home Messages

Suggested Reading and Sources

Test Your Knowledge

## / Lesion Matrix and its Mineralisation

## &lt;=&gt; ATTENTION

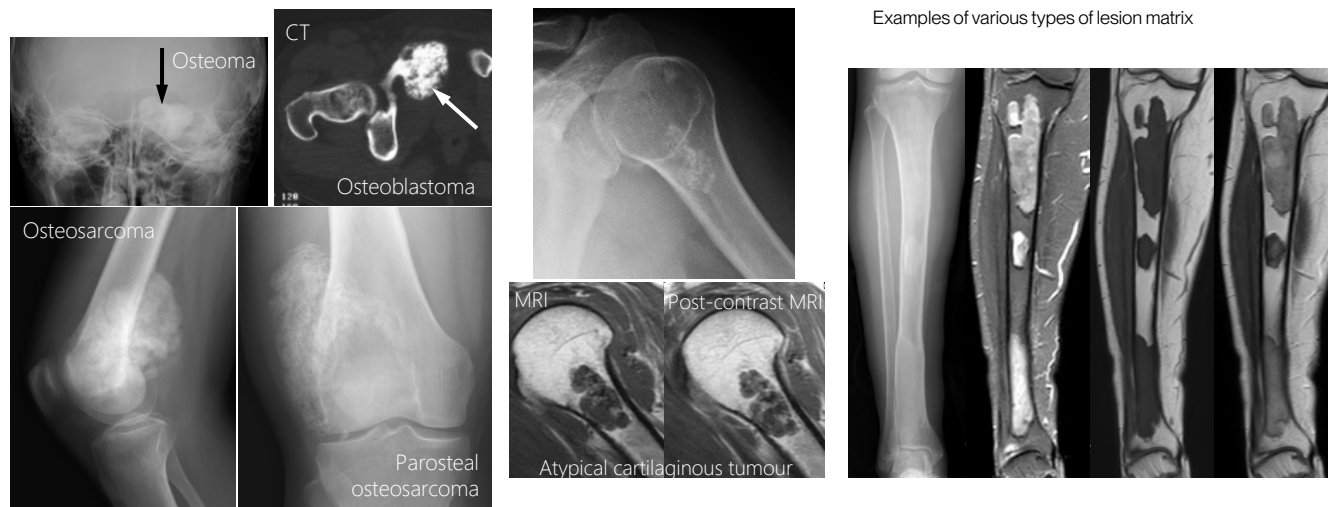Many bone lesions have an underlying matrix, which can become mineralised. Different types of matrix (and their mineralisation), which are

usually discernible on radiological imaging, point to different groups of lesions (Figure 98).

## &gt;=&lt; FURTHER KNOWLEDGE

FIGURE 98

Examples of various types of lesion matrix

**Osteoid matrix**

Marble-/cloud-like or ill-defined amorphous densities are characteristic in osteoid producing lesions

**Cartilaginous matrix**

Focal stippled or flocculent densities or "rings and arcs" of calcifications or enhancement are seen in cartilage producing lesions

**Fibrous matrix**

A ground-glass matrix is characteristic for fibrous dysplasia. Second through fourth images: MRI, the image on the far right is a post-contrast image.

## CHAPTER OUTLINE:

Imaging Anatomy

Strengths, Weaknesses and Roles of Imaging Modalities

Arthropathies

Fractures and Dislocations

Infection

**Tumours and Tumour-like Conditions**

/ Lesion Matrix and Its Mineralisation

Metabolic Diseases

Developmental Abnormalities

Take-Home Messages

Suggested Reading and Sources

Test Your Knowledge

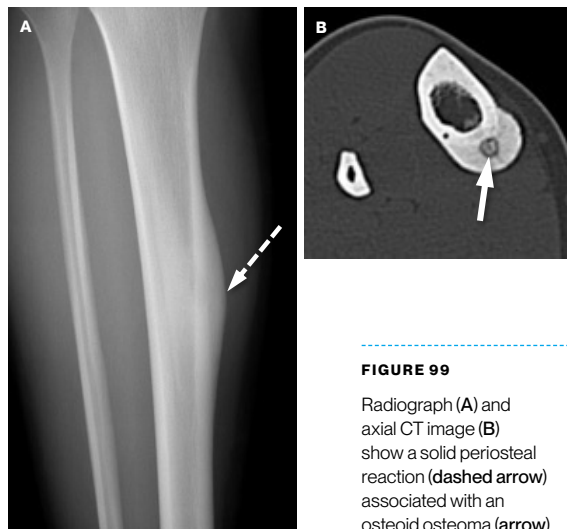
# / Periosteal Reaction

Periosteal reaction associated with a lesion gives important clues regarding its behaviour. Benign (or less aggressive) lesions tend to show a **solid periosteal reaction** (Figure 99), whereas more aggressive lesions display **lamellated** (Figure 100) or spiculated periosteal reaction (Figure 101) or the so-called “Codman triangle”

(Figure 102), which denotes disruption of an already lamellated periosteal reaction by aggressively invading tumour.

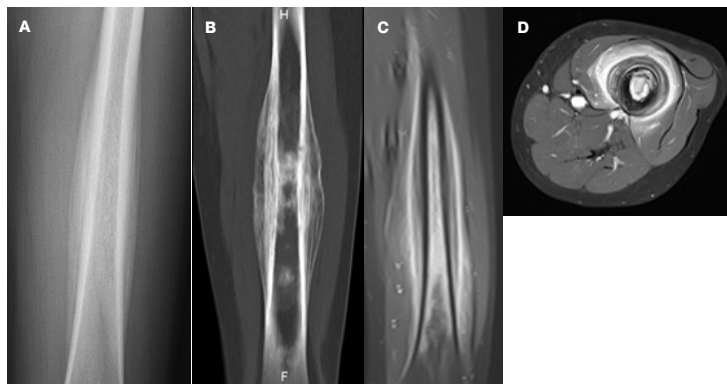## <=> ATTENTION

More than one type of aggressive periosteal reaction can be seen simultaneously



**FIGURE 99**

Radiograph (A) and axial CT image (B) show a solid periosteal reaction (dashed arrow) associated with an osteoid osteoma (arrow)



**FIGURE 100**

Radiograph (A), coronal CT reformation (B) and coronal (C) and axial (D) MR images show a lamellated (onion skin) periosteal reaction associated with a Ewing sarcoma

### CHAPTER OUTLINE:

Imaging Anatomy

Strengths, Weaknesses and Roles of Imaging Modalities

Arthropathies

Fractures and Dislocations

Infection

**Tumours and Tumour-like Conditions**

/ Periosteal Reaction

Metabolic Diseases

Developmental Abnormalities

Take-Home Messages

Suggested Reading and Sources

Test Your Knowledge

**CHAPTER OUTLINE:**

Imaging Anatomy

Strengths, Weaknesses  
and Roles of Imaging  
Modalities

Arthropathies

Fractures and  
Dislocations

Infection

**Tumours and Tumour-  
like Conditions**

/ Periosteal Reaction

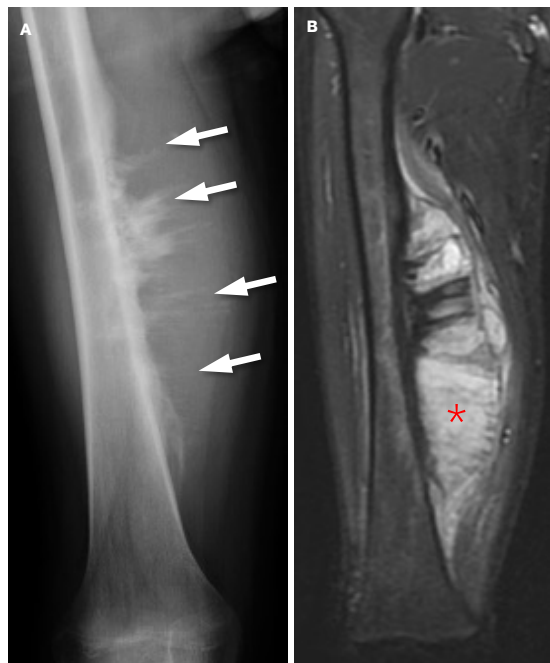Metabolic Diseases

Developmental  
Abnormalities

Take-Home Messages

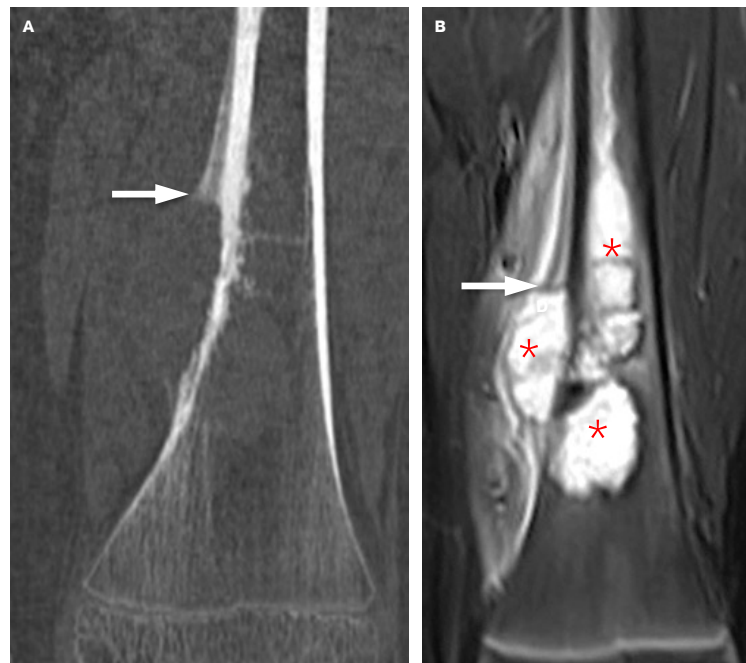
Suggested Reading  
and Sources

Test Your Knowledge



**FIGURE 101**

Radiograph (A) and MRI (B) show spiculated periosteal reaction (arrows) associated with an osteosarcoma (asterisk)



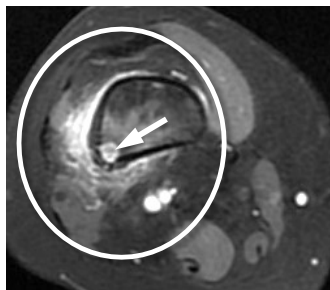
**FIGURE 102**

Coronal CT reformation (A) and MRI (B) show a Codman triangle (arrows) associated with an osteosarcoma (asterisks)

# / Characteristic Imaging Features

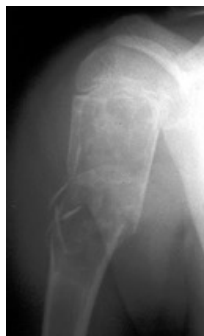Some bone tumours have characteristic, if not pathognomonic, radiological findings that greatly help in their diagnosis (**Figure 103**).

Reactive bone and soft tissue inflammation surrounding an active osteoid osteoma



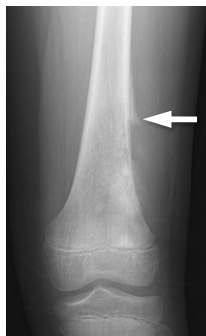Osteoid osteomas (OO) release prostaglandins and elicit significant reactive inflammation (hence their marked response to salicylates/antiprostaglandins), which is readily shown on fluid-sensitive MR images (note the OO nidus [arrow] within the circle that highlights such reaction)

“Fallen fragment” sign in solitary bone cyst



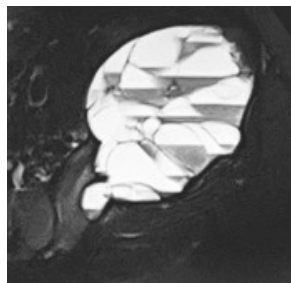
This is actually a pathological fracture in the background of a benign lesion

Codman triangle



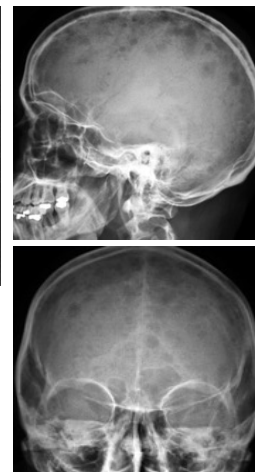
It shows the aggressiveness of the lesion, usually an osteosarcoma or, less commonly, osteomyelitis

Fluid-fluid levels



Fluid-fluid (or blood) levels are seen in some lesions such as aneurysmal bone cyst (above, transverse MR image of a left iliac lesion) and telangiectatic osteosarcoma

“Punched-out” lesions in multiple myeloma



## CHAPTER OUTLINE:

Imaging Anatomy

Strengths, Weaknesses and Roles of Imaging Modalities

Arthropathies

Fractures and Dislocations

Infection

**Tumours and Tumour-like Conditions**

/ Characteristic Imaging Features

Metabolic Diseases

Developmental Abnormalities

Take-Home Messages

Suggested Reading and Sources

Test Your Knowledge

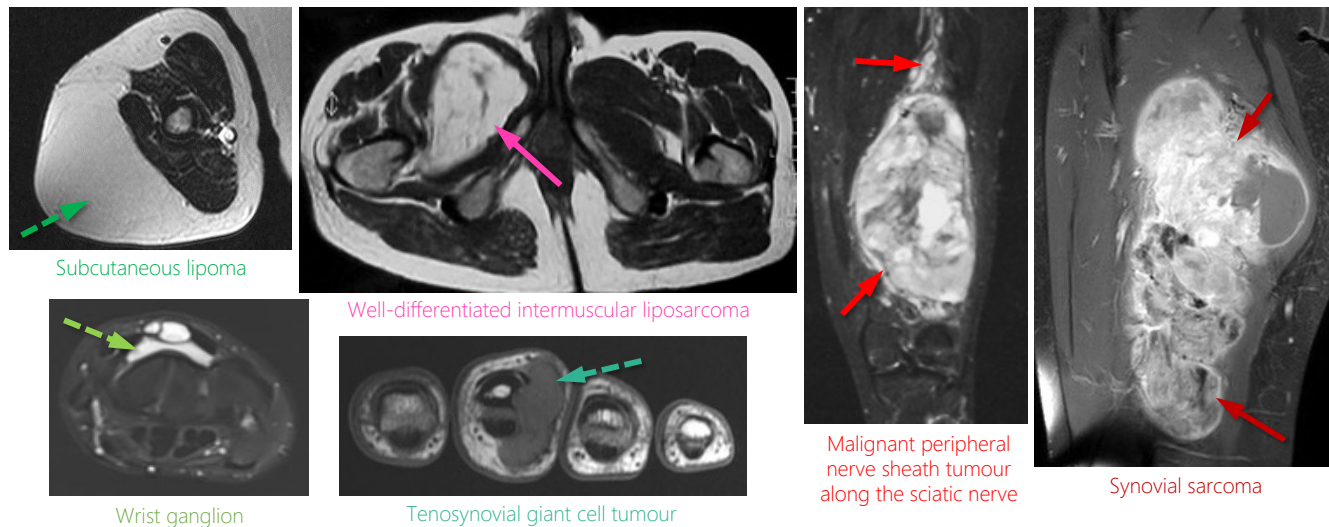
**FIGURE 103**

Examples of characteristic imaging findings in some bone tumours

# / Radiology of Soft Tissue Tumours

On imaging, a soft tissue mass with well-defined margins is **not necessarily** benign. Smaller ( $\leq 5$  cm) and superficial (versus deep-seated) lesions are more likely benign. Ganglion cysts and lipomas are the most common soft tissue masses. Ultrasonography is useful in discriminating solid versus cystic lesions and further characterising some solid lesions. The best combination of "MRI plus radiographs" provides specific diagnosis in only about 30%–50% of cases.

MRI is the modality of choice to show compartmental involvement, which is important in staging and to plan the route for biopsy, which is usually performed under US or CT guidance. Examples of soft tissue tumours as seen on MRI are shown in **Figure 104**.



**FIGURE 104**

Examples of benign (dashed arrows) and malignant (arrows) soft tissue tumours as depicted by MRI.

## / Musculo-skeletal Imaging

### CHAPTER OUTLINE:

#### Imaging Anatomy

#### Strengths, Weaknesses and Roles of Imaging Modalities

#### Arthropathies

#### Fractures and Dislocations

#### Infection

#### Tumours and Tumour-like Conditions

#### / Soft Tissue Tumours

#### Metabolic Diseases

#### Developmental Abnormalities

#### Take-Home Messages

#### Suggested Reading and Sources

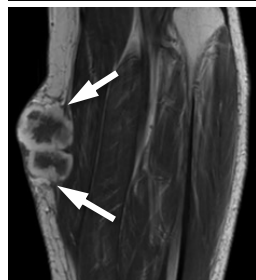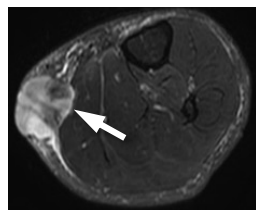
#### Test Your Knowledge



# / Radiology of Soft Tissue Tumours

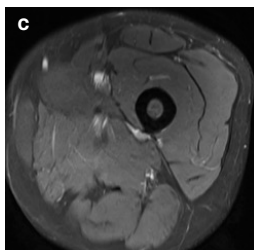
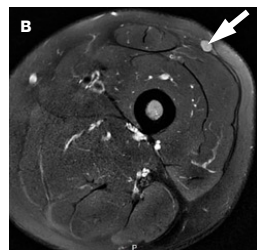
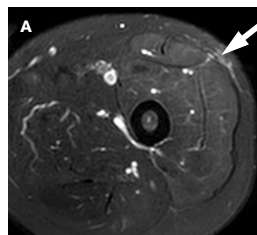
For subcutaneous lesions, **relation with the peripheral muscular fascia** (see **Figure 11**) is important. While a preserved fascial plane between a subcutaneous mass lesion and the peripheral fascia is no guarantee of a benign histology, fascial violation by the mass lesion is a clear sign of aggressive behaviour (**Figure 105**). MRI is the best imaging modality in the follow-up of malignant

soft tissue masses (**Figure 106**). Some properties of mass lesions such as internal haemorrhage or melanin content can also be identified on MRI (**Figure 107**).



**FIGURE 105**

Violation of the peripheral fascia (arrows) is a clear sign of malignancy in this myxofibrosarcoma.

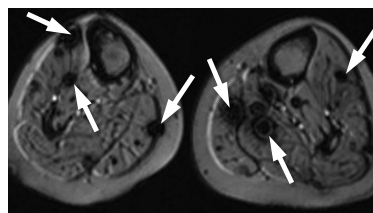


**FIGURE 106**

This patient was operated on for a subcutaneous mass that turned out to be an undifferentiated pleomorphic sarcoma (not shown). Postsurgical changes are evident in the first MRI shortly after surgery (arrow, A). Ten weeks later, a new soft tissue mass was identified (arrow, B), which was excised and confirmed to be local recurrence. Follow-up MRI four months later (C) was free of neoplastic masses.

**FIGURE 107**

Arrows point to some of the extensive haemorrhagic calf muscle metastases from an alveolar soft part sarcoma in this special MRI sequence called “susceptibility-weighted imaging”. Within the MRI machine, which features a strong magnetic field, the paramagnetic property of iron content from hemosiderin (due to haemorrhage) makes these so-called “blooming” artifacts (arrows) and thereby highlights bleeding.



## / Musculoskeletal Imaging

### CHAPTER OUTLINE:

Imaging Anatomy

Strengths, Weaknesses and Roles of Imaging Modalities

Arthropathies

Fractures and Dislocations

Infection

**Tumours and Tumour-like Conditions**

/ Soft Tissue Tumours

Metabolic Diseases

Developmental Abnormalities

Take-Home Messages

Suggested Reading and Sources

Test Your Knowledge

**CHAPTER OUTLINE:**

Imaging Anatomy

Strengths, Weaknesses  
and Roles of Imaging  
Modalities

Arthropathies

Fractures and  
Dislocations

Infection

Tumours and Tumour-  
like Conditions

**Metabolic Diseases**

Developmental  
Abnormalities

Take-Home Messages

Suggested Reading  
and Sources

Test Your Knowledge

# / Metabolic Diseases

# / Metabolic Diseases

The musculoskeletal system is the most bulky organ array in the human body. Because bone is a metabolically active tissue with a continuous cycle of synthesis and resorption, numerous metabolic conditions can affect not only the developing skeleton but also its final form in adults. Radiology of only a few select conditions are overviewed in this chapter:

- / **Osteoporosis** (= decreased total bone mass due to decreased size of bone trabeculae and cortical bone thinning; the bone is otherwise structurally normal)
- / **Osteomalacia** (osteoid = fails to undergo normal mineralisation because of vitamin D deficiency or other causes of calcium depletion)

- / **Rickets** (= “childhood-equivalent” of osteomalacia)
- / **Hyperparathyroidism** (= increased osteoclastic bone erosion because of excessive parathormone secretion due to a parathyroid adenoma or parathyroid hyperplasia)
- / **Renal osteodystrophy** (= different patterns of bone abnormalities associated with chronic kidney disease)

## CHAPTER OUTLINE:

Imaging Anatomy

Strengths, Weaknesses  
and Roles of Imaging  
Modalities

Arthropathies

Fractures and  
Dislocations

Infection

Tumours and Tumour-  
like Conditions

## Metabolic Diseases

Developmental  
Abnormalities

Take-Home Messages

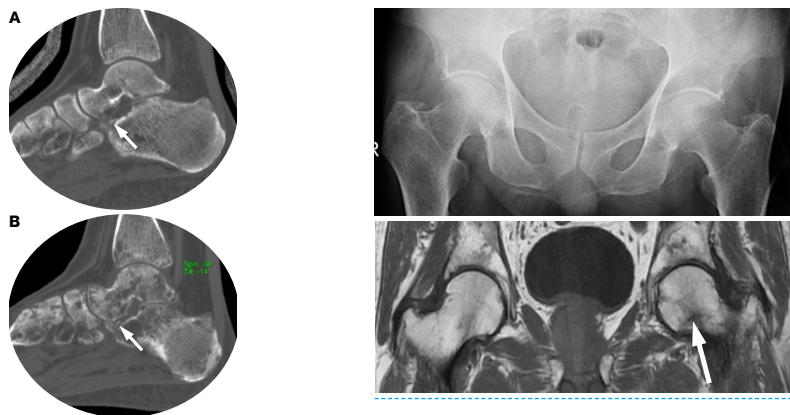
Suggested Reading  
and Sources

Test Your Knowledge

# / Osteoporosis: The Most Common Metabolic Bone Disease

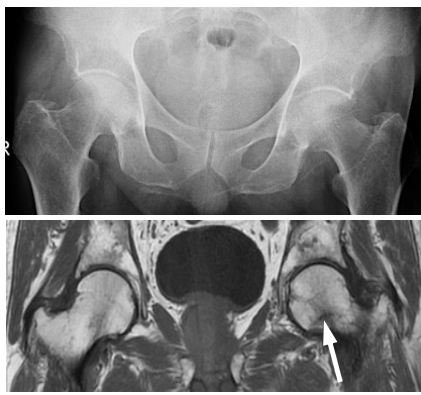
Osteoporosis is characterised by diminished but otherwise normal bone. It may be a local phenomenon (e.g., disuse osteoporosis, **Figure 108**) as well as a generalised condition (**Figure 109**). The World Health

Organization defines osteoporosis as a dual-energy X-ray absorptiometry-based (DEXA) T-score less than -2.5 standard deviations (SD) of young healthy adults (**Figure 110**). **Osteopenia** is a mild form of osteoporosis.



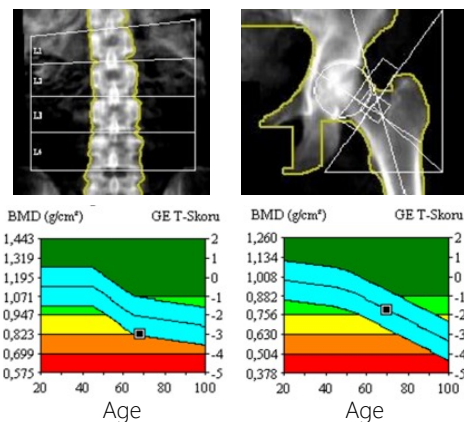
**FIGURE 108**

Disuse osteopenia on CT 5 weeks (A) and 15 weeks (B) after the initial injury in a 25-year-old woman with a sustentaculum tali fracture (arrows).



**FIGURE 109**

Hip fracture is the most dreaded complication of senile osteoporosis. Incomplete insufficiency fracture of the left femoral neck (arrow) in this 71-year-old man with osteoporosis was best shown on same-day MRI. A "hip" fracture denotes fracture of the proximal quarter of the femur.



**FIGURE 110**

DEXA in a 70-year-old woman shows osteoporosis in the spine and osteopenia in the femoral neck.

## CHAPTER OUTLINE:

Imaging Anatomy

Strengths, Weaknesses  
and Roles of Imaging  
Modalities

Arthropathies

Fractures and  
Dislocations

Infection

Tumours and Tumour-  
like Conditions

**Metabolic Diseases**

/ Osteoporosis

Developmental  
Abnormalities

Take-Home Messages

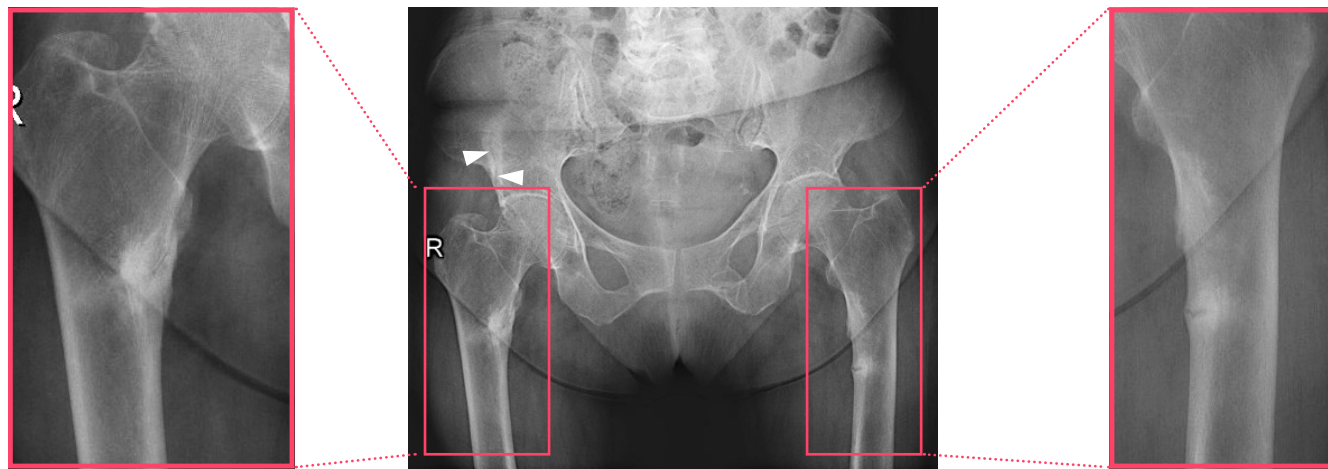
Suggested Reading  
and Sources

Test Your Knowledge

# / Osteomalacia

Occurring **after the cessation of growth**, osteomalacia, in contradistinction to rickets, does **not** predominantly involve growth plates. Inadequate or abnormal mineralisation of trabecular and cortical bone is observed. Patients typically present with insufficiency fractures,

formerly known as Looser zones (**Figure 111**). Large quantities of unmineralised osteoid are observed as indistinct/ill-defined trabeculae giving the impression of a “poor-quality” radiograph (**Figure 111**).



**FIGURE 111**

Looser zones along the bilateral medial femoral cortices, as well as in the right iliac bone (**arrowheads**), are present in this 74-year-old woman with osteomalacia. Large quantities of unmineralised osteoid are observed as indistinct/ill-defined trabeculae (especially in the diaphyses here).

## / Musculo-skeletal Imaging

### CHAPTER OUTLINE:

Imaging Anatomy

Strengths, Weaknesses and Roles of Imaging Modalities

Arthropathies

Fractures and Dislocations

Infection

Tumours and Tumour-like Conditions

### Metabolic Diseases

/ Osteomalacia

Developmental Abnormalities

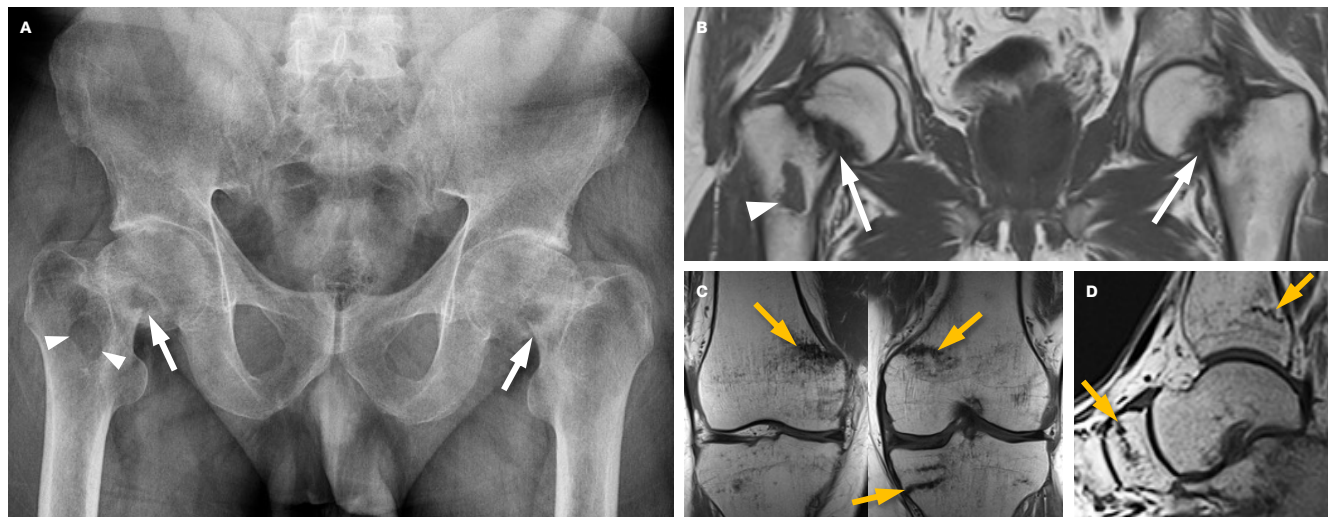
Take-Home Messages

Suggested Reading and Sources

Test Your Knowledge

## &lt;=&gt; ATTENTION

Osteomalacia can also have an oncogenic aetiology (Figure 112). This occurs when tumours secrete substances that inhibit the ability of kidney to absorb phosphate.



**FIGURE 112**

Radiograph (A) and cross-sectional images from different MRI examinations of the hips (B), knees (C) and ankle (D). This 53-year-old man had hypophosphatemia secondary to a biopsy-proven phosphaturic mesenchymal tumour in the right proximal femur (arrowheads in A and B), resulting in osteomalacia. Note bilateral femoral neck insufficiency fractures (white arrows) and indistinct/ill-defined trabeculae (representing extensive unmineralised osteoid), giving the impression of a "poor-quality" radiograph. The patient had insufficiency fractures (yellow arrows) also around his both knees and one ankle.

## Musculo-skeletal Imaging

### CHAPTER OUTLINE:

Imaging Anatomy

Strengths, Weaknesses and Roles of Imaging Modalities

Arthropathies

Fractures and Dislocations

Infection

Tumours and Tumour-like Conditions

### Metabolic Diseases

/ Osteomalacia

Developmental Abnormalities

Take-Home Messages

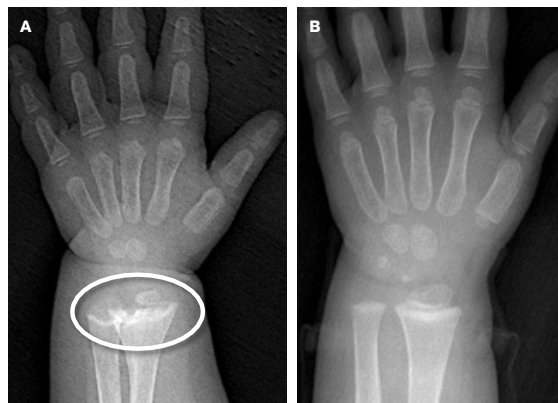
Suggested Reading and Sources

Test Your Knowledge

# / Rickets

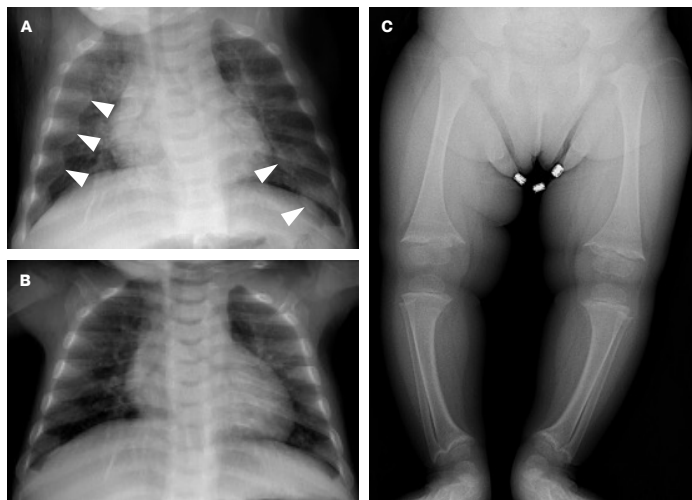
In rickets, the orderly development and mineralisation of growth plates is interrupted (**Figures 113 and 114**). Imaging findings are seen on the metaphyseal

side of the growth plate because of the concentration of unmineralized osteoid there (**Figure 113**).



**FIGURE 113**

Metaphyseal widening, cupping and fraying in the distal radius and ulna (**ellipse**) of a 15-month-old girl with rickets (**A**) resolved after treatment (**B**).



**FIGURE 114**

Rachitic rosary (**arrowheads** in **A**) denoting rib widening at the costochondral junctions in a 16-month-old girl with rickets resolved after treatment (**B**). Note bowing deformity of the lower extremities with metaphyseal flaring and fraying before treatment (**C**).

## CHAPTER OUTLINE:

Imaging Anatomy

Strengths, Weaknesses  
and Roles of Imaging  
Modalities

Arthropathies

Fractures and  
Dislocations

Infection

Tumours and Tumour-  
like Conditions

**Metabolic Diseases**

/ Rickets

Developmental  
Abnormalities

Take-Home Messages

Suggested Reading  
and Sources

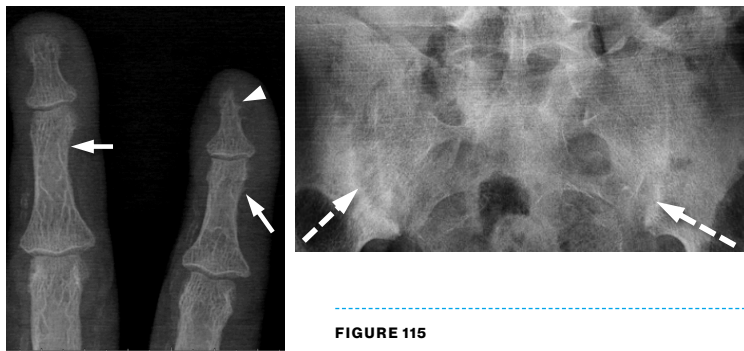
Test Your Knowledge



# / Renal Osteodystrophy

Renal osteodystrophy encompasses findings seen in the setting of **chronic renal insufficiency**. Among these are findings of osteomalacia (and rickets in children) and secondary hyperparathyroidism (**Figures 115 and 116**).

Skeletal imaging findings in osteomalacia/rickets and hyperparathyroidism are **independent from the aetiology** of these three conditions.

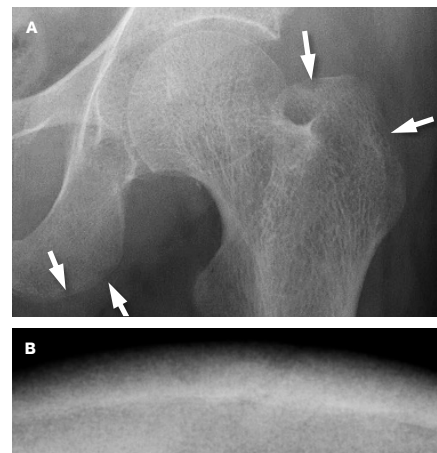


**FIGURE 115**

This 50-year-old man with chronic renal insufficiency and secondary hyperparathyroidism has subperiosteal bone resorption (**arrows**) at the radial aspects of the second and third middle phalanges and subchondral resorption (**dashed arrows**) in bilateral sacroiliac joints resulting in pseudo-widening. Note also acro-osteolysis in the second distal phalangeal tuft (**arrowhead**) and extensive vascular calcifications along fingers.

## <=> ATTENTION

**Radiologic findings of bone resorption are seen in hyperparathyroidism regardless of primary, secondary or tertiary type**



**FIGURE 116**

Subtendinous bone resorption (**arrows**) at the insertion sites of gluteus medius, minimus and hamstring tendons and trabecular paucity (**A and B**) because of cancellous bone resorption (**B** is an edge-on radiograph of the skull).

## / Musculoskeletal Imaging

### CHAPTER OUTLINE:

Imaging Anatomy

Strengths, Weaknesses and Roles of Imaging Modalities

Arthropathies

Fractures and Dislocations

Infection

Tumours and Tumour-like Conditions

### Metabolic Diseases

/ Renal Osteodystrophy

Developmental Abnormalities

Take-Home Messages

Suggested Reading and Sources

Test Your Knowledge

## / Renal Osteodystrophy: An Overlap of Osteomalacia/Rickets and Hyperparathyroidism

- Although findings in osteomalacia/rickets and hyperparathyroidism **tend to overlap**, radiographic findings of hyperparathyroidism predominate in adults, whereas those of rickets are in the foreground in children.
- The **“rugger jersey spine”** appearance (named after the pattern of horizontal stripes on jerseys worn by rugby players), denoting alternating bands of sclerosis along the vertebral body endplates and areas of lucency centrally is a characteristic feature of secondary hyperparathyroidism seen in renal osteodystrophy (Figure 117).
- Soft tissue mineralisation** (in the form of vascular calcifications, chondrocalcinosis and tumoral calcinosis) is a characteristic feature of renal osteodystrophy (Figure 118).
- Parathyroid adenomas** are seen in the primary and tertiary forms of hyperparathyroidism. Ultrasonography is used to detect parathyroid adenomas (Figure 119).

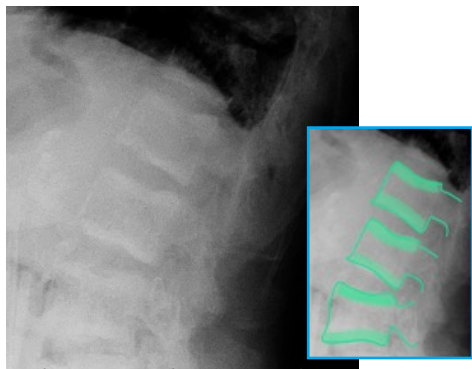


FIGURE 117

“Rugger jersey spine” appearance in a 55-year-old woman with end stage renal disease.

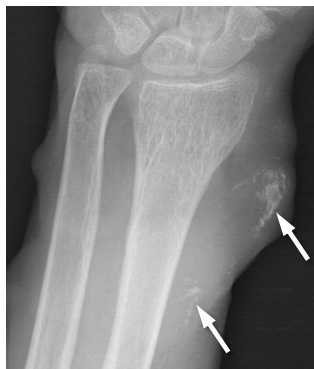

FIGURE 118

Soft tissue calcifications (arrows) in a 50-year-old man with chronic renal failure.

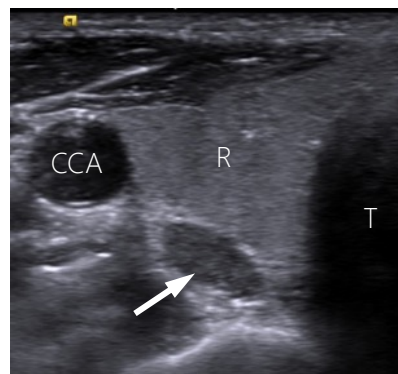


FIGURE 119

Ultrasonography (transverse image) shows a parathyroid adenoma (arrow) in a 36-year-old woman. Right lobe of the thyroid gland (R), right common carotid artery (CCA), trachea (T).

### CHAPTER OUTLINE:

Imaging Anatomy

Strengths, Weaknesses  
and Roles of Imaging  
Modalities

Arthropathies

Fractures and  
Dislocations

Infection

Tumours and Tumour-  
like Conditions

Metabolic Diseases

/ Renal  
Osteodystrophy

Developmental  
Abnormalities

Take-Home Messages

Suggested Reading  
and Sources

Test Your Knowledge

**CHAPTER OUTLINE:**

Imaging Anatomy

Strengths, Weaknesses  
and Roles of Imaging  
Modalities

Arthropathies

Fractures and  
Dislocations

Infection

Tumours and Tumour-  
like Conditions

Metabolic Diseases

**Developmental  
Abnormalities**

Take-Home Messages

Suggested Reading  
and Sources

Test Your Knowledge

# / Developmental Abnormalities

# / Developmental Abnormalities

**CHAPTER OUTLINE:****Imaging Anatomy**

Strengths, Weaknesses  
and Roles of Imaging  
Modalities

Arthropathies

Fractures and  
Dislocations

Infection

Tumours and Tumour-  
like Conditions

Metabolic Diseases

**Developmental  
Abnormalities**

Take-Home Messages

Suggested Reading  
and Sources

Test Your Knowledge

Several examples of the numerous developmental abnormalities that can involve the musculoskeletal system are:

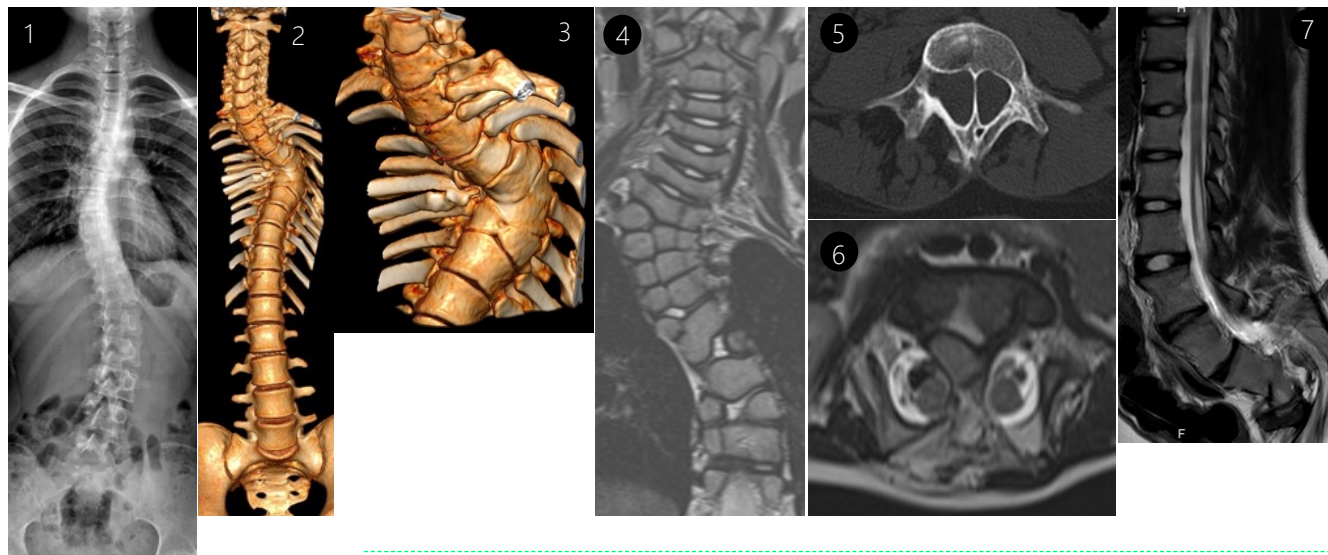
- / Scoliosis (one of the etiologic factors in scoliosis is developmental dysplasia)
- / Developmental dysplasia of the hip
- / Femoral trochlear hypoplasia/dysplasia
- / Glenohumeral dysplasia

Radiology not only brings diagnostic clues to developmental abnormalities but also provides information regarding the severity, outcome assessment and management follow-up of these conditions. Angular, point-to-point or projectional distance measurements on radiologic images are used for acquiring such information.

# / Imaging in Scoliosis

Developmental dysplasia is only one of the causes of scoliosis, the most common type of which (i.e., adolescent idiopathic scoliosis, not shown here) remains

of unknown aetiology. Radiographs, CT and MRI are widely used for the diagnosis and treatment planning, as well as follow-up of scoliosis (Figure 120).



**FIGURE 120**

Radiographs (1), CT (2, 3, 5) and MRI (4, 6, 7) show scoliosis (1) and associated abnormalities, such as hemivertebra, block vertebra, butterfly vertebra (2–4), diastematomyelia (5, 6), tethered cord and syringomyelia (7) and caudal regression syndrome (7).

## CHAPTER OUTLINE:

### Imaging Anatomy

Strengths, Weaknesses  
and Roles of Imaging  
Modalities

Arthropathies

Fractures and  
Dislocations

Infection

Tumours and Tumour-  
like Conditions

Metabolic Diseases

### Developmental Abnormalities

/ Scoliosis

Take-Home Messages

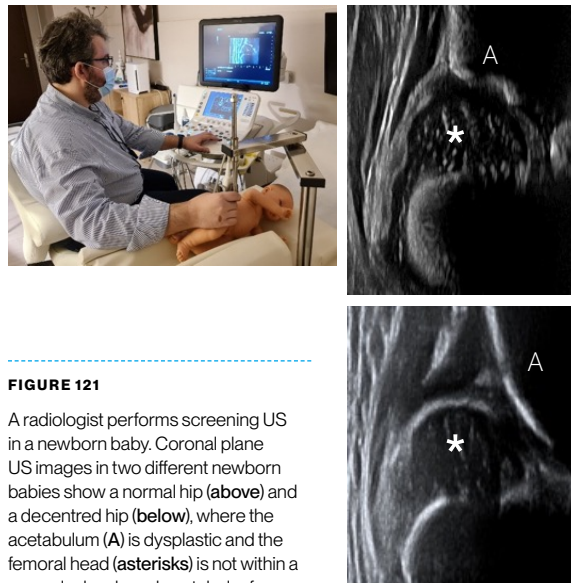
Suggested Reading  
and Sources

Test Your Knowledge

# / Imaging in Developmental Dysplasia of the Hip (DDH)

Ultrasonography is an excellent tool in screening for developmental dysplasia of the hip (DDH), which is recommended to take place as early as

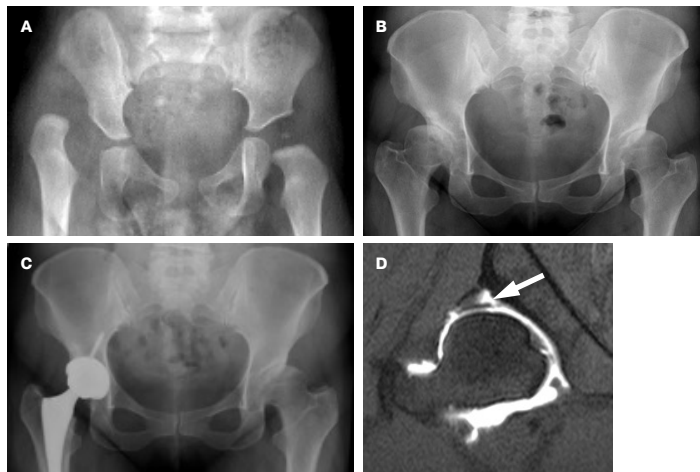
possible – but no later than the first six weeks after delivery (**Figure 121**). If untreated, DDH can progress to early-onset hip osteoarthritis (**Figure 122**).



**FIGURE 121**

A radiologist performs screening US in a newborn baby. Coronal plane US images in two different newborn babies show a normal hip (**above**) and a decentred hip (**below**), where the acetabulum (**A**) is dysplastic and the femoral head (**asterisks**) is not within a properly developed acetabular fossa.

Ultrasonography images courtesy of Dr Konstantinos Chlapoutakis, Heraklion, Crete, Greece



**FIGURE 122**

Radiographs show an infant with DDH on the right side (**A**) and a 37-year-old woman with DDH on both sides (**B**). The woman developed early-onset osteoarthritis and had a total hip replacement four years later (**C**). MR-arthrography image of the same woman (**D**) shows a thickened acetabular labrum with a tear (**arrow**).

## CHAPTER OUTLINE:

### Imaging Anatomy

Strengths, Weaknesses  
and Roles of Imaging  
Modalities

Arthropathies

Fractures and  
Dislocations

Infection

Tumours and Tumour-  
like Conditions

Metabolic Diseases

### Developmental Abnormalities

/ Developmental  
Dysplasia of the Hip

Take-Home Messages

Suggested Reading  
and Sources

Test Your Knowledge

# / Take-Home Messages

- / Sufficient and relevant clinical information needs to be given to the radiologist by the referring clinician in order to provide the best service to the patient, which encompasses the validation or determination of the best imaging modality and technique and evaluation of the imaging study.
- / First-line diagnostic modality in musculoskeletal (MSK) imaging is radiography.
- / Computed tomography (CT) is usually reserved for the identification and better characterisation of some fractures, assessment of bone lesions in complex anatomic areas and estimation of the mineral load in gout.
- / In the MSK system, ultrasonography (US) is mainly used in the evaluation of superficial structures.
- / Magnetic resonance imaging (MRI) is an excellent tool for imaging soft tissues, joints and bone marrow—including occult fractures.
- / An algorithmic approach starting with the identification of joint space narrowing on radiographs is useful in many arthropathies.
- / After trauma, lipohaemarthrosis on imaging suggests that an intra-articular fracture is present.
- / Imaging closely reflects pathophysiology in osteomyelitis—but should not delay joint fluid aspiration and microbiologic assessment in suspected septic arthritis.
- / Location across the body and site within a bone are, along with the patient's age, the key determinants of a bone tumour.

## / Musculoskeletal Imaging

### CHAPTER OUTLINE:

Imaging Anatomy

Strengths, Weaknesses and Roles of Imaging Modalities

Arthropathies

Fractures and Dislocations

Infection

Tumours and Tumour-like Conditions

Metabolic Diseases

Developmental Abnormalities

### Take-Home Messages

Suggested Reading and Sources

Test Your Knowledge



- / Many aggressive bone lesions have indistinct margins on radiographs.
- / A soft tissue mass with well-defined (distinct) margins on imaging is not necessarily benign.
- / Biopsy of MSK lesions needs to be performed within the framework of compartmental anatomy.
- / As the largest array of organs in the human body, the MSK system gives clues on imaging to many metabolic diseases.
- / Imaging is essential in many generalised or focal developmental abnormalities.

**Musculo-  
skeletal  
Imaging**

**CHAPTER OUTLINE:**

Imaging Anatomy

Strengths, Weaknesses  
and Roles of Imaging  
Modalities

Arthropathies

Fractures and  
Dislocations

Infection

Tumours and Tumour-  
like Conditions

Metabolic Diseases

Developmental  
Abnormalities

**Take-Home Messages**

Suggested Reading  
and Sources

Test Your Knowledge

# / Suggested Reading and Sources

## / Musculoskeletal Imaging

### CHAPTER OUTLINE:

Imaging Anatomy

Strengths, Weaknesses  
and Roles of Imaging  
Modalities

Arthropathies

Fractures and  
Dislocations

Infection

Tumours and Tumour-  
like Conditions

Metabolic Diseases

Developmental  
Abnormalities

Take-Home Messages

**Suggested Reading  
and Sources**

Test Your Knowledge

- / Helms CA. Fundamentals of Skeletal Radiology. 5th edition. Philadelphia: Elsevier, 2020
- / Major NM, Anderson MW, Helms CA, Kaplan PA, Dussault R, eds. Musculoskeletal MRI. 3rd edition. Philadelphia: Elsevier, 2020
- / Herring W. Learning Radiology: Recognizing the Basics. 4th edition. Philadelphia: Elsevier, 2020
- / Jacobson JA et al. Radiographic evaluation of arthritis: degenerative joint disease and variations. Radiology 2008; 248:737–747
- / Jacobson JA et al. Radiographic evaluation of arthritis: inflammatory conditions. Radiology 2008; 248:378–389
- / Pathria MN et al. Acute and stress-related injuries of bone and cartilage: pertinent anatomy, basic biomechanics and imaging perspective. Radiology 2016; 280:21–38
- / Aydingöz Ü. Imaging osteomyelitis: an update. Rofo 2023; 195:297–308
- / <https://radiologyassistant.nl/>
- / Wu JS, Hochman MG. Soft-tissue tumors and tumorlike lesions: a systematic imaging approach. Radiology 2009; 253:297–316
- / Chang CY et al. Imaging findings of metabolic bone disease. RadioGraphics 2016; 36:1871–1887
- / O'Beirne JG et al. International Interdisciplinary Consensus Meeting on the Evaluation of Developmental Dysplasia of the Hip. Ultraschall Med 2019; 40:454–464

**CHAPTER OUTLINE:**

Imaging Anatomy

Strengths, Weaknesses  
and Roles of Imaging  
Modalities

Arthropathies

Fractures and  
Dislocations

Infection

Tumours and Tumour-  
like Conditions

Metabolic Diseases

Developmental  
Abnormalities

Take-Home Messages

Suggested Reading  
and Sources

**Test Your Knowledge**

# / Test Your Knowledge

## / Test Your Knowledge

<?> QUESTION

1

Which is the characteristic site of muscle strains?

- ☐ Muscle belly
- ☐ Myotendinous junction
- ☐ Tendon
- ☐ Tendo-osseous junction

**CHAPTER OUTLINE:**

Imaging Anatomy

Strengths, Weaknesses  
and Roles of Imaging  
Modalities

Arthropathies

Fractures and  
Dislocations

Infection

Tumours and Tumour-  
like Conditions

Metabolic Diseases

Developmental  
Abnormalities

Take-Home Messages

Suggested Reading  
and Sources

**Test Your Knowledge**

## / Test Your Knowledge

<?> ANSWER

1

Which is the characteristic site of muscle strains?

- ☐ Muscle belly
- ☒ Myotendinous junction
- ☐ Tendon
- ☐ Tendo-osseous junction

### CHAPTER OUTLINE:

Imaging Anatomy

Strengths, Weaknesses  
and Roles of Imaging  
Modalities

Arthropathies

Fractures and  
Dislocations

Infection

Tumours and Tumour-  
like Conditions

Metabolic Diseases

Developmental  
Abnormalities

Take-Home Messages

Suggested Reading  
and Sources

**Test Your Knowledge**

## / Test Your Knowledge

<?> QUESTION

### 2 Which is the first-line imaging modality to examine joints?

- ☐ Ultrasonography
- ☐ Computed tomography
- ☐ Magnetic resonance imaging
- ☐ Radiography

**CHAPTER OUTLINE:**

Imaging Anatomy

Strengths, Weaknesses  
and Roles of Imaging  
Modalities

Arthropathies

Fractures and  
Dislocations

Infection

Tumours and Tumour-  
like Conditions

Metabolic Diseases

Developmental  
Abnormalities

Take-Home Messages

Suggested Reading  
and Sources

**Test Your Knowledge**

## / Test Your Knowledge

**CHAPTER OUTLINE:**

Imaging Anatomy

Strengths, Weaknesses  
and Roles of Imaging  
Modalities

Arthropathies

Fractures and  
Dislocations

Infection

Tumours and Tumour-  
like Conditions

Metabolic Diseases

Developmental  
Abnormalities

Take-Home Messages

Suggested Reading  
and Sources

**Test Your Knowledge**

<?> ANSWER

### 2 Which is the first-line imaging modality to examine joints?

- ☐ Ultrasonography
- ☐ Computed tomography
- ☐ Magnetic resonance imaging
- ☒ Radiography



# / Test Your Knowledge

**<?> QUESTION**

**3** Punched out erosions with overhanging edges surrounding the 1st metatarsophalangeal joint, along with preservation of joint space width, are characteristic of:

- ☐ Gout
- ☐ Rheumatoid arthritis
- ☐ Psoriatic arthritis
- ☐ Osteoarthritis

**CHAPTER OUTLINE:**

Imaging Anatomy

Strengths, Weaknesses  
and Roles of Imaging  
Modalities

Arthropathies

Fractures and  
Dislocations

Infection

Tumours and Tumour-  
like Conditions

Metabolic Diseases

Developmental  
Abnormalities

Take-Home Messages

Suggested Reading  
and Sources**Test Your Knowledge**

# / Test Your Knowledge

&lt;?&gt; ANSWER

3 Punched out erosions with overhanging edges surrounding the 1st metatarsophalangeal joint, along with preservation of joint space width, are characteristic of:

■ Gout

- ☐ Rheumatoid arthritis
- ☐ Psoriatic arthritis
- ☐ Osteoarthritis

**CHAPTER OUTLINE:**

Imaging Anatomy

Strengths, Weaknesses  
and Roles of Imaging  
Modalities

Arthropathies

Fractures and  
Dislocations

Infection

Tumours and Tumour-  
like Conditions

Metabolic Diseases

Developmental  
Abnormalities

Take-Home Messages

Suggested Reading  
and Sources**Test Your Knowledge**

# / Test Your Knowledge

**<?> QUESTION**

## 4

Which of the following is most likely an insufficiency fracture?

- ☐ Distal femur fracture in a 16-year-old girl following motor vehicle accident
- ☐ Hip fracture in a 72-year-old woman who fell in a bathroom
- ☐ Metatarsal fracture in a newly-recruited 21-year-old soldier
- ☐ Distal radius fracture in an otherwise healthy 34-year-old woman who slipped on ice and fell on her outstretched hand

## Musculo-skeletal Imaging

**CHAPTER OUTLINE:**

Imaging Anatomy

Strengths, Weaknesses  
and Roles of Imaging  
Modalities

Arthropathies

Fractures and  
Dislocations

Infection

Tumours and Tumour-  
like Conditions

Metabolic Diseases

Developmental  
Abnormalities

Take-Home Messages

Suggested Reading  
and Sources

**Test Your Knowledge**

# / Test Your Knowledge

&lt;?&gt; ANSWER

4

Which of the following is most likely an insufficiency fracture?

- ☐ Distal femur fracture in a 16-year-old girl following motor vehicle accident
- ☒ Hip fracture in a 72-year-old woman who fell in a bathroom
- ☐ Metatarsal fracture in a newly-recruited 21-year-old soldier
- ☐ Distal radius fracture in an otherwise healthy 34-year-old woman who slipped on ice and fell on her outstretched hand

**CHAPTER OUTLINE:**

Imaging Anatomy

Strengths, Weaknesses  
and Roles of Imaging  
Modalities

Arthropathies

Fractures and  
Dislocations

Infection

Tumours and Tumour-  
like Conditions

Metabolic Diseases

Developmental  
Abnormalities

Take-Home Messages

Suggested Reading  
and Sources**Test Your Knowledge**

# / Test Your Knowledge

**<?> QUESTION**

**5** Lipohaemarthrosis on a horizontal X-ray beam radiograph denotes that a fracture is:

- ☐ Comminuted
- ☐ Open
- ☐ Intra-articular
- ☐ Displaced

**Musculo-  
skeletal  
Imaging****CHAPTER OUTLINE:**

Imaging Anatomy

Strengths, Weaknesses  
and Roles of Imaging  
Modalities

Arthropathies

Fractures and  
Dislocations

Infection

Tumours and Tumour-  
like Conditions

Metabolic Diseases

Developmental  
Abnormalities

Take-Home Messages

Suggested Reading  
and Sources**Test Your Knowledge**

# / Test Your Knowledge

&lt;?&gt; ANSWER

5 Lipohaemarthrosis on a horizontal X-ray beam radiograph denotes that a fracture is:

- ☐ Comminuted
- ☐ Open
- ☒ Intra-articular
- ☐ Displaced

**CHAPTER OUTLINE:**

Imaging Anatomy

Strengths, Weaknesses  
and Roles of Imaging  
Modalities

Arthropathies

Fractures and  
Dislocations

Infection

Tumours and Tumour-  
like Conditions

Metabolic Diseases

Developmental  
Abnormalities

Take-Home Messages

Suggested Reading  
and Sources**Test Your Knowledge**

# / Test Your Knowledge

**<?> QUESTION**

# 6

An otherwise healthy 20-year-old male presents with knee pain following trauma during a football game. Radiographs reveal soft tissue swelling about the knee and a well-defined 4-cm lytic cortical-subcortical lesion at the lateral aspect of the distal femur with a thin sclerotic rim and mildly lobulated outline. Later, MRI reveals an anterior cruciate ligament tear and no fluid-fluid levels within the described femur lesion. The previously asymptomatic distal femur lesion is most likely:

- ☐ an osteosarcoma
- ☐ an osteoid osteoma
- ☐ a non-ossifying fibroma
- ☐ an aneurysmal bone cyst

## / Musculo-skeletal Imaging

**CHAPTER OUTLINE:**

Imaging Anatomy

Strengths, Weaknesses  
and Roles of Imaging  
Modalities

Arthropathies

Fractures and  
Dislocations

Infection

Tumours and Tumour-  
like Conditions

Metabolic Diseases

Developmental  
Abnormalities

Take-Home Messages

Suggested Reading  
and Sources**Test Your Knowledge**



# / Test Your Knowledge

**CHAPTER OUTLINE:**

Imaging Anatomy

Strengths, Weaknesses  
and Roles of Imaging  
Modalities

Arthropathies

Fractures and  
Dislocations

Infection

Tumours and Tumour-  
like Conditions

Metabolic Diseases

Developmental  
Abnormalities

Take-Home Messages

Suggested Reading  
and Sources**Test Your Knowledge****<?> ANSWER****6**

An otherwise healthy 20-year-old male presents with knee pain following trauma during a football game. Radiographs reveal soft tissue swelling about the knee and a well-defined 4-cm lytic cortical-subcortical lesion at the lateral aspect of the distal femur with a thin sclerotic rim and mildly lobulated outline. Later, MRI reveals an anterior cruciate ligament tear and no fluid-fluid levels within the described femur lesion. The previously asymptomatic distal femur lesion is most likely:

- ☐ an osteosarcoma
- ☐ an osteoid osteoma
- ☒ a non-ossifying fibroma
- ☐ an aneurysmal bone cyst

## / Test Your Knowledge

<?> QUESTION

7 What would be your recommendation for the bone lesion in the previous question?

- ☐ Leave it alone
- ☐ Close follow-up with MRI every 3 months for a year
- ☐ Surgical resection
- ☐ Make a biopsy according to compartmental anatomy considerations

**Musculo-  
skeletal  
Imaging**

**CHAPTER OUTLINE:**

Imaging Anatomy

Strengths, Weaknesses  
and Roles of Imaging  
Modalities

Arthropathies

Fractures and  
Dislocations

Infection

Tumours and Tumour-  
like Conditions

Metabolic Diseases

Developmental  
Abnormalities

Take-Home Messages

Suggested Reading  
and Sources

**Test Your Knowledge**

## / Test Your Knowledge

**CHAPTER OUTLINE:**

Imaging Anatomy

Strengths, Weaknesses  
and Roles of Imaging  
Modalities

Arthropathies

Fractures and  
Dislocations

Infection

Tumours and Tumour-  
like Conditions

Metabolic Diseases

Developmental  
Abnormalities

Take-Home Messages

Suggested Reading  
and Sources

**Test Your Knowledge**

<?> ANSWER

7 What would be your recommendation for the bone lesion in the previous question?

- ☒ Leave it alone
- ☐ Close follow-up with MRI every 3 months for a year
- ☐ Surgical resection
- ☐ Make a biopsy according to compartmental anatomy considerations

# / Test Your Knowledge

**<?> QUESTION**

8

Which of the following suggests more aggressiveness for bone lesions on radiographs?

- ☐ Solid type periosteal reaction
- ☐ Metaphyseal location
- ☐ Involvement of a long bone
- ☐ Permeative pattern
- ☐ Narrow zone of transition

**CHAPTER OUTLINE:**

Imaging Anatomy

Strengths, Weaknesses  
and Roles of Imaging  
Modalities

Arthropathies

Fractures and  
Dislocations

Infection

Tumours and Tumour-  
like Conditions

Metabolic Diseases

Developmental  
Abnormalities

Take-Home Messages

Suggested Reading  
and Sources**Test Your Knowledge**

# / Test Your Knowledge

&lt;?&gt; ANSWER

8

Which of the following suggests more aggressiveness for bone lesions on radiographs?

- ☐ Solid type periosteal reaction
- ☐ Metaphyseal location
- ☐ Involvement of a long bone
- ☒ Permeative pattern
- ☐ Narrow zone of transition

**CHAPTER OUTLINE:**

Imaging Anatomy

Strengths, Weaknesses  
and Roles of Imaging  
Modalities

Arthropathies

Fractures and  
Dislocations

Infection

Tumours and Tumour-  
like Conditions

Metabolic Diseases

Developmental  
Abnormalities

Take-Home Messages

Suggested Reading  
and Sources**Test Your Knowledge**

## / Test Your Knowledge

### / Musculo- skeletal Imaging

<?> QUESTION

9 A soft tissue mass with well-defined (distinct) margins on imaging is benign.

- ☐ True
- ☐ False

**CHAPTER OUTLINE:**

Imaging Anatomy

Strengths, Weaknesses  
and Roles of Imaging  
Modalities

Arthropathies

Fractures and  
Dislocations

Infection

Tumours and Tumour-  
like Conditions

Metabolic Diseases

Developmental  
Abnormalities

Take-Home Messages

Suggested Reading  
and Sources

**Test Your Knowledge**

## / Test Your Knowledge

**CHAPTER OUTLINE:**

Imaging Anatomy

Strengths, Weaknesses  
and Roles of Imaging  
Modalities

Arthropathies

Fractures and  
Dislocations

Infection

Tumours and Tumour-  
like Conditions

Metabolic Diseases

Developmental  
Abnormalities

Take-Home Messages

Suggested Reading  
and Sources

**Test Your Knowledge**

<?> ANSWER

9 A soft tissue mass with well-defined (distinct) margins on imaging is benign.

☐ True

☒ False



## / Test Your Knowledge

<?> QUESTION

### 10 Osteoporosis is best assessed with:

- ☐ Radiographs
- ☐ Ultrasonography
- ☐ Magnetic resonance imaging
- ☐ Dual-energy X-ray absorptiometry

**CHAPTER OUTLINE:**

Imaging Anatomy

Strengths, Weaknesses  
and Roles of Imaging  
Modalities

Arthropathies

Fractures and  
Dislocations

Infection

Tumours and Tumour-  
like Conditions

Metabolic Diseases

Developmental  
Abnormalities

Take-Home Messages

Suggested Reading  
and Sources

**Test Your Knowledge**

## / Test Your Knowledge

**CHAPTER OUTLINE:**

Imaging Anatomy

Strengths, Weaknesses  
and Roles of Imaging  
Modalities

Arthropathies

Fractures and  
Dislocations

Infection

Tumours and Tumour-  
like Conditions

Metabolic Diseases

Developmental  
Abnormalities

Take-Home Messages

Suggested Reading  
and Sources

**Test Your Knowledge**

**<?> ANSWER**

10 Osteoporosis is  
best assessed with:

- ☐ Radiographs
- ☐ Ultrasonography
- ☐ Magnetic resonance imaging
- ☒ Dual-energy X-ray absorptiometry

