

Case-Based Diagnosis Training

Patient:

Gender: *Female*

Age: *59 years*

Clinical History:

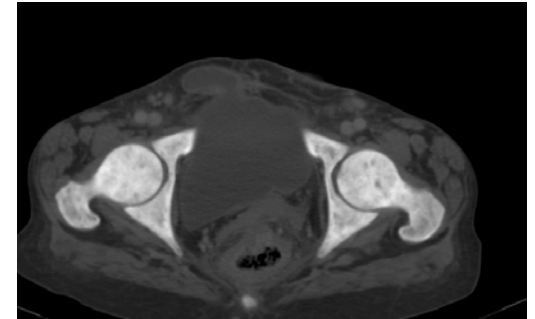
Patient presenting with chronic (1-year) abdominal pain, nausea, vomiting, diarrhoea and diffuse bone pain.

Final Diagnosis:

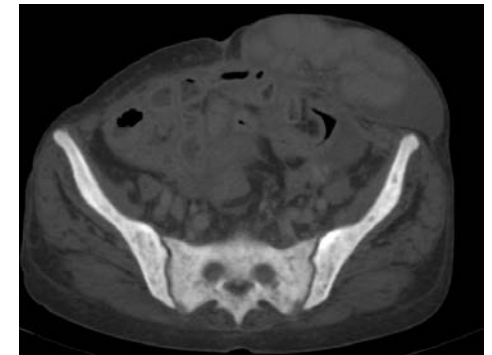
Systemic mastocytosis

Submitter: Julio Brandao Guimaraes; Sao Paulo/BR

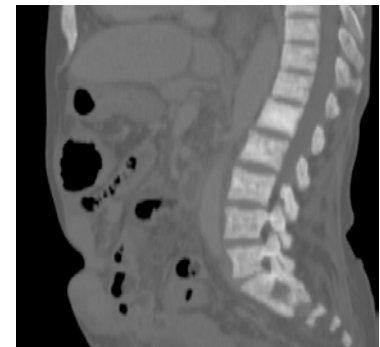
Please add pictures
(radiograph, ultrasound, CT or MR images)
by clicking on the symbols within the boxes below:



Picture 1: *Diffuse esclerotic pelvic bone lesions*



Picture 2: *Diffuse esclerotic pelvic bone lesions*

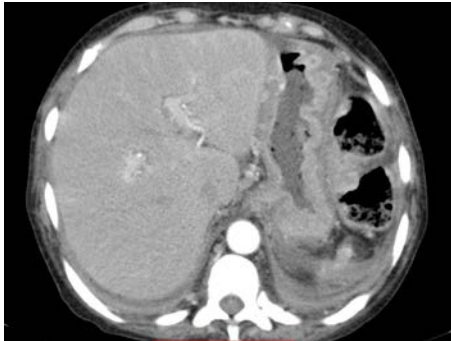


Picture 3: *Sclerotic lesions diffusely distributed in the spinal column*

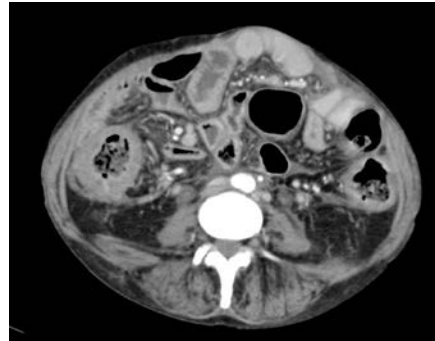
Case-Based Diagnosis Training

Additional Pictures:

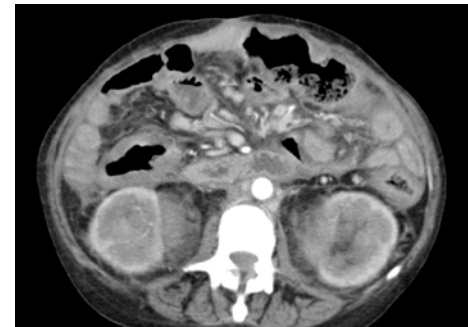In case you want to submit further pictures please add these (radiograph, ultrasound, CT or MR images) by clicking on the symbols within the boxes below:



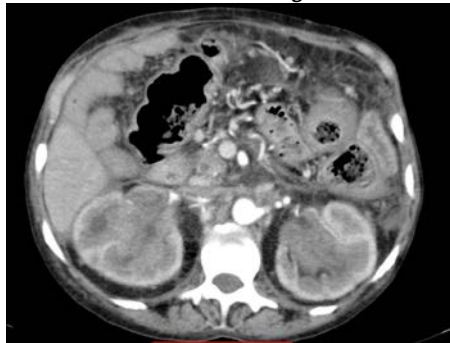
Picture 4: *Hepatomegaly, mural stomach thickening*



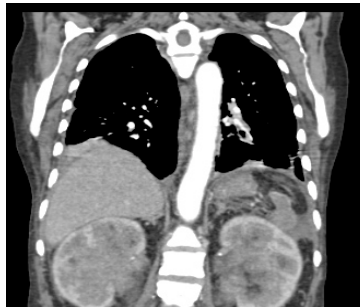
Picture 5: *Diffuse small bowel thickening*



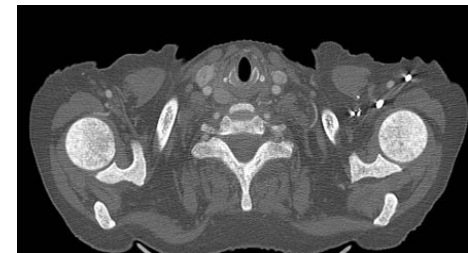
Picture 6: *Bilateral renal infiltrations*



Picture 7: *Bilateral renal infiltrations*



Picture 8: *Bilateral renal infiltrations and sclerotic lesions diffusely distributed in the spinal column*



Picture 9: *Diffuse sclerotic bone lesions in the shoulder girdle.*