

Case-Based Diagnosis Training

Patient:

Gender: *female*

Age: *34 years*

Clinical History:

Patient with throat pain and minimally productive cough. No fever.

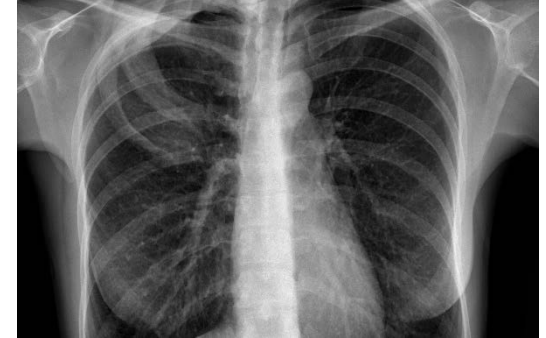
Lung auscultation was normal.

Final Diagnosis:

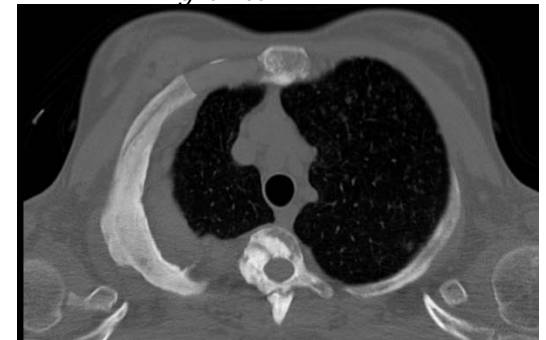*Tuberous sclerosis (Bourneville-Pringle disease).
Incidental findings in patient with an upper
respiratory tract infection.*

**Submitter: Facundo Nahuel Diaz, Mauricio Omar Marquesini Lopez;
Buenos Aires/AR**

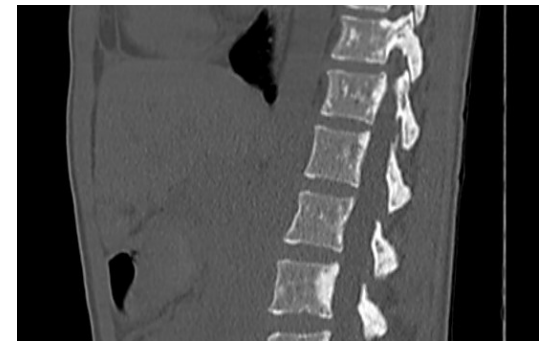
Please add pictures
(radiograph, ultrasound, CT or MR images)
by clicking on the symbols within the boxes below:



Picture 1: *Hyperostosis of 2nd and 3rd right ribs*



Picture 2: *Hyperostosis of 3rd rib (MIP)*

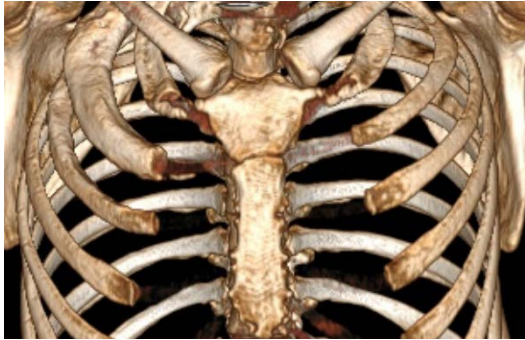

Picture 3: *Focal sclerotic lesions*

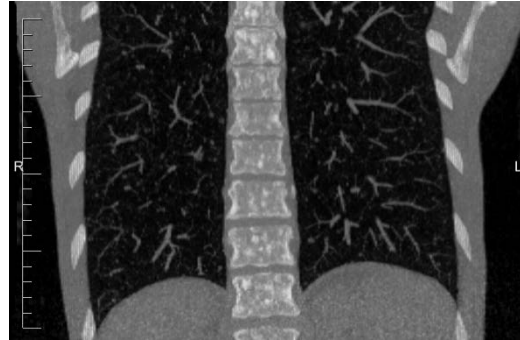
Case-Based Diagnosis Training

Additional Pictures:

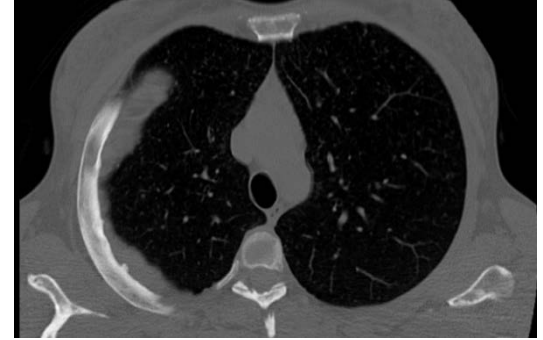In case you want to submit further pictures please add these (radiograph, ultrasound, CT or MR images) by clicking on the symbols within the boxes below:



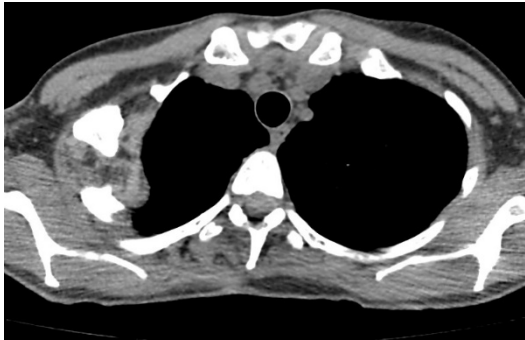
Picture 4:



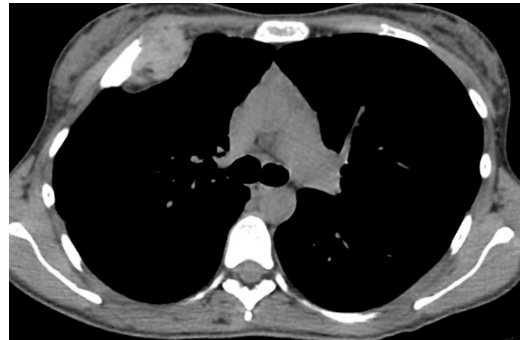Picture 5:



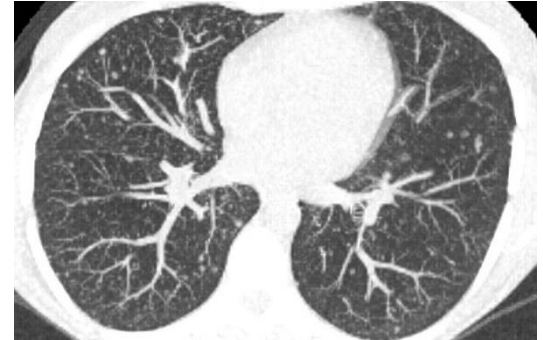
Picture 6:



Picture 7:



Picture 8:



Picture 9: